



International Journal of Homoeopathic Sciences

E-ISSN: 2616-4493

P-ISSN: 2616-4485

www.homoeopathicjournal.com

IJHS 2023; 7(4): 410-413

Received: 23-10-2023

Accepted: 26-11-2023

Dr. Ranjana Pavan Terdal
BHMS, MD Homoeopathy in
Materia Medica MUHS,
Nashik, Maharashtra, India

A curious case report of left foot eczema: Through homoeopathic lens

Dr. Ranjana Pavan Terdal

DOI: <https://doi.org/10.33545/26164485.2023.v7.i4f.1006>

Abstract

There are many skin diseases today, including Eczema. The Medical Definition of Eczema [EK-zeh-muh] is "A group of conditions in which the skin becomes inflamed, forms blisters, and becomes crusty, thick and scaly". It causes burning and itching and may occur over a long period [1]. Approximately 75% of the patients experience remission before adolescence, and the remaining 25% develop atopic dermatitis into adulthood or experience a relapse after several years [2]. In Conventional medicine, it is treated with emollients and topical steroids. However, by using homoeopathic treatment, one can cure the disease as well as prevent its return. Homoeopathy provides a better response in such conditions; one such case report is presented below. A 71 years old, male patient attended OPD for complaints of severe itching, swelling and hyperpigmentation of the left foot. He has suffered from this condition since 1994, after unsatisfactory outcomes from modern medicine and ayurvedic treatment, the patient turned to homoeopathic treatment, after case taking, Homoeopathy medicine is prescribed and doses and medicine are given according to the relationship of medicine, as per the response of medicine on the patient. Within 11 months of homoeopathic treatment, the patient started improving and continued to be free from his complaint at the time of his last follow-up visit to OPD.

Keywords: Eczema, blisters, scaly, adolescence, emollients, homoeopathy treatment

Introduction

Although uncommon, eczema is a common, long-lasting, noninfectious condition. The most prominent sign of eczema is an itchy rash. If the rash does not go away during childhood, it often gets better with time. Severe bouts of eczema can significantly impair a person's quality of life. However, you do not have to hide your eczema as you get older. You can control your symptoms by treating eczema diligently and avoiding factors that can cause flare-ups.

Symptoms: Acute eczema includes red and itchy skin, sometimes with blisters that easily break and then weep [leak liquid]. Over time the skin may become dry and cracked and also thicken. The structure may also change, making it rougher. The main symptom is itching, which can often become unbearable. At times it will get worse [flare up]. At other times it will get better [rise and fall]. Also clears up completely for a while. The inflammation is only rarely constant. Each person is different and the severity of symptoms varies depending on your age [4].

Causes of Eczema

The skin's defensive layer, the cornea, is damaged by the inflammatory response happening in the skin. Another possible cause is a mutated gene that affects the production of the protein filaggrin, which the body needs to make the skin changes, causing the skin to lose irritants and allergens. [substance that can trigger allergies]and germs that might cause infections. Some foods, especially those containing nuts, eggs and fish and pollens such as grass, can cause eczema. The skin may also be irritated by environmental factors or other substances that are not allergens. The skin can get uncomfortable when it comes into contact with rough materials such as rough wool, tobacco heat or cold.

Corresponding Author:
Dr. Ranjana Pavan Terdal
BHMS, MD Homoeopathy in
Materia Medica MUHS,
Nashik, Maharashtra, India

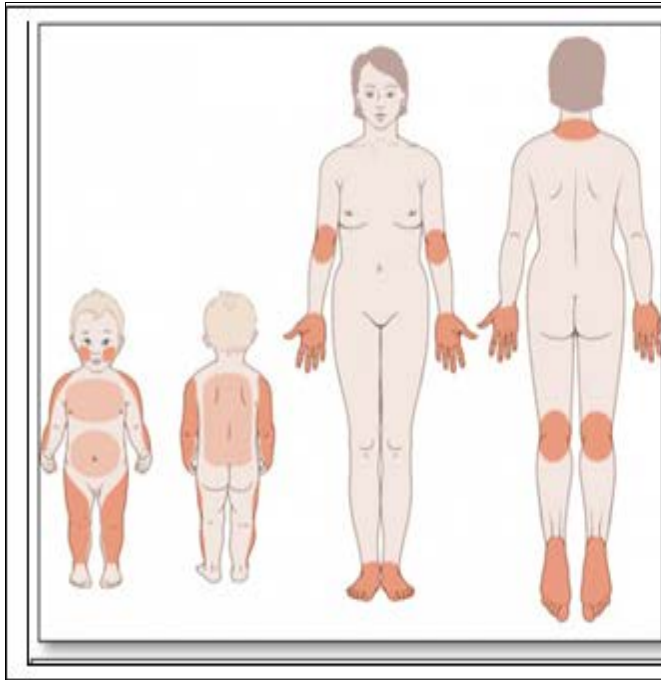


Fig 1: Eczema in Children and Adults: Skin areas typically affected

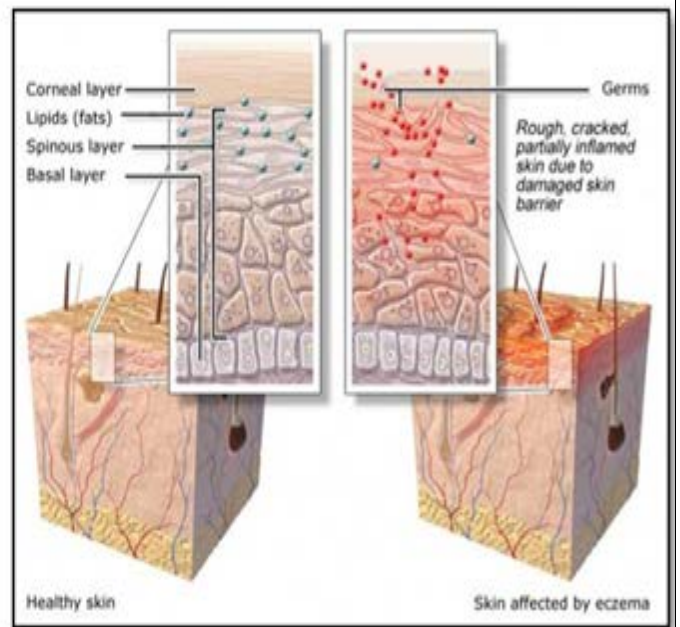


Fig 2: Healthy Skin and Skin affected by Eczema

Types of eczema: Besides atopic dermatitis other types include

1. **Allergic contact dermatitis:** Which occurs with a substance or allergen that the immune system recognizes as foreign.
2. **Dyshidrotic eczema:** Refers to irritation of skin on the palms of the hands and soles of the feet. Characterized by blisters.
3. **Neurodermatitis:** leads to scaly patches of skin on the head, forearms, wrists and lower legs. It occurs due to a localized itch such as from an insect bite.
4. **Discoid Eczema:** Also known as nummular

Case Report

Patient Information

A 71-year-old male patient reported to the OPD on 19

March 2022 with complaints of itching over the left foot, and skin becoming dry and cracked. Itching aggravates at night, amel by cold water application.

Medical History

Taken modern Medication for treatment, antibiotics, cream etc.

Recent diagnosis of Type 2 Diabetes Mellites taking homoeopathy treatment.

Past History: NO Any specific history of illness.

Family History

Mother: Was Healthy dying of a natural cause?

Father: Was healthy dying of natural cause.

Younger sister: Has type 2 DM at the age of 55.

Table 1: Physical generals

Appetite: Normal with proper timetable for meals, purely vegetarian	Thirst: Intake of 3 litres of normal water.
Desire: Sweets	Aversion: Not specific
Perspiration: Normal no bad smell or staining	Urine: Frequently at night, Incontinence of urine
Stool: Indigestion with sometimes hard stool	Sleep: Disturbed due to frequency of urination, and dreams. Sleep with a covering of the whole body, in the dark.
Dreams: Of His Son who died in a road accident 9 years back	Thermal State: Chilly Patient

Table 2: Physical Examination

Appearance: Average	Hair Type and Colour: Black
Eyes: Normal and No spectacles	Ear: Normal No tinnitus
Tongue: Normal	Teeth: Normal No carries
Fingers: Normal	Nails: Normal
Skin type and colour: Dry skin and dark	Pallor: Absent
Temperature: Normal	

Mind

Wants company, always ready to help needy and poor people Emotional Cry in alone, Angary when contradiction, Consolation amel symptoms; Fastidious, want everything clean neat, and tidy, Emotion suppress Systemic examination: all systematic examination is normal.

Table 3: Reperforation

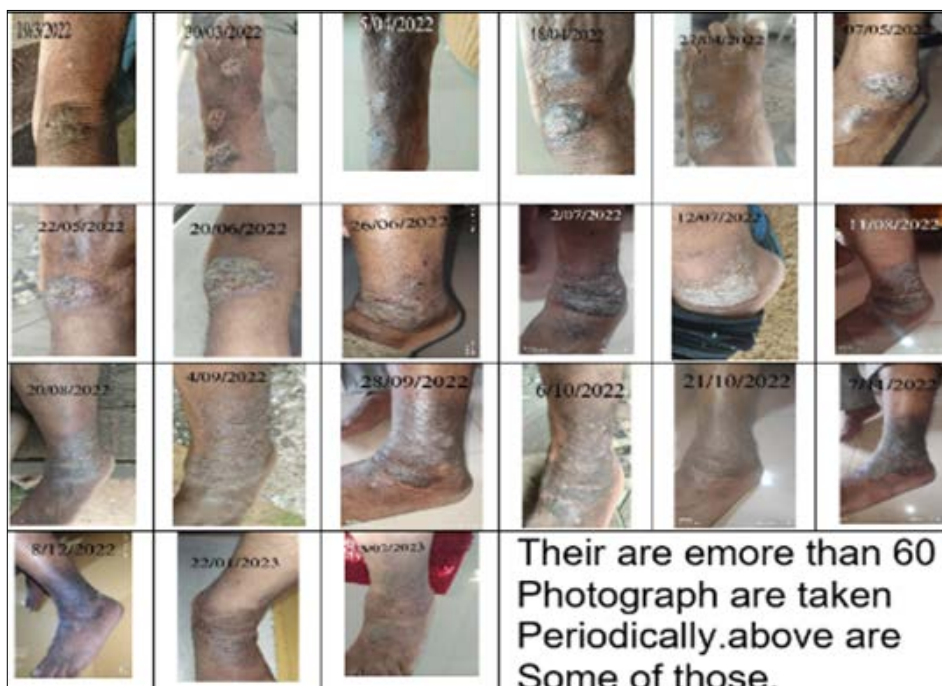Remedy	Sulph	Ars	Rhus-t	Graph	Mez	Alum	Merc	Phos	Lyc	Psor	Petr	Sep	Led	Dulc	Calc
Totally	34	33	31	30	29	28	28	28	27	27	27	26	25	25	25
Symptoms Covered	10	10	9	10	9	9	9	8	8	8	7	8	10	9	7
[Complete] [Skin]Eruptions: Eczema:	4	4	4	4	4	4	4	4	4	4	4	4	4	4	4
[Complete] [Extremities]Eruptions: Eczema: Lower limbs:	4	4	3	4	0	0	3	0	3	3	4	0	1	0	0
[Complete] [Extremities]Eruptions: Eczema: Lower limbs: Left:	0	0	0	0	0	0	0	0	0	0	0	0	0	0	0
[Complete] [Skin]Eruptions: Eczema: Itching:	0	0	4	1	3	3	0	0	0	3	0	3	1	0	0
[Complete] [Skin]Swelling: Inflamed: Eczema:	0	0	0	1	0	0	0	0	0	0	0	0	0	0	0
[Complete] [Skin]Eruptions: Discharging, moist:	4	4	4	4	4	3	4	4	4	4	4	4	1	4	4
[Complete] [Skin]Eruptions: Itching:	4	4	4	4	4	3	4	3	3	4	4	4	4	3	4
[Complete] [Skin]Itching: Scratching: amel.:	3	1	2	1	2	2	2	4	0	0	0	3	1	2	4
[Complete] [Skin]Eruptions: itching: bathing, washing: cold, amel.:	0	0	0	0	0	0	0	0	0	0	0	0	0	0	0
[Complete] [Skin]Itching: Old people:	3	4	0	0	3	3	1	0	0	0	0	0	0	3	0
[Complete] [Skin]Itching: Scratch, must:	3	3	3	4	3	3	3	2	3	3	4	3	3	2	3
[Complete] [Skin]Itching: Scratching: Agg.:	4	4	4	3	3	3	3	4	3	3	3	1	3	3	3
[Complete] [Skin]Itching: Sleep: During:	1	1	0	0	0	0	0	3	3	0	0	0	0	1	0
[Complete] [Skin]Spots:	4	4	3	4	3	4	4	4	4	3	4	4	4	3	3
[Complete] [Skin]Eruptions: Eczema: Cold amel.:	0	0	0	0	0	0	0	0	0	0	0	0	3	0	0

According to the analysis of symptoms, repertorisation is done by the Zomoeo pro app, Repertorisation chart is given. Graphites 30 OD for 3 days dose is given alone with placebo on the first visit on 19 March 2022 considering the reportorial totality and causation in the path of improving medicine is change according to remedy relationship. The patient was improved symptomatically as compared to before on 28 February 2023.

Discussion

After Repertorisation many medicines namely Sulphur, Arsenic album, Rhus. Tox, Graph, Mez, Alum, Merc, Phos, Lyc, Psor, Petr, Sep, Led, Dulc, Calc etc. came but after taking details through Materia Medica^[3]. In this case, after thorough case-taking and analysis, we selected Graphites 30 as the most appropriate medicine for the patient's left foot Eczema. Graphites is a mineral-based medicine derived from black lead and is known for its effectiveness in treating skin conditions like eczema. Graphitis have several Keynotes that match the patient's symptoms. One of the most relevant keynotes, in this case,

is “Left-sided complaints.” as the patient eczema was primarily left side Another important keynote of Graphities is “Ailments from suppressed eruptions”, and this is a common cause of eczema, Another significant Keynote of Graphities is “discharge are thick, sticky, offensive, foul, scanty and acrid”, This Keynote further confirms the selection of Graphities as its totality of symptoms was right. In this case, the patient showed significant improvement with Graphities 30. Homoeopathy also takes into account the mental and emotional aspects of a person while choosing a remedy. In this case after analyzing the patient's mental and emotional state, it was found that he was a reserved and introverted person who had difficulty expressing his emotions. This personality trait is also in line with Graphite Indication as it is known for its usefulness in treating emotional suppression and introverted personalities. Homoeopathy treated patients with individualized medicine and doses, depending on their unique symptoms and response to the remedy. In this case, Graphitis 30 is Medicine given in stages, and it shows signs of improving Eczema.



These are few photographs taken during follow up, more than 60 photographs we have in this case.

Fig 3: Photographs taken during follow up

Follow up on the case

Photograph of the patient's eczema is collected periodically after consuming the prescribed medicine. More than 60

photographs were collected during the process of treatment. Some photographs are here to be given as a month.

Table 4: Follow-up Sheet

Sl. No	Date	Symptoms	Remedy with dose
1.	19/3/2022	Dryness of skin, cracks, hard, Sticky discharge from eczema. Burning after scratching. itching agg night, warm amel cold, scratching mild sticky discharge	1] Graph 30 x OD x 3days 2] Placebo x BD X 8 days
2.	28/3/2022	Dryness of the skin decreased by 15 % cracks and hardness of the skin better by 5 % Burning after scratching persistently Sticky discharge increased	1] Placebo x BD x1 month
3.	2/04/2022	Dryness of skin better by 20 % Scaling of skin Hardness improved by 15% Burning pain better by 10 % The sticky discharge is stopped now.	1]Graph 30 x OD x3days 2] Placebo x BD x 1 month
4.	7/05/2022	The patient feels better in the last 30 days. Discharge has increased again since the last 2 days with redness of the skin, pain, and distress. Itching increases.	1] Graph 30 x OD x3days 2]Placebo X BD x 30 days
5.	9/06/2022	All new and recent eruption are gone, old eruption on the ankle joint remains, with mild discharge. Yellow crust	1]Graph 30 x BD x3days 2]Placebo x BD x30Days
6.	2/07/2022	Swelling over the ankle joint. itching agg at night, discharge sticky. Painful, Crust following out.	1]Placebo X BD x 30 Days
7.	11/08/2022	Swelling, discharge and pain decreased. Hyperpigmentation on ankle no burning. Dryness of skin with scaly skin	1]Graph 30x OD x3days 2]Placebo x BD x 30 days
8.	15/09/2022	Mild swelling and discharge remain. With hyperpigmentation of the ankle.	1]Placebo x BD x30 days
9.	6/10/2022	Discharge, swelling stops. Dryness and hyperpigmentation of skin better	1]Placebo x BD x30 days
10.	7/11/2022	Mild swelling, agg working in water. Patient feels better	1]Placebo x 30 x days.
11.	8/12/2022	Mild hyperpigmentation, mild swelling, and mild discharge remain.	1]Graph 30 single dose 2]Placebo x BD x 2 month
12.	22/01/2023	Hyperpigmentation of skin decreased. mild eruption remaining. Mild itching.	1]Placebo X BD x15 days
13.	3/02/2023	The patient is improving. Mild hyperpigmentation remains.	Placebo x BD x2 month

Conclusion

Homoeopathy is a holistic system of medicine that aims to treat the person as a whole rather than just their symptoms. It based on the principle of "like cures like", which means that a substance that can cause symptoms in a healthy person can cure similar symptoms in a sick person. This is known as the law of similars and is the foundation of Homoeopathy. In Conclusion, this curious case report of left foot eczema through a Homoeopathic lens highlights the importance of individualized treatment and understanding the patient as a whole in homoeopathy. The selection of Graphites, based on the patient's symptoms, keynotes, and response to the medicine resulted in significant improvement in his condition within just 11months. This case serves as a reminder that homoeopathy can provide relief to the patients who have not seen success with conventional treatments and is a reliable option for chronic skin conditions likes Eczema.

Conflict of Interest

Not available

Financial Support

Not available

References

- <https://www.cancer.gov/publications/dictionaries/cancer-terms/def/eczema>
- <https://www.ncbi.nlm.nih.gov/pmc/articles/PMC8463816/#:~:text=Approximately%2075%25%20of%20patients%20experience,symptom%2Dfree%20%5B4%5D>
- Homoeopathic Materia Medica by William Boericke.
- <https://www.ncbi.nlm.nih.gov/books/NBK279399/#:~:t>

ext=Eczema%20is%20a%20common%2C%20chronic,
a%20while%20or%20disappear%20altogether.

How to Cite This Article

Terdal RP. A Curious Case Report of Left Foot Eczema: Through Homoeopathic Lens. International Journal of Homoeopathic Sciences. 2023;7(4):410-413.

Creative Commons (CC) License

This is an open access journal, and articles are distributed under the terms of the Creative Commons Attribution-Non Commercial-Share Alike 4.0 International (CC BY-NC-SA 4.0) License, which allows others to remix, tweak, and build upon the work non-commercially, as long as appropriate credit is given and the new creations are licensed under the identical terms.