



International Journal of Homoeopathic Sciences

E-ISSN: 2616-4493

P-ISSN: 2616-4485

IJHS 2019; 3(4): 16-19

Received: 10-08-2019

Accepted: 12-09-2019

Dr. S Bidwalkar

Professor & Head of The
Department of Repertory
Dr. M.P.K. Homoeopathic
Medical College, Hospital &
Research Centre Homoeopathy
University, Jaipur, Rajasthan,
India

Dr. Yashasvi Shakdviya

Asst. Prof, Department of
Repertory Dr M.P.K.
Homoeopathic Medical
College, Hospital & Research
Centre Homoeopathy
University, Jaipur, Rajasthan,
India

Dr. Noopur Kumari

MD (Hom.) (PGR)
Department of Repertory
Dr. M.P.K. Homoeopathic
Medical College, Hospital &
Research Centre Homoeopathy
University, Jaipur, Rajasthan,
India

Corresponding Author:

Dr. Noopur Kumari

MD (Hom.) (PGR)
Department of Repertory
Dr. M.P.K. Homoeopathic
Medical College, Hospital &
Research Centre Homoeopathy
University, Jaipur, Rajasthan,
India

Homoeopathic treatment of Vitiligo: A case report

Dr. S Bidwalkar, Dr. Yashasvi Shakdviya and Dr. Noopur Kumari

Abstract

Vitiligo is a common chronic skin depigmentation disorder. It is an autoimmune skin condition that results in the loss of the melanin pigment. A case report of a 8 year male child is presented here which was treated with individualized homoeopathic medicine after proper case taking and repertorization.

Keywords: Autoimmune disease, Vitiligo, depigmented, patches, reportorial totality, constitutional medicine, individualized, homoeopathy

Introduction

Vitiligo results due to stoppage of melanin formation by the melanocytes and presents as asymptomatic depigmented macules anywhere on the body including mucous membranes of lips and genitalia. There is a marked reduction or even absence of melanocytes and melanin in the epidermis [1, 2] Vitiligo is not a rare condition but is difficult to treat and is associated with psychological distress [3] The exact cause of the Vitiligo is not known and different patterns of vitiligo may have different pathogenesis [4, 5] Some studies suggested that Vitiligo is an autoimmune disease in which the body's immune system attacks its own healthy cells. It sometimes runs in family suggesting that genetics may play a role [5]. In some cases people with Vitiligo often report with some sort of triggering factors like injury, sunburn, illness, any emotional stress, pregnancy etc. [5, 6] Different patterns of vitiligo are:- (a) Vitiligo Vulgaris- it is the commonest type which usually occurs after second decade. (b) Segmental Vitiligo- restricted to one part of the body and usually occurs in younger individuals (c) Generalised Vitiligo- have extensive lesions. Depigmentation usually occurs before the age 20 [4]

Case report

A 8 year male child was reported at Sindhi camp campus OPD on 14/8/18 with a complaint of hypopigmented spot over chin, neck, nape of neck, both ears, scalp since 8 to 9 months

History of Presenting Complaints

Patient was apparently well 9 months back when he gradually started complaining of hypopigmented spots first seen over his chin, the descending below towards the neck, then to both ears and lastly over nape of neck and scalp. The spots were earlier smaller which gradually started increasing in size.

Past Medical History - nothing specific

Family History- nothing specific

Mental Generals

Ailments started after he got afraid of the fight between his family members +++

Doesn't wear dirty clothes+++

Weeps when alone ++

Desire for company +

Obstinate in nature +

Physical Generals

Appetite- 1 chapati/ meal, 3 meals / day, 3 cups of milk per day

Thirst- drinks 1 to 1-1/2 litres per day

Desire- salty+++ , sweets++, cold food and drinks++

Stool- hard stools ++, offensive +++ , black, constipated, passes once in 3 to 4 days

Thermal reaction- Hot

Sleep- sound, refreshing sleep, sleeps for 8-10 hours

Skin Examination

Margins of patch- defined
 Colour of patch- white
 No. of patches- multiple
 Hair in patches- white

General Examination

General built- lean and thin
 Pulse- 78bpm
 Respiratory rate- 16 breaths per minute

Analysis of Symptoms

Mentals

Ailments started after he got afraid of the fight between his family members
 Doesn't wear dirty clothes
 Weeps when alone
 Desire for company
 Obstinate in nature

Physical generals

Desire for salty food

Desire for sweets
 Desire for cold food and drinks
 Constipated, hard, black and offensive stools

Particulars

Hypopigmented spots over chin, neck, nape of neck, both ears and scalp

Evaluation of Symptoms

1. Ailments started after he got afraid of the fight between his family members
2. Doesn't wear dirty clothes
3. Desire for salty food
4. Offensive stools
5. Hypopigmented spots over chin, neck, nape of neck, both ears and scalp
6. Weeps when alone
7. Desire for sweets
8. Desire for cold food and drinks
9. Constipated hard, black and offensive stools
10. Desire for company
11. Obstinate in nature

Table 1: Repertorial Totality

Symptoms	Repertorial totality
Ailments started after he got afraid of the fight between his family members	Mind - Ailments From - fright
Doesn't wear dirty clothes	Mind - CLEANNESS - mania for
Weeps when alone	MIND - WEEPING - alone, when
Desire for salty food	GENERALS - FOOD and DRINKS - salt - desire
Desire for sweets	GENERALS - FOOD and DRINKS - sweets - desire
Desire for cold food and drinks	GENERALS - FOOD and DRINKS - cold drink, cold water - desire GENERALS - FOOD and DRINKS - cold food - desire
Constipated hard, black and offensive stools	STOOL - HARD - burnt, as if STOOL - ODOR - offensive
Hypopigmented spots over chin, neck, nape of neck, both ears and scalp	SKIN - DISCOLORATION - white - spots

Repertorial Sheet

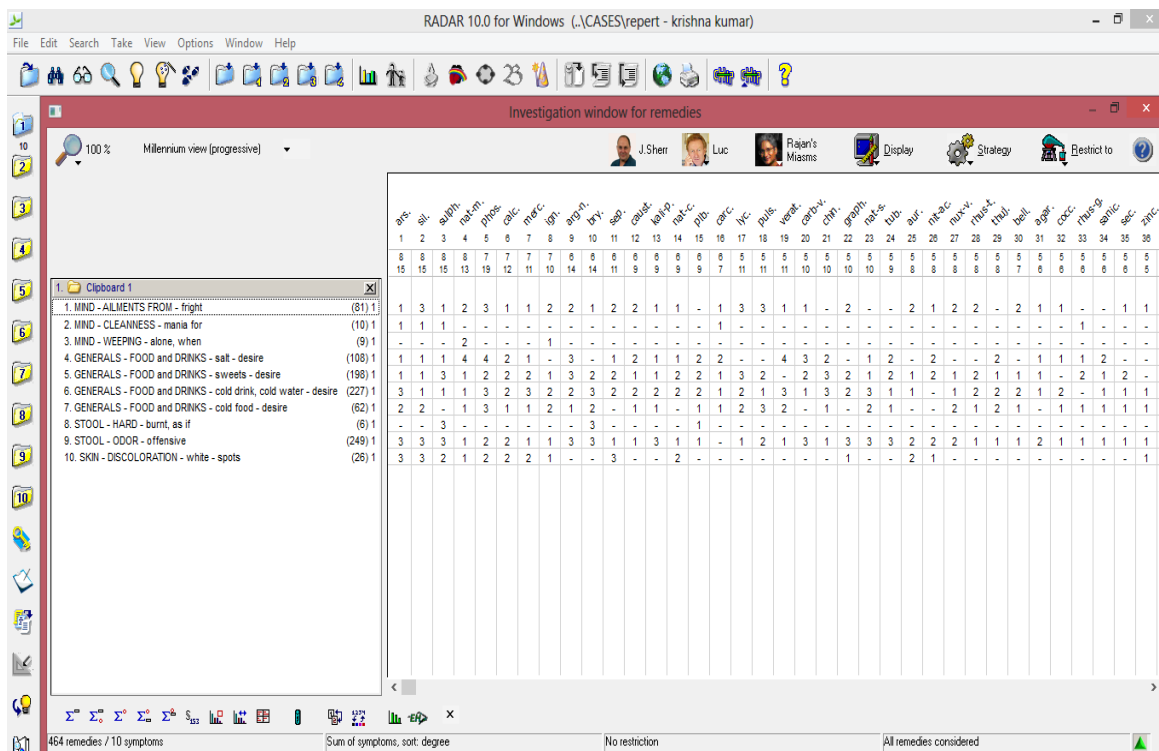


Fig 1: Showing repertorization of case from Synthesis Repertory 9.0 (English) using RADAR 10.0

Prescription

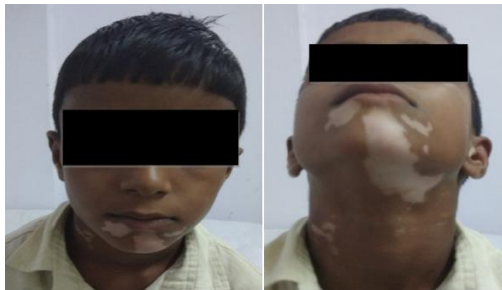Sulphur 30/ 1 Dose
 Rubrum 30/ TDS/ 14 days

repertorization and thermal reaction of the patient a single dose of Sulphur is prescribed in 30 potency as per the need of the case which is followed by Rubrum. The medicine was repeated wherever the improvement ceases [7]

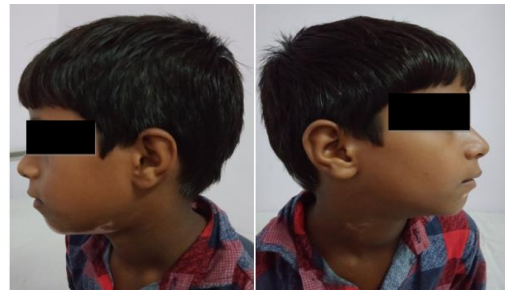Basis of Prescription: Considering the results of

Follow Up Sheet

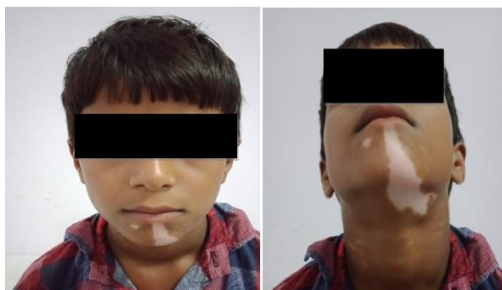Date	Symptoms	Prescription
14/8/18	On the basis of repertorization	Sulphur 30/1 dose Rubrum 30/ BD/ 14 days
28/8/18	Same as before	Rubrum 30/ BD/14 days
11/9/18	The spots over B/L ears are getting darker	Rubrum 30/ BD/14 days
25/9/18	The spots over chin are getting pigmented and the margins are getting closer	Rubrum 30/ BD/14days
9/10/18	The spots all over affected areas are getting pigmented	Rubrum 30/ BD/21days
30/10/18	No further improvement is seen	Sulphur 30/1 dose Rubrum 30/ BD/ 14 days
13/11/18	The spots over nape of neck is getting pigmented	Rubrum 30/ BD/30 days
18/12/18	The spots are getting pigmented	Rubrum 30/ BD/30 days
15/1/19	No further improvement is seen	Sulphur 30/1 dose Rubrum 30/ BD/30 days
12/2/19	The spots are same	Sulphur 200/1 dose Rubrum 30/ BD/30 days
12/3/19	The spots over chin are getting pigmented and smaller in size	Rubrum 30/ BD/30 days
16/4/19	The spots over chin, nape of neck and both the ears are getting smaller in size	Rubrum 30/ BD/30 days
14/5/19	The spots are getting pigmented	Rubrum 30/ BD/30 days
11/6/19	The spots over neck are getting smaller and pigmented	Rubrum 30/ BD/30 days
16/7/19	No further improvement is seen	Sulphur 200/1 dose Rubrum 30/ BD/30 days
13/8/19	The spots all over the affected areas are getting darker and smaller in size	Rubrum 30/ BD/30 days
10/9/19	The spots all over the affected areas are getting darker and smaller in size	Rubrum 30/ BD/30 days



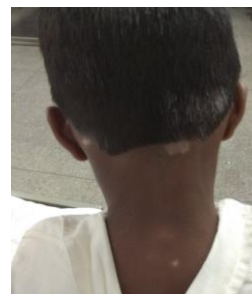Before treatment (14/8/18)



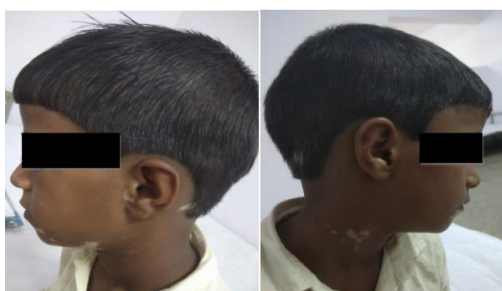After treatment (10.9.19)



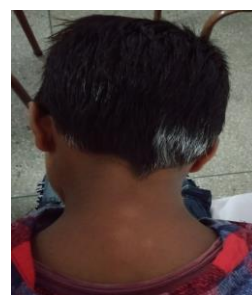After treatment (10.9.19)



Before treatment (14/8/18)



Before treatment (14/8/18)



After treatment (10.9.19)

Discussion and conclusion

Vitiligo is one of the most common cosmetic problem nowadays. It leaves a long lasting impression on the psychological development of the patient. Homoeopathy helps in reducing this stress by treating the patient on the psychological as well on the physical aspect. Homoeopathy treats the patient as a whole not just its end products of disease. Homoeopathic medicines are prescribed after getting the totality of the symptoms of the patient. In the above mentioned case medicine was prescribed after proper case taking and repertorization which not only improved the depigmented spots but also improved the general health of the patient as reported by him in his follow ups.

References

1. Gupta R, Manchanda RK. Textbook of dermatology for homeopaths. 4th edition. New Delhi: B. Jain Pub.; 2011, 140.
2. Dewan D, Taneja D, Singh U, Mittal R, Khurana A. Homoeopathic research in vitiligo: Current scenario. Indian Journal of Research in Homoeopathy. 2017; 11(4):226.
3. Mahesh S, Mallappa M, Tsintzas D, Vithoulkas G. Homeopathic Treatment of Vitiligo: A Report of Fourteen Cases. American Journal of Case Reports. 2017; 18:1276-83.
4. Khanna N. Illustrated synopsis of dermatology & sexually transmitted diseases. 3rd edition. New Delhi: Elsevier India, 2019; 131-32
5. Vitiligo [Internet]. Genetic and Rare Diseases Information Center. U.S. Department of Health and Human Services; [cited 2019Aug18]. Available from: <https://rarediseases.info.nih.gov/diseases/10751/vitiligo>
6. Colledge NR, Walker BR, Ralston SH, editors. Davidson's Principles & Practice of Medicine. 21st edition. Elsevier Limited, 2010, 1253-54.
7. Hahnemann S, Boericke W. Organon of medicine. 5th edition. New Delhi: B. Jain; Aphorism 2009; 245-48:122-27