



# International Journal of Homoeopathic Sciences

E-ISSN: 2616-4493

P-ISSN: 2616-4485

[www.homoeopathicjournal.com](http://www.homoeopathicjournal.com)

IJHS 2023; 7(4): 454-456

Received: 02-08-2023

Accepted: 13-09-2023

**Dr. Pankaj Sharma**

Professor Dean-Rajasthan  
Ayurveda University, Jodhpur  
& HOD of Department of  
Organon of Medicine-Swasthya  
Kalyan Homoeopathic Medical  
College & Research Centre,  
Sitapura, Jaipur, Rajasthan,  
India

**Dr. Harish Jabdolia**

Assistant Professor,  
Department of Organon of  
Medicine, Swasthya Kalyan  
Homoeopathic Medical College  
& Research Centre, Sitapura,  
Jaipur, Rajasthan, India

**Dr. Nimisha Pareek**

M.D. (PGR), Department of  
Organon of Medicine,  
Swasthya Kalyan  
Homoeopathic Medical College  
& Research Centre, Sitapura,  
Jaipur, Rajasthan, India

**Dr. Sushila Choudhary**

M.D. (PGR) Department of  
Organon of Medicine-Swasthya  
Kalyan Homoeopathic Medical  
College & Research Centre,  
Sitapura, Jaipur, Rajasthan,  
India

**Corresponding Author:**

**Dr. Pankaj Sharma**

Professor Dean-Rajasthan  
Ayurveda University, Jodhpur  
& HOD of Department of  
Organon of Medicine-Swasthya  
Kalyan Homoeopathic Medical  
College & Research Centre,  
Sitapura, Jaipur, Rajasthan,  
India

## Flat wart treated successfully by homoeopathy: A case report

**Dr. Pankaj Sharma, Dr. Harish Jabdolia, Dr. Nimisha Pareek and Dr. Sushila Choudhary**

DOI: <https://doi.org/10.33545/26164485.2023.v7.i4f.1010>

### Abstract

Warts are classified under one sided diseases as external local maladies. They often have individualistic and immunological basis as also familial tendencies. Warts are included under miasm sycosis. Although warts are local diseases, they are treated with internal remedy which is based on comprehensive understanding of the patient. This includes local symptoms, i.e. morphology and location of lesion, mental makeup of the person, and physical characteristics. This is what is called totality of symptoms. A constitutional remedy thus selected eradicates the complaint locally as well as internally, thereby providing long lasting relief from complaints. Common remedies include Calcarea carbonica, Causticum, Lachesis, Sulper, Thuja occidentalis, Sepia, Natrum Mur. Homeopathic concept and homeopathic treatment of warts has been described.

**Keywords:** Calcarea carbonica, flat wart, homeopathic

### Introduction

As we know, skin is the mirror of the soul! This understanding forms the basis of homeopathic management of skin disorders. In modern medicine, warts are understood to be caused by an infection with the human papillomavirus. Warts commonly appear on hands, feet, as well as on other areas of skin and mucous membranes <sup>[1]</sup>.

Warts are categorized on the basis of location, namely, common warts (around nails and fingers), foot warts, and genital warts. They are also understood on the basis of their morphology and texture, namely, soft, hard, flat, smooth, rough, scaly, etc. These are contagious and can spread from direct skin contact.

Warts are of diagnostic value to us in distinguishing between different stages of disease. The verruca vulgaris is found in children who are suffering with hereditary sycosis; they appear at or about the second dentition. The verruca filiformis comes as a tertiary lesion in an acquired form of sycosis. The verruca plana juvenilis is another hereditary form found more or less upon the back of hands and faces of children and young people. They are usually pigmented, disseminated, and in irregular unilateral groups <sup>[2]</sup>.

Some people are just more likely to contract warts than others, just like some people catch colds more easily than others do. Weakened immune systems, lack of adequate rest, poor nutrition, increased stress, and close living quarters can also contribute to catching the wart virus <sup>[3]</sup>.

This means that warts too have an individualistic and immunological basis.

### Case

**Background:** The reported case is 25 yrs old vegetarian male Student by Profession, belonging to a middle socio-economic family, residing in rural area who came to our OPD of Swasthya Kalyan Homoeopathic Medical College & Research Centre, Sitapura, Jaipur. Rajasthan (India) on 07-04-2022 with the following Complaints of Multiple flat warts on right forearm since 3 years with slight itching when exposed to dust and sun light. Largest wart up to 0.6 cm, rest are small Spreading continuously new wart every next week.

- Complaint of Warts is from almost 3 years.
- There were only 4 warts in the starting, for 7-8 months, and were soft. Slight itching was present.
- Have taken allopathic treatment 2 yrs. back. Warts were improved for few months and

- Then again reappeared.
- Now spreading continuously. New eruption every next week.

**Past history:** N/A

**Mental generals**

**Childhood:** Flabby child. Delayed dentition, slow. Ate soil and chalk a lot.

- Introvert and diligent.
- Fear of darkness.
- Confused.
- Desire-company

Avoid changes. Likes to be with family, have refused to go out for studies and job.

Ailments from Death of loved one. Absent minded. Anxiety fear with.

**Family history**

55 year old Mother having lipoma on thighs since long and is on allopathic treatment.

Younger Brother died 4 year ago

**Physical generals**

His appetite was good. However thirst was decreased. He only drank 1-1.5 litres water in a day. He had specific desire for sweets but he had no specific aversion. He was a chilly patient. The patient also said that he had aggravation. From fatty food and cold drinks egg causes stomach pain.he had profuse perspiration especially on head and neck. Stool is satisfactory and regular. He had refreshing sleep 6-7 hrs per night.

On examination his vital parameters were normal.

**Analysis of Symptoms**

Mentals	Physical generals	Particulars
<ul style="list-style-type: none"> <li>▪ Introvert and diligent</li> <li>▪ Fears of darkness</li> <li>▪ Confused</li> <li>▪ Desire company</li> </ul>	<ul style="list-style-type: none"> <li>▪ Desire to sweets</li> <li>▪ Thirst is decreased</li> <li>▪ <b>Thermals:</b> Chilly</li> <li>▪ <b>Perspiration:</b> Profuse especially on head and neck</li> <li>▪ Agg, fatty food and cold drinks, evening washing</li> </ul>	<ul style="list-style-type: none"> <li>▪ Flat multiple warts on right forearm</li> <li>▪ Hard and painful to touch</li> <li>▪ Itching</li> <li>▪ Spreading continuously</li> </ul>

**Evaluation**

1. Introvert and diligent.
2. Fears of darkness.
3. Confused.
4. Desire company.
5. Desire to sweets.
6. Thirst is decreased.
7. **Thermals:** Chilly.
8. **Perspiration:** Profuse especially on head and neck
9. **Agg:** Fatty food and cold drinks, evening washing
10. **Amm:** Warmth
11. Flat multiple warts on right forearm
12. Hard and painful to touch
13. Itching.
14. Spreading continuously.

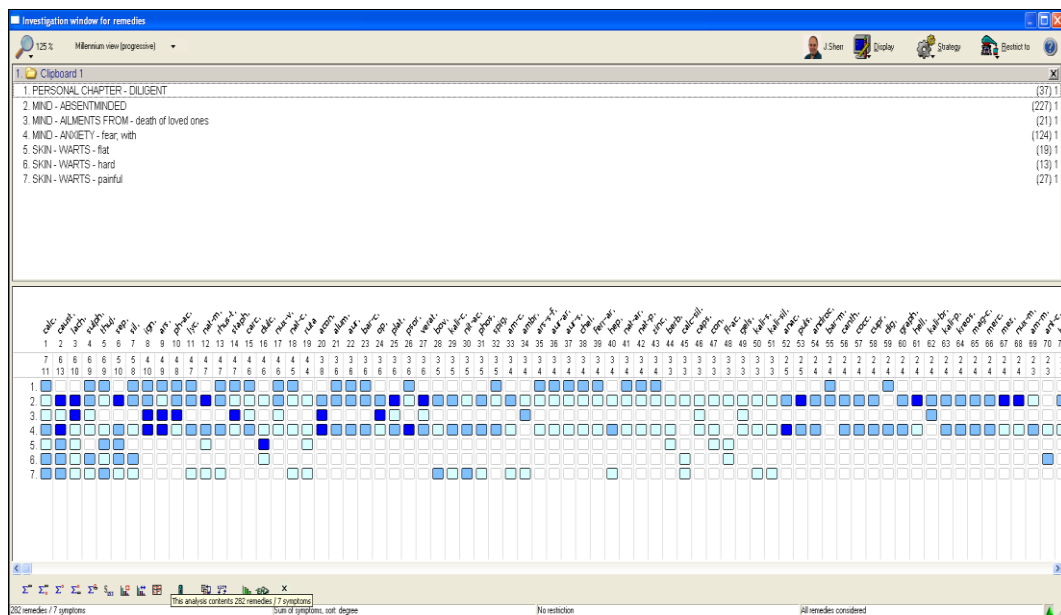
2. Fears of darkness.
3. Confused.
4. Desire company.
5. Desire to sweets.
6. Thirst is decreased.
7. **Thermals:** Chilly.
8. **Perspiration:** Profuse especially on head and neck
9. **Agg:** Fatty food and cold drinks, evening washing
10. **Amm:** Warmth
11. Flat multiple warts on right forearm
12. Hard and painful to touch
13. Itching
14. Spreading continuously

**Section of Repertory:** Synthesis repertory

**Totality of Symptoms**

1. Introvert and diligent.

**Repertory Sheet <sup>[4]</sup>**

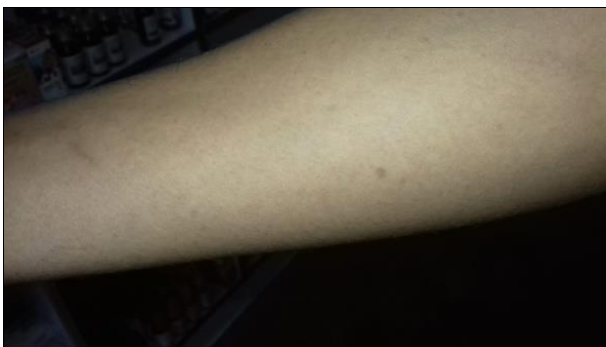
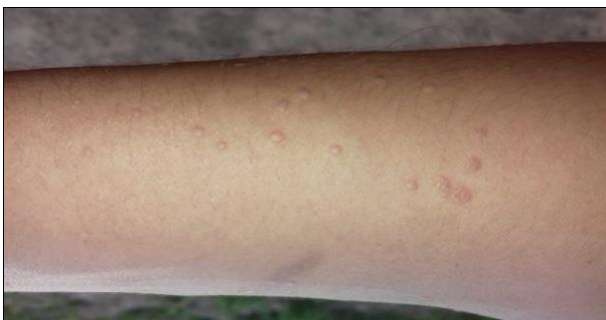
**Repertorial analysis**

Calcarea-carbonica - 11/7  
 Causticum - 13/6  
 Lachesis- 10/6  
 Sulph - 9/6  
 Thuja - 9/6

**Follow-ups**

Date	Symptoms	Prescription
07-04-2022 First Consultation	<ul style="list-style-type: none"> <li>▪ Flat wart on right forearm (Fig.1)</li> </ul>	Calcarea-carbonica 200/1 Dose/ Stat Phytum 30/ TDS/ 15 days
14-04-2022	<ul style="list-style-type: none"> <li>▪ No noticeable change in the complaint of warts.</li> <li>▪ Patient is feeling hopeful.</li> <li>▪ Normal stool, appetite and thirst</li> </ul>	Calcarea-carbonica 200/1 Dose/ Stat Phytum 30/ TDS/ 15 days
29-04-2022	<ul style="list-style-type: none"> <li>▪ Slight relief in itching and pain in warts.</li> <li>▪ Slightly decrease size of warts too.</li> <li>▪ Takes cold easily from slight exposure of cold air and temperature.</li> </ul>	Calcarea-carbonica 200/1 Dose/ Stat Rubrum 30/ TDS/ 15 days
13-05-2022	<ul style="list-style-type: none"> <li>▪ Patient noticed improvement seen</li> </ul>	Calcarea-carbonica 200/1 Dose/ Stat Phytum 30/ TDS/ 15 days
28-05-2022	<ul style="list-style-type: none"> <li>▪ Warts disappeared completely (Fig.2)</li> </ul>	Calcarea-carbonica 200/1 Dose/ Stat Rubrum 30/ TDS/ 15 days

**Fig 1:** Before image**Fig 2:** After image**Conclusion**

With the individualization of the case, Calcarea Carbonica was considered as the indicated remedy and it proved effective in the treatment of warts of the patient. According to the photographs attached above it is evidently seen that the patient is completely cured with no recurrence of warts.

**Conflict of Interest**

Not available

**Financial Support**

Not available

**References**

1. Mayo Clinic. Available from: <http://www.mayoclinic.org/diseases-conditions/commo>

**Selection of remedy with justification**

On the basis of totality of symptoms Calcarea-carbonica was prescribed [5].

**Prescription**

**Rx:** Calcarea-carbonica 200/ 1 Dose/ Stat  
 Sac Lac 30/ TDS for 15 Days

n-warts/basics/causes/con-20021715.[Last accessed on 2016 Jan 20].

2. Allen JH. The Chronic Miasms. Vol. 2. New Delhi: B. Jain Publishers; c2007. p. 65.
3. Illinois, University of Illinois at Urbana-Champaign, McKinley Health Center. Available from: <http://www.mckinley.illinois.edu/handouts/warts.html>. [Last accessed on 2016 Jan 20]
4. Radar Synthesis 9.0[Computer programme] Version10.7
5. Boericke W, Boericke O. Pocket Manual of Homoeopathic Materia Medical Comprising of the Characteristics and Guiding Symptoms of all Remedies. New Delhi: B. Jain Publishers Private Ltd.; c2012.
6. Farokh M. Diseases of the skin, B Jain Publisher. p. 128.
7. Khanna N. Illustrated synopsis of dermatology and sexually transmitted diseases. 5<sup>th</sup> ed. New Delhi: Reed Elsevier India Pvt. Ltd; c2016.
8. Dudgeon RE. Organon of Medicine. 5th edition: B jains Publishers; c2011.

**How to Cite This Article**

Sharma P, Jabdolia H, Pareek N, Choudhary S. Flat wart treated successfully by homoeopathy: A case report. International Journal of Homoeopathic Sciences. 2023;7(4):454-456.

**Creative Commons (CC) License**

This is an open access journal, and articles are distributed under the terms of the Creative Commons Attribution-NonCommercial-ShareAlike 4.0 International (CC BY-NC-SA 4.0) License, which allows others to remix, tweak, and build upon the work non-commercially, as long as appropriate credit is given and the new creations are licensed under the identical terms.