



# International Journal of Homoeopathic Sciences

E-ISSN: 2616-4493

P-ISSN: 2616-4485

[www.homoeopathicjournal.com](http://www.homoeopathicjournal.com)

IJHS 2024; 8(2): 88-92

Received: 14-02-2024

Accepted: 21-03-2024

**Dr. Bhawana Singh**

PG Scholar, Department of  
Materia Medica State National  
Homoeopathic Medical  
College, Lucknow, Uttar  
Pradesh, India

**Dr. Amit Nayak**

Professor and HOD,  
Department of Materia Medica  
State National Homoeopathic  
Medical College, Lucknow,  
Uttar Pradesh, India

**Dr. Khushboo Gupta**

PG Scholar, Department of  
Organon of Medicine and  
Homoeopathic Philosophy,  
State National Homoeopathic  
Medical College, Lucknow,  
Uttar Pradesh, India

**Corresponding Author:**

**Dr. Bhawana Singh**

PG Scholar, Department of  
Materia Medica State National  
Homoeopathic Medical  
College, Lucknow, Uttar  
Pradesh, India

## Effectiveness of homoeopathic medicine in treating filiform warts: A case report

**Dr. Bhawana Singh, Dr. Amit Nayak and Dr. Khushboo Gupta**

**DOI:** <https://doi.org/10.33545/26164485.2024.v8.i2b.1124>

### Abstract

Filiform warts resemble threads and have a pointed look. They are typically thought to be particularly irritating because they frequently appear on the face and occasionally resemble tiny brushes. The third most frequent skin condition we treat in our office is warts, which are said to be more common in adults than in youngsters. This article presents the example of a 29-year-old housewife who had filiform warts. The patient reported complete alleviation after taking homoeopathic medicine, which was chosen based on the patient's whole range of symptoms.

**Keywords:** Homoeopathy, filiform warts, sepia

### Introduction

Warts are benign, non-cancerous skin growths that can occur on different body areas and take on a variety of shapes. The human papilloma virus is the cause of them <sup>[1]</sup>. Adults frequently develop warts, which are highly contagious. Everybody must deal with it at least once in their lifetime. Only a small number of the HPV virus's more than 100 subtypes can result in skin warts at particular anatomical locations. Among these, HPV strains 1, 2, 4, 27, and 29 are responsible for filiform warts. It should be noted that exposure to these strains does not ensure the development of warts. In most cases, filiform warts spread by skin-to-skin contact, particularly in cases when the skin is damaged. Although they can be uncomfortable, they are not cancerous <sup>[2]</sup>. These warts seem differently than other warts. They have long, narrow projections that generally extend to 1 to 2 millimeters from the skin. They can be yellow, brown, or skin-toned, and generally form in clusters.

Males and females alike can develop benign epidermal growths on their anogenital areas called external genital warts (EGWs), which are typically sexually transmitted. Common, palmo-plantar, flat, mosaic, and Filiform are the subtypes of non-genital warts. These included common (40%), palmo-plantar (25%), plane (15%), mosaic (4%), and filiform/digitate (6%) forms morphologically <sup>[3]</sup>. Workers who handle raw meat, kids who frequently use public restrooms or swimming pools, relatives who already have warts, people with compromised immune systems, especially adults, and children who have had an organ transplant or in future had any serious disease like cancer or AIDS, and people with atopic conditions like eczema.

### Types of warts

- **Common warts:** These flesh-colored growths are most frequently found on the feet, fingers, backs of hands, and skin surrounding nails. They feel hard and rough, and they are about the size of a pea or a pinhead.
- **Planter warts:** These warts are usually found on the foot, particularly on the plantar area, or soles. They can contain black spots and are frequently flat or inward growing. They can grow to be rather huge and hurt when you walk or stand. Planter Warts: HPV types 1, 2, 4, 27 and 57.
- **Mosaic warts:** These warts resemble pinhead-sized white pimples. They usually appear beneath the toes or on the balls of the feet. But typically disperse and encompass greater regions of Mosaic warts are less painful when walking and are flatter than planter warts. Mosaic warts are caused by HPV type 2.
- **Flat warts:** You can get these warts anywhere on your body <sup>[4]</sup>. Compared to other

warts, they are smoother and smaller, and they often form in clusters of 20 to 100 at a time. Flat warts are caused by HPV types 3, 10, and 28.

- **Filiform warts:** These warts resemble protruding, lengthy threads. They frequently grow around your lips, eyes, and nose on your face. Filiform warts are caused by HPV types 1, 2, 4, 27, and 29.
- **Genital warts:** These warts (also known as anal warts) affect the rectum and genitalia. It is a skin-to-skin contact-transmitted sexually transmitted infection (STI). Small, hard nodules with rough surfaces are known as genital warts. HPV types 6 and 11 cause about 90% of genital warts.

#### Rare types of warts

- **Butcher's warts:** These warts typically appear on the hands of persons who handle raw meat, such as butchers<sup>[5]</sup>, and in those whose jobs require them to spend a lot of time in a chilly, damp environment. Butcher's warts are caused by HPV type 7.
- **Focal epithelial hyperplasia, also known as Heck's disease:** This uncommon ailment causes warts to grow in the mucosa of the mouth. In general, the warts are soft and have whitish to mucosal colors. Heck's disease is caused by HPV types 13 and 32.

#### Precautions to be taken

Warts can be prevented by taking a few precautions, such as not sharing towels, shoes, gloves, or socks, and avoiding touching or scratching the lesions to prevent the spread of the virus.

#### Treatment used in allopathy

There are numerous treatment options available to get rid of warts<sup>[6]</sup>. Using salicylic acid, liquid nitrogen, and podophyllin is one of these. Other methods include (a) loop electro-surgical excision process; (b) CO<sub>2</sub> laser surgery; and (d) interferon injections. Warts cannot be permanently cured by these treatments; they will always recur.

#### Treatment according to homoeopathy

The majority of skin warts are benign and can go away on their own without medical intervention. After treatment, warts can occasionally return, necessitating multiple types of care<sup>[7]</sup>. In this case, the homeopathic approach holds that in addition to extrinsic virulence, there is an innate predisposition to illness. Warts fall under the category of one-sided sickness in homeopathy. Sycosis miasm covers warts. The primary method of homeopathic treatment for warts is constitutional medicine, which is chosen based on a thorough understanding of the patient<sup>[8]</sup>. Based on the full spectrum of symptoms, a single well-indicated remedy is used for treatment.

#### Homoeopathy and Warts

One important aspect of treating warts is homoeopathy. The originator of homoeopathy, Hahnemann, gave an important description of the characteristics and nature of a wart under sycosis. Numerous medications have been utilized based on the location, kind, and characteristics of warts. Homoeopathy, on the other hand, solely provides internal medication without the need for external treatment<sup>[9]</sup>; in this sense, it treats disease inside and effectively for all time. As previously said, there are various medications available, but

a few of the most often used ones for warts are nitric acid, Sabina, Lycopodium clavatum, Thuja, Causticum, Dulcamara, Antimonium Crudum, and Natrum sulph. The current case study involving a filiform wart demonstrates the rapid and effective benefits of homoeopathic medicinal sepia. This case aims to demonstrate the effectiveness of homoeopathic treatment<sup>10</sup> for filliform warts.

#### Case report

NAME- Saman Fatima REGISTRATION NO.- 14586

AGE/Sex- 29/F DEPARTMENT- Skin (OPD- 2)

A case of 29 years old housewife, visited the OPD NO. 2 of National homoeopathic medical college, lucknow for the treatment of warty growth on her chin since 2 years. She had the history of prolonged use of allopathic treatment and had also under gone the process of cauterization (Laser Therapy) but again a warty growth appeared (bigger than before) on the chin along with scarring of the tissues around. Before the cauterisation her filliform warts was brown, hard, rough and large. Slight pain was also present while touching it. She had also used baking soda for its removal, but as such no response was there. She also complained about having excess of dead skin around her nails. She also complained of excessive bloating in stomach after eating the food and recurrent constipation. She had the tendency of having recurrent boils. She also had dry scaly dandruff in head.

#### History of present complaint

Wart were generally present since 2 years which gradually had increased in its size over the period of time. Significant cause was repeated removal by external application.

#### Past History

A patient experienced jaundice at the age of four and a renal stone at the age of twenty.

#### Family History

Her mother suffers from persistent dyspepsia and diabetes mellitus, her father has gout, and both of her grandparents have osteoarthritis in their knees. Other family members do not appear to be very unwell.

#### Physical generals

- **Appetite:** Easy satiety.
- **Taste:** Normal.
- **Tongue:** Slightly coated white.
- **Desire:** Acidic food; vinegar, pickles.
- **Aversion:** Cold foods.
- **Thirst:** Normal, dryness of lips.
- **Sweat:** Normal.
- **Stool:** Alternate loose and constipated.
- **Urine:** Normal.
- **Sleep:** Sleeplessness due to anxiety.
- **Position:** Lying on left side.
- **Dreams:** Anxious.
- **Worse:** From cold air.
- **Discharges:** Normal.
- **Obs/Gynae:** Leucorrhoea before menses<sup>++</sup>.
- **Menses:** Normal, 3-4 days.

#### Mental generals

##### Shy nature, Talk less

She had the intense anxiety about- 'Why I am not

conceiving if everything is normal'.  
 Not easily satisfy by anything done by others.  
 Brooding over anything said by others in a rude manner.  
 Intense anxiety about her health as well as others health.  
 Easily get worry about every matter.

**On examination**

A single, tough, well-defined, horny, dry wart measuring 3-4 mm was present over the chin.

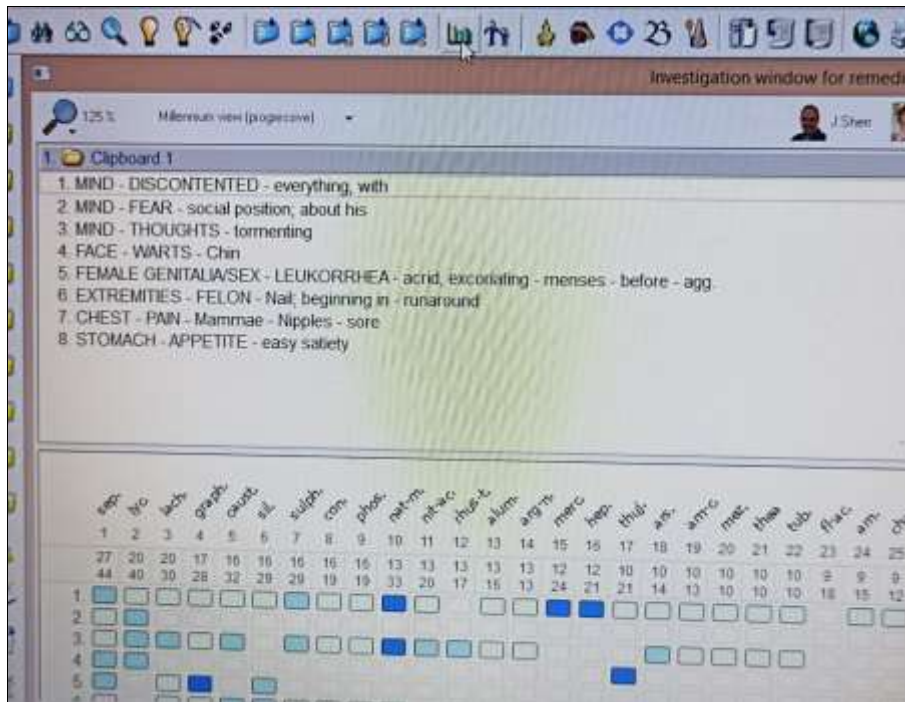
**Totality of symptoms**

- Dry and horny wart on chin.
- Discounted with everything.
- Tormenting about health.
- Acrid leuchorrea before menses.
- Complaints of felon around the nails.

- Constant sorness in nipples.
- A small meal easily fill the stomach.

**Repertorisation**

Repertorisation of case is been done through Synthesis repertory and the rubrics were taken as.  
 MIND – Discontented - everything with;  
 MIND - Fear- social position; about her  
 MIND - Thoughts- tormenting  
 FACE- Warts - chin  
 STOMACH - Appetite-easy satiety  
 FEMALE GENITALIA / SEX – Leuchorrea - acrid,  
 excoriating-menses-before-agg  
 EXTREMITIES - Felon-nail; beginning in-run around  
 CHEST - Pain – Mamme - Nipples- sore



**Fig 1:** Repertorial sheet

**First prscription**

In this case homoeopathic remedy SEPIA was selected on the basis of individualization and totality of symptoms. According to her overall constitutions sepia proved to be successful in the treatment of warts which appeared useful inspite of laser treatment in this case and the remedy also relived the other complaints of the patients. So, she was prescribed Sepia 30 three doses, followed by Sac. lac. - 30/ TDS for 20 days on the first visit (26 june 2020).

**Follow UP**

She began to get better after 20 days, and the warts got much better. She kept getting better. However, a small amount of scarring on the chin remained. By the time she received her two doses of Sepia1M prescription, her wart had entirely disappeared. After receiving a placebo for a while, she was placed under supervision before her therapy was stopped. After four months, she had no complaints, and the warts haven't come back since.

**Table 1:** Treatment Progress and Remedy Administration Timeline

Dates	Improvement in symptoms	Remedy / doses
16 july 2020	Intense anxiety was improved, dry and horny filliform wart was present, Exfoliation of nails was improved	SAC.LAC. - 30/ T.D.S
5 August 2020	Slight improvement in all symptoms except leuchorrea was not improved	SEPIA- 200/ 2 doses
26 August 2020	Wart was improving, leuchorrea was improved, Exfoliation of nails was absent	SAC.LAC - 30/ T.D.S
17 September 2020	50% improvement in wart and leuchorrea was also improved	SAC.LAC- 30/T.D.S
7 October 2020	Anxiety+, leuchorrea was absent, warts was present, slight chest pain was present	SEPIA - 1M/ 2 doses
28 October 2020	All symptoms were totally improved	SAC.LAC. - 30/T.D.S

## Result

There is marked improvement in filliform wart on the chin. Single medicine SEPIA was prescribed in subsequent potency followed by sac.lac. which showed the improvement and the wart was completely disappeared within a period of 4 months of homoeopathic treatment (Figure 1) Before treatment (Figure 2) After treatment.

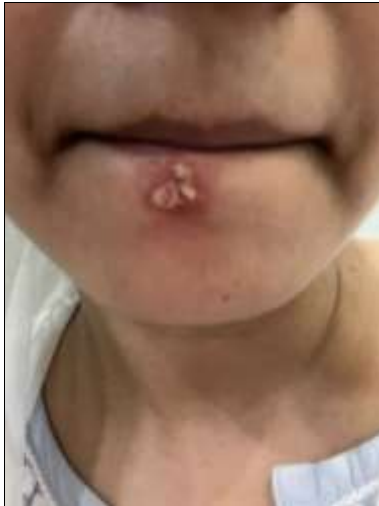

Fig 2: Before treatment

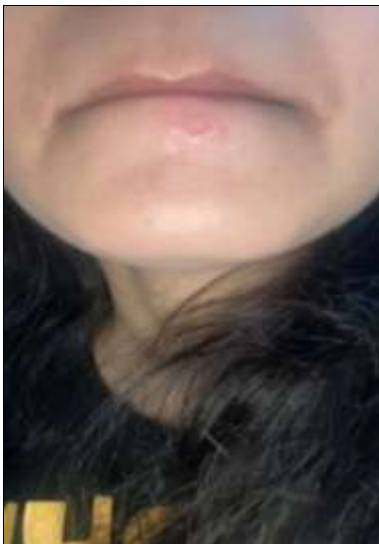


Fig 3: After treatment

## Discussion

In this instance, treatment has been administered for filiform wart, one of the wart subtypes. The case highlights how crucial individuality is when treating homoeopathic medicine. Following an extensive inquiry and review of the situation, wherein the fundamental principles outlined in the Organon of Medicine [11] have been applied to the consideration of mental generals, physical generals, and the peculiarities of the local sickness. Following the extraction of the case's key criteria, the case has been repertorized from the synthesis software. With seven out of eight rubrics and eighteen marks, the repertorial result reveals Sepia to be the most effective homoeopathic medicine (figure 1). Six rubrics were also addressed by Lyco and Graph, however these medications do not address other significant symptoms, such as horny warts, which are less severe in both cases. The filliform warts on the chin and discontented

feeling are the important symptoms for the prescribing sepia and graded in a higher degree. In light of all the information gathered, including consultation with Materia Medica [12], Sepia in potency 30 has been determined to be the best course of action for this particular case. The patient will be prescribed to take three doses of this medication on an empty stomach, three times a day, along with placebo pills, for a period of twenty days (Table 1). Follow-up appointments will be scheduled every twenty days. A photograph was taken on the first visit (Figure 1), and further visits will show a marked improvement. Figure 2 is the final photograph taken on the last visit.

## Conclusion

The success of internal medicine combined with customized homoeopathic medicine in the treatment of warts is demonstrated by the current case [13]. On the other hand, the outcomes of this one case report are by no means definitive as to the long-term clinical efficacy of homeopathy for warts. To prove that homoeopathy is beneficial and efficient in treating various illnesses, well-designed research are necessary [14].

## Acknowledgement

Financial Support and Sponsorship: Nil.

## Conflicts of Interest

There are no conflicts of interest.

## References

1. Sterling JC, Handfield-Jones S, Hudson PM. British Association of Dermatologists. Guidelines for the management of cutaneous warts. *Br J Dermatol.* 2001;144:4-11.
2. Buck W Jr. Warts (genital). *BMJ Clinical Evidence;* c2010. p. 1602.
3. Ghadgepatil SS, Gupta S, Sharma YK. Clinicoepidemiological Study of Different Types of Warts. *Dermatology Research and Practice;* c2018. p. 7989817.
4. U.S. National Library of Medicine. Warts: Overview. 04 May 2017. Archived from the original on 20 January 2018.
5. Shaikh B. MI. Case studies for treatment of warts with Homoeopathy. *Indian J Res Homoeopathy.* 2016;10:272-278.
6. WebMD. Skin problem and treatment. Available from: <https://www.webmd.com/skin-problems-and-treatments/ss/slideshow-warts>.
7. Berth-Jones J, Hutchinson PE. Modern treatment of warts: cure rates at 3 and 6 months. *Br J Dermatol.* 1992;127(3):262-265. DOI: 10.1111/j.1365-2133.1992.tb00125.x.
8. Campion MJ. Clinical manifestations and natural history of genital human papillomavirus infection. *Obstet. Gynecol. Clin. North Am.* 1987;14(2):363-388.
9. Al About AM, Nigam PK. Wart (Plantar, Verruca Vulgaris, Verrucae); c2019 Sept 27. Available from: <https://www.ncbi.nlm.nih.gov/books/NBK431047/>.
10. WebMD. Skin Conditions and Warts. Available from: <https://www.webmd.com/skin-problems-and-treatments/warts#1>.
11. Kent JT. Lectures on Homoeopathic Materia Medica. Reprint edition 2005. B. Jain Publishers (P) Ltd.

12. Hahnemann S. The Chronic Diseases Their Peculiar Nature and Their Homoeopathic Cure. Reprint Edition. New Delhi: B. Jain Publishers (P) Ltd; c2009. p. 98-100.
13. Allen HC. Keynotes and Characteristics with Comparison of some of the Leading remedies of the Materia Medica with Bowel Nosodes. Low price Edition. New Delhi: B. Jain Publishers (P) Ltd; c2002.
14. Hahnemann S. Organon of Medicine. 5<sup>th</sup> edition translated by Dudgeon RE and 6<sup>th</sup> edition by Boericke W. New Delhi: B. Jain Publisher (P) Ltd; c2002.

**How to Cite This Article**

Singh B, Nayak A, Gupta K. Effectiveness of homoeopathic medicine in treating filiform warts: A case report. International Journal of Homoeopathic Sciences. 2024; 8(2):88-92.

**Creative Commons (CC) License**

This is an open access journal, and articles are distributed under the terms of the Creative Commons Attribution-NonCommercial-ShareAlike 4.0 International (CC BY-NC-SA 4.0) License, which allows others to remix, tweak, and build upon the work non-commercially, as long as appropriate credit is given and the new creations are licensed under the identical terms.