



International Journal of Homoeopathic Sciences

E-ISSN: 2616-4493

P-ISSN: 2616-4485

www.homoeopathicjournal.com

IJHS 2024; 8(3): 294-296

Received: 17-06-2024

Accepted: 19-07-2024

Dr. Amrita Sahni

Unit Doctor, Dr Batra's
Positive Health Clinic Pvt.
Ltd., BHMS, Sector 18, Noida,
Uttar Pradesh, India

Homeopathic intervention in benign tumor

Dr. Amrita SahniDOI: <https://doi.org/10.33545/26164485.2024.v8.i3e.1230>**Abstract**

A benign tumor, such as a cyst, is a non-cancerous growth that can persist for many years. These conditions are common worldwide, affecting millions of people. Homeopathy takes a holistic approach to treating such conditions by considering the patient's overall health and symptoms. This paper presents a case study of a 68-year-old woman who had a benign cyst for 40 years. After an initial homeopathic treatment provided partial relief, she later sought help from Dr. Batra's clinic. Under the care, the cyst increased in size before bursting and fully draining, leaving only an empty cavity. This case highlights the effectiveness of homeopathic treatment in managing long-standing benign tumors.

Keywords: Benign tumor, homeopathy treatment, intervention, benign tumor**Introduction**

Benign tumors, such as cysts, are non-cancerous growths that develop in various tissues and organs. They are typically caused by factors like genetic mutations, infections, or inflammation. Although benign, these tumors can cause discomfort, pain, or other symptoms depending on their location and size. Common symptoms include swelling, pain, and pressure on nearby structures. While not life-threatening, benign tumors may require treatment if they grow or cause significant symptoms. Homeopathy treats these conditions by addressing the underlying causes and the patient's overall health, offering a holistic approach to long-term management.

Case Profile

A 68-year-old female presented with a benign cyst that had persisted for 40 years. Initially, she sought homeopathic treatment, which led to partial leakage of the cyst but did not result in complete drainage. Unable to continue the treatment, the cyst returned to its original state. Later, under homeopathic care from Dr. Batra's clinic, the cyst grew in size, eventually burst, and fully drained, leaving only an empty cavity. The patient also has a history of diabetes, which occasionally spikes due to sweet intake and lack of exercise, though she generally manages it well with allopathic medicine.

Physical generals

Diet	Primarily Vegetarian
Appetite	Medium
Desire	Salty, Chatpata
Aversion	Bhaigan, Bindi, Urad Dal as it leads to itching
Thermal Reaction	Ambithermal
Thirst	Good
Stools	Normal
Urine	Normal
Perspiration	Normal
Sleep	Normal
Dreams	Ns

Examination

"Initially, the patient had a hard, non-movable cyst with no itching. After a few months, the cyst gradually burst, leaving only a small dent in its place".

Corresponding Author:**Dr. Amrita Sahni**

Unit Doctor, Dr Batra's
Positive Health Clinic Pvt.
Ltd., BHMS, Sector 18, Noida,
Uttar Pradesh, India

Mental Generals

The patient is a 68-year-old female with a calm and easygoing nature. She is generally cheerful, friendly, and enjoys talking. She doesn't get upset easily and is not overly sensitive. However, she occasionally gets angry when conversations aren't proper, and this anger is mostly directed at her husband. She mentioned that the only times she felt stressed were when her in-laws and parents passed away, but overall, she has not experienced any major turning points in her life. She finds happiness in watching her grandchildren play.

Past history

"Previously, the patient had taken homeopathic medicines, which caused the cyst to start leaking. However, due to an

inability to continue the treatment, the cyst reverted to its original state".

Family history

Nothing specific

Case analysis: Repertorial totality

Repertory used	Rubrics selected
Synthesis	• Mind: Affectionate
	• Mind: Cheerful
	• Mind: Loquacity
	• Generals: Food and drinks - Salt - Desire
	• Skin: Excrescences

Repertory screenshot

	phos.	caust.	nat-m.	st-aph.	lach.	verat.	nit-ac.	carb-v.	thuji.	nux-v.	plb.
1. MIND - AFFECTIONATE (36)	2	2	2	2	1	1	1	1	2		
2. MIND - CHEERFUL (188)	2	1	1	1	3	2	2	1	1	2	1
3. MIND - LOQUACITY (125)	2	1	1	1	4	2			1	1	2
4. GENERALS - FOOD and DRINKS - salt - desire (40)	4	2	4	1		4	2	3	2		2
5. SKIN - EXCRESCENCES (39)	1	3	1	3	1		3	2	3	1	1

Selection of remedy

Thuja 1M was prescribed as the primary antisycotic remedy to facilitate the rupture or absorption of the cyst, and it also served as an intercurrent remedy. Additionally, Conium 30,

Phytolacca 30 and Calcarea Fluorica 30 and 6x were administered to target the growth, as these remedies are specifically indicated for such conditions.

Miasmatic approach

Symptoms	Psora	Sycosis	Syphilis	Tubercular
Mind: Affectionate		X		
Mind: Cheerful		X		
Mind: Loquacity		X		
Generals: Desire for Salt				X
Skin: Excrescences		X (Thuja)		

Miasmatic predominance: Sycosis

Materials and Methods: Synthesis repertory

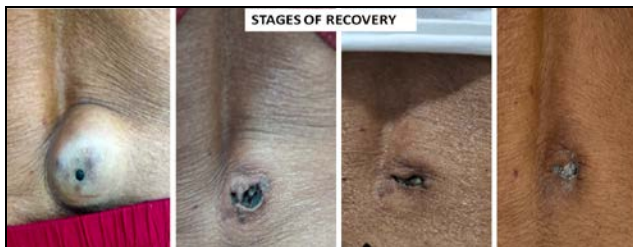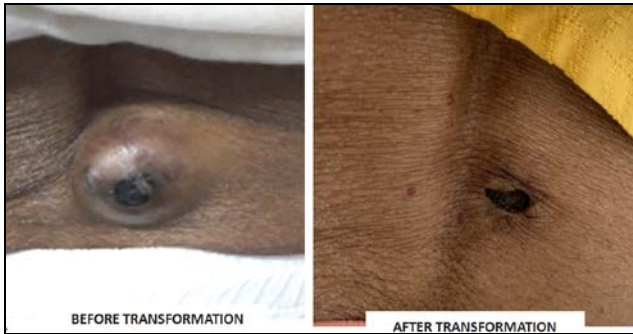Results

Month	Progress	Prescription
1 st month	Size of the cyst increased	Thuja 1M, Conium 30, Calcarea Fluorica 6X
2 nd month	Patient felt size was increasing, took 2 months' medicine together	Conium 30, Calcarea Fluorica 6X
3 rd month	Took 2 months' medicine together	Conium 30, Calcarea Fluorica 6X
4 th month	Blackish discoloration increased, as per old photos	Thuja 1M, Conium 30, Calcarea Fluorica 6X
5 th month	Size increase doubts	Thuja 1M, Phytolacca 30, Calcarea Fluorica 6X, Kali Bromatum 30
6 th month	Took 3 months' medicine together	Same as 5 th month prescription
7 th month	Took 3 months' medicine together	Same as 5 th month prescription
8 th month	Took 3 months' medicine together	Same as 5 th month prescription
9 th month	Better, cyst ruptured, patient said the cyst improved	Thuja 1M, Phytolacca 30, Calcarea Fluorica 6X, Kali Bromatum 30
10 th month	Cyst became flat without any issues	Thuja 1M, Phytolacca 30, Calcarea Fluorica 6X
11 th month	Cured	Thuja 1M, Phytolacca 30, Calcarea Fluorica 6X, Silicea 6X
12 th month	No issues remain	Thuja 1M, Phytolacca 30, Calcarea Fluorica 6X, Silicea 6X

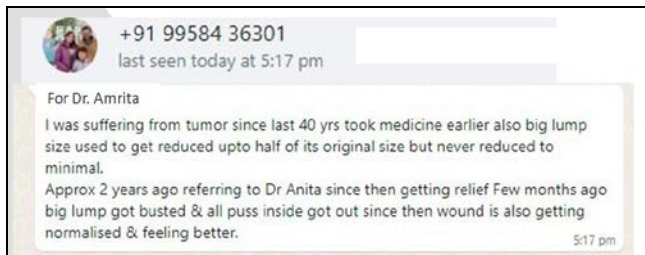
Discussion and Conclusion

The treatment demonstrated the effectiveness of homeopathy in managing a silent tumor. Thuja 1M initiated the tumor's shift, allowing Conium, Calcarea Fluorica, and Phytolacca to facilitate its gradual reduction and cleansing. Silicea was later given as a final remedy to complete the healing process. Kali Bromatum, prescribed by another doctor, had an uncertain impact. This case underscores homeopathy's potential in treating complex conditions through a personalized and miasmatic approach, leading to a successful resolution.

The transformation



Testimonial



Acknowledgments

I extend my sincere thanks to Dr. Vikas and Dr. Nitin Kothawde for their invaluable support in selecting the remedies that led to the patient's successful recovery. I also deeply appreciate the patient's patience throughout the treatment process.

References

1. Mathur M. Pituitary microadenoma treated with individualized homeopathic medicine: A case report. *Homeopathy*. 2020 Nov;109(04):243-247.
2. Ahmad S, Rehman T, Abbasi W. Homeopathic approach for the treatment of cancer. *Indian Journal of Research in Homeopathy*. 2018;12(3):157-163.
3. Choudhury S, Goswami P, Bukhsh KAR. Traumatic tongue fibroma treated with individualized homeopathic remedies: A case report with a brief literature review. *J Clin Images Med Case Rep*.

2022;3(7):1926.

4. Koch A, Ellis J, Gyllenhaal C, Tripathy D, Lo C, Oberbaum M, Samuels N, Singer SR, Gupta G, Block K. Integrative tumor board: metastatic breast cancer. *Integrative Cancer Therapies*. 2006 Dec;5(4):373-90.
5. Parikh N. True Surgical Cases in Homeopathy. *Homeopathic Links*. 2015 Mar;28(01):027-32.

How to Cite This Article

Sahni A. Homeopathic intervention in benign tumor. *International Journal of Homeopathic Sciences*. 2024;8(3):294-296.

Creative Commons (CC) License

This is an open-access journal, and articles are distributed under the terms of the Creative Commons Attribution-Non Commercial-Share Alike 4.0 International (CC BY-NC-SA 4.0) License, which allows others to remix, tweak, and build upon the work non-commercially, as long as appropriate credit is given and the new creations are licensed under the identical terms.