



International Journal of Homoeopathic Sciences

E-ISSN: 2616-4493

P-ISSN: 2616-4485

www.homoeopathicjournal.com

IJHS 2025; 9(1): 55-58

Received: 28-10-2024

Accepted: 30-11-2024

Dr. Ratnajit Talukdar

Chief Homeopathic
Consultant, Howrah Branch,
Dr. Batra's Positive Health
Clinic Pvt. Ltd., BHMS,
Mumbai, Maharashtra, India

Managing atopic dermatitis leading to erythroderma with homeopathy

Ratnajit TalukdarDOI: <https://doi.org/10.33545/26164485.2025.v9.i1.A.1344>**Abstract**

Atopic dermatitis is a chronic inflammatory skin condition that can progress to erythroderma in severe cases, affecting millions worldwide. This case study focuses on a 70-year-old female with advanced atopy came at Dr Batra's positive health clinic. This patient tried many allopathic treatments but failed to provide lasting relief. Homeopathic intervention resulted in significant improvement and preventing progression to erythroderma. This paper highlights the holistic approach of homeopathy in addressing systemic imbalances, offering sustainable relief in chronic dermatological conditions like AD.

Keywords: Atopic dermatitis, erythroderma, homeopathy**Introduction**

Atopic dermatitis (AD) is a chronic inflammatory skin condition characterized by intense itching, redness, dryness, and scaling, often associated with genetic predisposition, environmental triggers, and immune system dysfunction. Common causes include allergens, irritants, extreme temperatures, and stress, while elevated IgE levels are a hallmark of its allergic component. Symptoms range from mild itching and dryness to severe oozing, crusting, and thickened skin. Left untreated, AD can lead to complications such as skin infections, erythroderma, and a significant impact on mental health and quality of life.

Case Profile

A 70-year-old widow with chronic dermatitis for over ten years presented with severe itching, burning sensations, thick scaling, and offensive oozing, particularly behind the ears and on her scalp. Her symptoms included intense itching, bleeding from scratching, and a foul-smelling discharge, which worsened at night, after bathing, and with cold air exposure. The condition, affecting her whole body but predominantly the flexor surfaces, face, and neck, was accompanied by extreme skin dryness, recurrent flaking, and cracks that oozed when exposed to water. She had a history of hypothyroidism, hypertension, anemia, chronic constipation, and recurrent leg pain, adding complexity to her case. Warm clothing and protection from cold provided some relief.

Table 1: Physical Generals

Appetite	Less
Diet	Mixed diet
Thirst	Scanty, 1-1.5 lit per day
Aversion	N.S.
Intolerance	Brinjals, prawns
Craving	Sweets-++, tea
Sleep	Scanty 5-6 hrs per day
Dreams	Nothing such
Urine	N.A.D.
Stool	Constipated
Perspiration	Moderate, N.O., N.S.
Thermal Response	Chilly
Mens/Obs history	Menopausal Obs: 1 daughter - 38 years, FTND

Corresponding Author:

Dr. Ratnajit Talukdar
Chief Homeopathic
Consultant, Howrah Branch,
Dr. Batra's Positive Health
Clinic Pvt. Ltd., BHMS,
Mumbai, Maharashtra, India

Mental Generals

Mentally, she was once a calm and sociable person who mingled easily and enjoyed company. However, after her husband's death, she became more irritable, headstrong, and fastidious, though she still maintained a love for traveling and social interactions.

She expressed great concern for her daughter, with whom she resides, and her emotional state was deeply affected by life events, such as the happiness of her daughter's birth and the sadness of her father's death.

Despite these stressors, she shared good terms with her siblings. Initially, her severe physical condition led to feelings of despair, including suicidal ideation, but over time, her mental state improved significantly with treatment, and she expressed happiness and gratitude for the progress made.

Past History

Recurrent neuralgic pains over her legs.
 Recurrent prickly rashes, better in monsoon seasons.
 Pox. Mild sinusitis
 Cataract surgery done.

Family History

Father-sciatica,
 Mother- Skin Allergies, HTN, DM, Cardiac Asthma

- **Husband:** Died of CKD with HTN

- **Daughter:** SLE, AS, LIH, Hypothyroidism

Case analysis

- Repertorial totality
- Mind, despair, suicidal disposition
- Mind, hopelessness
- Mind, oversensitive, cold, to
- Skin, itching, intolerable
- Skin, dry
- Skin, rough
- Skin, eruptions, eczema
- Skin, discharges, offensive
- Skin, discoloration, dirty appearance
- Generals, cold, aggravation from
- Generals, weakness, debility, extreme
- Hair, dry
- Hair, lusterless

Repertory used	Rubrics selected
Repertory Name	SKIN - ITCHING - bathing - agg SKIN - ITCHING - bathing - after SKIN - WARTS - bathing agg SKIN - WARTS GENERAL - COLD - agg GENERAL - COLD - air - agg MIND - SUICIDAL DISPOSITION

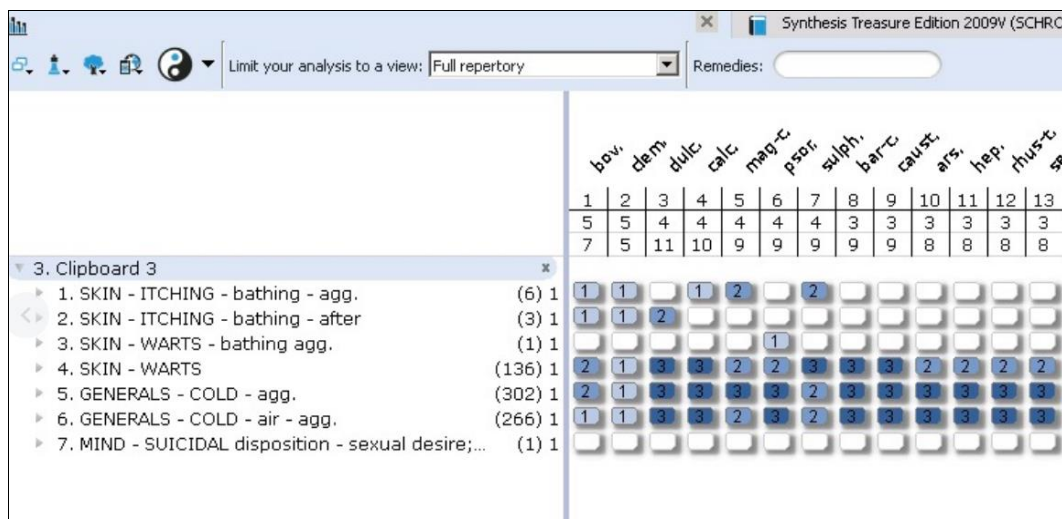


Fig 1: Repertory screenshot

Table 2: Selection of Remedy

Remedy	Reasons
Psorinum 0/2- 0/14	Patient is extremely sensitive to cold Extreme debility Suffering from debilitating chronic disease like hypothyroidism Patient is hopeless with suicidal tendency All discharges are very foul smelling Skin have very dirty look, dry Lustreless, rough hair with intolerable itching

Table 2: Miasmatic Approach

Symptoms	Psora	Sycosis	Syphilis	Tubercular
Severe itching	Present			
Burning sensation	Present			
Thick scaling		Present		
Offensive oozing		Present		Present
Bleeding after scratching			Present	
Cracks in skin			Present	
Foul-smelling discharge		Present	Present	
Aggravation from cold air	Present			Present
Recurrent flaking		Present		Present
Chronicity and relapses		Present		Present

Materials and Methods

Synthesis repertory was used for repertorization

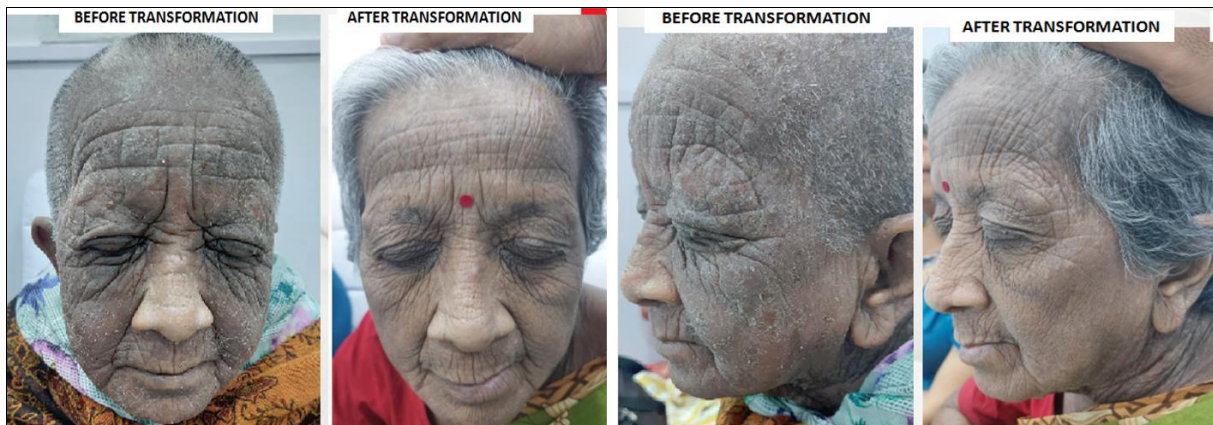Results

Appointment Date	Patient Remarks	Remedy Given with Potency
30/06/2024		Graphites 30C, Sulphur 1M
14/07/2024		Sac-L, Sulphur 1M, Calendula MT (Q)
19/07/2024		Immunoforce
28/07/2024	Long-standing ailments, dry skin, cracks with oozing, better in monsoons, craving for sweets and tea, chilliness, irritability.	Arsenicum Album 6C Belladonna 30C Ferrum Phos 6X Mezereum 6C
24/08/2024	<<	Psorinum (0/6 & 0/8)
21/09/2024	Skin lesions 50% better, itching persists in the morning and after bathing.	Psorinum (0/10 & 0/12)
22/09/2024	>	Psorinum (0/10 & 0/12)
27/10/2024	>	Sac-L
10/11/2024	No oozing, flaking reduced, itching persists after bathing, chilliness normalized.	Psorinum (0/13 & 0/14) Sac-L

Discussion and Conclusion

This case of a 70-year-old widow with chronic dermatitis highlights the effectiveness of individualized homeopathic treatment in addressing complex, long-standing skin conditions. The patient presented with severe itching, burning sensations, thick scaling, offensive oozing, and a foul odor, significantly impacting her quality of life. After years of unsuccessful allopathic treatments, homeopathy

focused on her miasmatic predominance, systemic issues, and specific aggravations. Remedies tailored to her symptoms brought significant improvement, including reduced oozing, odor, and scaling, along with 50% relief in itching. This case underscores the holistic and sustainable approach of homeopathy in managing chronic dermatological ailments.



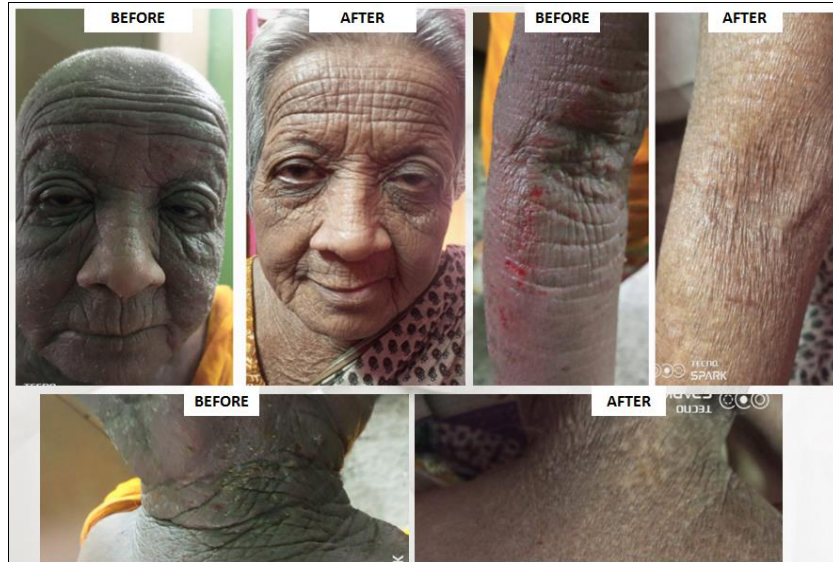

Fig 2: The transformation

Acknowledgments

I take this Opportunity to thank those who have helped and supported me personally and professionally during this case study.

Conflict of Interest

Not available.

Financial Support

Not available.

References

1. Sharma B. Management of atopic dermatitis with homeopathy-a clinical study. *Int J Homoeopath Sci.* 2018.
2. Hill P, Hoare J, Lau-Gillard P, Rybnicek J, Mathie R. Pilot study of the effect of individualised homeopathy on the pruritus associated with atopic dermatitis in dogs. *Vet Rec.* 2009;164:364-370.
3. Siebenwirth J, Lüdtkke R, Remy W, Rakoski J, Borelli S, Ring J, *et al.* Effectiveness of a classical homeopathic treatment in atopic eczema: A randomized placebo-controlled double-blind clinical trial. *Forsch Komplementmed.* 2009;16(5):315-323.
4. Miyashiro D, Sanches J. Erythroderma: A prospective study of 309 patients followed for 12 years in a tertiary center. *Sci Rep.* 2020, 10.
5. Moy A, Murali M, Kroshinsky D, Duncan L, Nazarian R. Immunologic overlap of helper T-cell subtypes 17 and 22 in erythrodermic psoriasis and atopic dermatitis. *JAMA Dermatol.* 2015;151(7):753-760.

How to Cite This Article

Talukdar R. Managing atopic dermatitis leading to erythroderma with homeopathy. *International Journal of Homoeopathic Sciences.* 2025;9(1):55-58.

Creative Commons (CC) License

This is an open access journal, and articles are distributed under the terms of the Creative Commons Attribution-NonCommercial-ShareAlike 4.0 International (CC BY-NC-SA 4.0) License, which allows others to remix, tweak, and build upon the work non-commercially, as long as appropriate credit is given and the new creations are licensed under the identical terms.