



# International Journal of Homoeopathic Sciences

E-ISSN: 2616-4493  
P-ISSN: 2616-4485  
[www.homoeopathicjournal.com](http://www.homoeopathicjournal.com)  
IJHS 2025; 9(1): 190-194  
Received: 06-12-2024  
Accepted: 02-01-2025

**Dr. Saroj Ranjit Sawant**  
Department of Homoeopathic  
Materia Medica, Dr. JJ  
Magdum Homoeopathic  
Medical College, Jaysingpur,  
Maharashtra, India

**Dr. Angaraj Mansingrao Mane**  
Department, Department of  
Homoeopathic Materia  
Medica, Dr. JJ Magdum  
Homoeopathic Medical  
College, Jaysingpur,  
Maharashtra, India

**Dr. Vidya Manish Ghevde**  
Department of Repertory, Dr.  
JJ Magdum Homoeopathic  
Medical College, Jaysingpur,  
Maharashtra, India

**Dr. Pranav Shrikant Nimankar**  
Department of Surgery, Dr JJ  
Magdum Homoeopathic  
Medical College, Jaysingpur,  
Maharashtra, India

**Dr. Pooja Sudhakar Shinde**  
Department of Community  
Medicine, Dr JJ Magdum  
Homoeopathic Medical  
College, Jaysingpur,  
Maharashtra, India

**Dr. Sneha Mahadeo Jogdande**  
Department of Practice of  
Medicine, Dr JJ Magdum  
Homoeopathic Medical  
College, Jaysingpur,  
Maharashtra, India

**Corresponding Author:**  
**Dr. Saroj Ranjit Sawant**  
Department of Homoeopathic  
Materia Medica, Dr. JJ  
Magdum Homoeopathic  
Medical College, Jaysingpur,  
Maharashtra, India

## Efficacy of homoeopathic management in trophic skin ulceration of leprosy: A case report

**Saroj Ranjit Sawant, Angaraj Mansingrao Mane, Vidya Manish Ghevde, Pranav Shrikant Nimankar, Pooja Sudhakar Shinde and Sneha Mahadeo Jogdande**

**DOI:** <https://doi.org/10.33545/26164485.2025.v9.i1.C.1354>

### Abstract

Leprosy is an infection caused by the bacillus *Mycobacterium leprae*, which is acid-fast and rod-shaped. The condition is treatable, and early intervention can prevent disabilities. Several homeopathic remedies are available for the treatment of leprosy. Homeopathic treatment addresses both physical and mental health comprehensively. In this particular case of leprosy, *Mercurius Solubilis* was selected as a single homeopathic remedy. The aim is to demonstrate the comprehensive effects of *Mercurius Solubilis* in treating leprosy at a private homeopathic clinic located in Kolhapur, Maharashtra. A 40-year-old individual with leprosy received a tailored homeopathic treatment from 2018 until January 2022. The therapy involved the selection of the homeopathic remedy *Mercurius Solubilis* specifically suited to the patient. During follow-up appointments, the outcomes were evaluated through a thorough examination of the skin lesions and general assessment criteria. Over a three-month observation period, positive results from the homeopathic remedy were observed regarding both the skin lesions and general symptoms. The homeopathic remedy *Mercurius Solubilis* demonstrated clinical significance in the context of leprosy. A clinical assessment of the role of *Mercurius Solubilis* in leprosy was conducted with a holistic perspective.

**Keywords:** *Mercurius Solubilis*, homoeopathy, leprosy, holistic perspective

### Introduction

Leprosy is a chronic infectious disease caused by a bacillus, *Mycobacterium leprae*. *M leprae* multiplies slowly and the disease incubation period, on average, is 5 years (WHO, 2022) [1]. Leprosy was once feared as a highly contagious and devastating disease, but now we know it doesn't spread easily and treatment is very effective. However, if left untreated, the nerve damage can result in crippling of hands and feet, paralysis, and blindness.

The homoeopathic employment of medicines according to the similarity of symptoms must effect a permanent and perfect cure, if at the same time the opposite of their large doses, the most-minute doses, are exhibited (S., 2012) [3].

William Boericke (1849-1929) was an Austrian-born American physician who became a influential exponent of homeopathy. He has given references for remedies to leprosy in his book

### Lepra, leprosy

*Anac, Ars., Bad., Calopt, Carb. ac., Chaulmugra, Commocl, Cupr. ac., Cur., Dipterocarpus, Elcis, Graph, Guano, Gynocardia, Hoang n., Hura, Hydrocot, Jatropha goss, Lach., Merc. S., Śnanthe, Phos, Pip. m., Sec., Sep., Sil, Thyr.* (Boericke, 2010) [4].

A Borderline Lepromatous (BL) leprosy case was treated with *Mercurius solubilis*, a homoeopathic medicine for two years. The patient showed appreciable improvement in clinical signs and symptoms (Chakraborty D, 2014) [5].

This case study was carried out to see the efficacy of homoeopathic management in the trophic skin ulceration of leprosy.

### Patient Information

A 40-year-old man, Mr. B.M., visited our outpatient department on 29/09/2018. He worked as a tempo driver and had been feeling very down and depressed due to a slow-healing lepromatous wound on his fourth toe for the past week.

A year earlier, he had been diagnosed with lepromatous leprosy and foot ulcers. His treatment included multi-bacillary multi-drug therapy along with various topical medications for his ulcers. After about 50 days, he noticed some improvement. Three months into the treatment, the ulcers on his toes had nearly completely healed, though he was left with stigma due to tissue loss on his toes. His illness forced him to quit his job. Despite having made a recovery, he felt ashamed and was apprehensive about returning to work because of his disfigured foot. His family provided moral support and attempted to change his perspective, but their efforts were unsuccessful. He continued to stay at home, burdened by anxiety regarding his condition. He believed it was a divine punishment due to his past wrong doings. This feeling of despair persisted even after he had healed. He was constantly anxious about his family's well-being. Six months later, his symptoms returned. He turned to homeopathy, feeling even more apprehensive about his illness. He experienced hopelessness about his recovery and felt miserable regarding his health. A comprehensive case evaluation revealed significant insights.

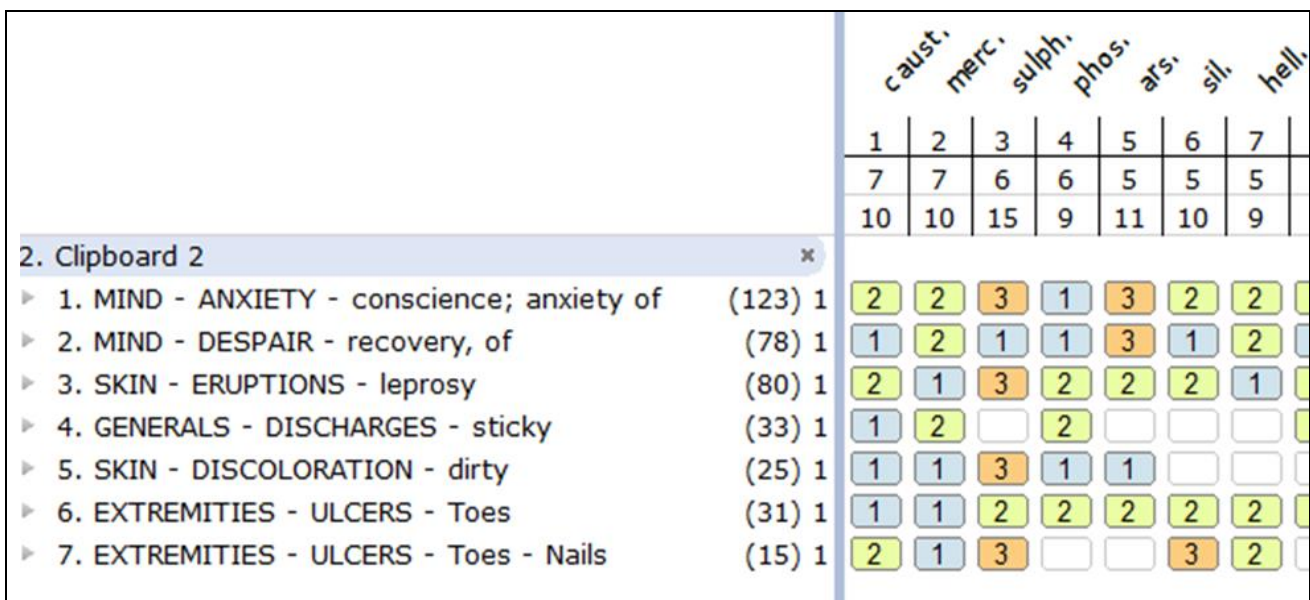
He had been hospitalized for gastroenteritis during his childhood. He follows a non-vegetarian diet and has irregular eating patterns. His appetite has decreased, but he is able to endure hunger. He craves spicy foods and avoids leafy greens, consuming only about half a liter of water daily. He experiences excessive sweating, particularly under his arms. His sleep is limited and often disrupted by his health issues. He is sensitive to both hot and cold temperatures. Mentally, he expressed hopelessness about recovery, worry about his illness, reluctance to engage socially or converse with others, and concern for his family's future. Physical examination revealed trophic ulcers on the third and fourth toes of his right foot, a prior deformity on the great toe, swelling, and unhealthy skin. The wounds emitted an unpleasant odor and produced a serosanguinous discharge. Pulsation was noted as well. Prominent symptoms of syphilis were evident in this case.

**Diagnostic Assessment**

The symptoms of the patient have been analyzed as per the Kentian method of analysis & evaluation.

Sr. No.	Totality of symptoms	Reportorial Rubrics
1	Anxiety with done some crime or neglected duty	Mind - Anxiety - conscience; anxiety of
2	Despair of recovery	Mind - Despair - recovery, of
3	Discharges are sticky	Generals - Discharges - sticky
4	Lepromatous leprosy	Skin - Eruptions - leprosy
5	Dirty look of skin	Skin - Discoloration - dirty
6	Trophic ulceration of toes	Extremities - Ulcers - Toes
7	Ulceration of nails	Extremities - Ulcers - Nails

The reportorial result is shown in Figure 1



**Fig 1:** Repertorisation





In this case, repertorisation was carried out using the computer Homoeopath classic software, using complete Repertory. The top-ranked medicines Causticum, & Mercurius solubilis were found after repertorisation. Causticum usually manifests its action mainly in chronic rheumatic, arthritic, and paralytic affections, indicated by the tearing, drawing pains in the muscular and fibrous tissues, with deformities about the joints, progressive loss of muscular strength, and tendinous contractures. Bur Mercurius solubilis shows ulcers in general with burning on

the edges hard on the edges with bloody pus; with corroding pus swollen on edges (J.H., 2017) [7].

**Therapeutic Intervention**

Though totality of the case favored the selection of Causticum & Mercurius solubilis which scores high place after repertorisation. After referring Materia medica for symptom picture, Mercurius solubilis was selected in 30C potency.

**Follow-Up and Outcomes**

Visit	Date	Complaints	Prescription
1	15/10/2018	 <p><b>Fig 1,2,3:</b> Hopelessness+, Despair+ Sleeplessness+, Right Toe ulcer with swelling++, Dirty look of affected part+, Discharge from ulcer- Sticky sero-sanguinous, Offensive smell+</p>	Merc Sol 30C 3pills OD for 15 days.
2	01/12/2018	 <p><b>Fig 4:</b> Sleep Improved, Appetite Improved, Ulcer healed No smell, No discharge, Skin Discoloration Dirty, Started Job of driving again</p>	Sac. Lac. 2 pills BID for 1 month
3	13/02/2019	Fair, No complaints	Sac. Lac 2pills BID for one month
4	09/03/2019	 <p><b>Fig 5:</b> Pressure sore on sole of Right foot with vesicle on nail of third right toe, Generals good</p>	Sulpur30 OD 3piils for three days Sac. Lac 2pills BID for 10 days
5	21/03/2019	 <p><b>Fig 6:</b> Sore healed, Generals good</p>	PL 2pills BID for one days
6	20/04/2019 to 09/06/2021	Fair, No complaints	PL 2pills BID
17	16/06/2021	Complaints recur, Toe wound ++, watery sticky discharge++, Offensiveness+, Generals Good	Merc Sol 30C 3pills OD for 10 days. Calendula Q lotion locally
18	02/07/2021	Ulcer healed No smell, No discharge, Skin Discoloration Dirty	PL 2pills per week for 16 weeks
20	04/01/2022	Fair, No complaints Generals good	PL 2pills per week for 6 weeks

## Discussion

This case of Leprosy determines changes in the peripheral nervous system and skin. Neural changes lead to ulceration. These chronic neuropathic ulcers have very peculiar characteristics such as circular edges, and erythematous surfaces. They occur in high-pressure areas such as feet.

After receiving both contemporary and homeopathic treatment, the ulcer in this leprosy patient resolved. However, the patient suffered a severe ulceration recurrence and a pervasive sense of hopelessness and despair despite receiving modern treatment for a year and a half. His career was impacted, but following three years of homeopathic treatment, there was a single, minor recurrence with a change in his mental condition. He resumed his work. The impact of homeopathy was demonstrated by the acceptance of the illness condition and the struggle to maintain it.

Several mental health disorders and negative emotional states were identified among leprosy patients and their family members. Depression and anxiety are particularly common, and a higher prevalence was found among leprosy-affected persons in comparison with healthy controls. Further research is necessary to identify the burden of the disease of leprosy, taking the mental health consequences into account, and the impact of leprosy on the mental wellbeing of family members. (Somar P, 2020) <sup>[8]</sup>.

Mental health of people affected by leprosy has not been studied much. There is no prevalence data, and the psychological burden of leprosy is unknown, along with factors contributing to it. Estimating and understanding this data is essential to plan interventions and resources to address it (Karthikeyan Govindasamy, 2021) <sup>[9]</sup>.

This case draws attention to the psychological impact of disease on a patient's behavior that cannot be abolished by modern treatment but homeopathic treatment modifies his mental state with positive coping to disease.

Referring to the homeopathic materia medica, Mercurius solubilis is not in the primary choices of drugs to leprosy. But this case brings our attention to Mercurius solubilis to know the depth of its pathogenesis. References we found to Mercurius solubilis are as

*A tendency to ulcerate* runs through the remedy. Ulcers are found everywhere, in the throat, nose, mouth, and on the lower limbs (materiamedica.info JT) <sup>[10-12]</sup>.

Every organ and tissue of the body is more or less affected by this powerful drug; it transforms healthy cells into decrepit, inflamed, and necrotic wrecks, and decomposes the blood, producing a profound anemia. This malignant medicinal force is converted into useful life saving and life preserving service if employed homeopathically.

Every degree and kind of inflammation and ulceration is produced by Merc and its salts. (materiamedica.info JH) <sup>[10-12]</sup>. This case also draws attention to clinical verification of Mercurius solubilis in management of leprosy though it cannot be frequently prescribed such type of clinical condition.

## Conclusion

The management of leprosy is possible with homeopathic medicine. Homeopathic therapy has the potential to treat leprosy. Conventional treatment was used to treat this instance of lepromatous leprosy at first, but following a relapse, customized homeopathic medicine was able to eliminate the skin lesions. In this leprosy patient, Mercurius Solubilis exhibits a favourable clinical result. Individualized

homeopathic medicine greatly reduces both the physical and psychological effects of illness. Hopefully, this case would increase interest in studying the use of homeopathic remedies for leprosy.

## Acknowledgments

We acknowledge the patient for giving faith and contributing to the clinical verification of Homoeopathy.

## Conflict of interest

The authors declare no conflicts of interest

## Financial Support

Not available

## References

1. World Health Organization. WHO website. [Online], 2022 [Cited 2022 Jan 29]. Available from: <https://www.who.int/news-room/fact-sheets/detail/leprosy>.
2. Centers for Disease Control and Prevention. CDC. [Online], 2017 [cited 2022 Jan 29]. Available from: <https://www.cdc.gov/leprosy/transmission/index.html>.
3. Hahnemann S. Organon of Medicine. 6th ed. Boericke W, Editor. IBPP, 2012.
4. Boericke GW. Boericke's New Manual of Homeopathic Materia Medica with Repertory. 3<sup>rd</sup> revised & augmented ed. B. Jain, editor. India: B. Jain Publishers (P) LTD, 2010.
5. Chakraborty D, Das U, PCT SJ. Therapeutic effect of Mercurius solubilis on immune status of a borderline leprosy case. IJRH. 2014 Jun 30;8(2):100-106.
6. Boericke W. Boericke's New Manual of Homoeopathic Materia Medica with Repertory. 3<sup>rd</sup> revised & augmented Ed. Jain, editor. San Francisco: B. Jain Publishers (P) LTD, 2007.
7. Clarke JH. A Dictionary of Practical Materia Medica. Vol II. Reprint Ed. Jain, editor. India: IBPP, 2017.
8. Somar P, van BW. The impact of leprosy on the mental wellbeing of leprosy-affected persons and their family members - a systematic review. Global Mental Health. 2020 Jun;7:e15.
9. Karthikeyan G, Govindasamy I. Burden of depression and anxiety among leprosy affected and associated factors: A cross-sectional study from India. PLoS Negl Trop Dis. 2021 Jan;15(1).
10. Materiamedica.info. Mercurius. [Online], [Cited 2022 Jan 31]. Available from: <https://www.materiamedica.info/en/materia-medica/james-tyler-kent/mercurius>.
11. Boericke W. Mercurius. [Online], [Cited 2022 Jan 31]. Available from: <http://www.homeoint.org/books/boericmm/m/merc.htm>
12. Materiamedica.info. Mercurius. [Online], [Cited 2022 Jan 31]. Available from: <https://www.materiamedica.info/en/materia-medica/john-henry-clarke/mercurius>.
13. Hahnemann S. Organon of Medicine. 6th ed. Boericke W, Editor. IBPP, 2012.
14. Somar P, van WM. The impact of leprosy on the mental wellbeing of leprosy-affected persons and their family members: A systematic review. Global Mental Health. 2020 Jun;7:e15.
15. Centers for Disease Control and Prevention. CDC.

- [Online]. 2017 [Cited 2022 Jan 29]. Available from:  
<https://www.cdc.gov/leprosy/transmission/index.html>.
16. World Health Organization. WHO website. [Online]. 2022 [Cited 2022 Jan 29]. Available from:  
<https://www.who.int/news-room/fact-sheets/detail/leprosy>.
17. Boericke W. Mercurius. [Online], [Cited 2022 Jan 31]. Available from:  
<http://www.homeoint.org/books/boericmm/m/merc.htm>
18. Boericke W. Boericke's New Manual of Homoeopathic Materia Medica with Repertory. 3rd revised & augmented ed. Jain, editor. San Francisco: B.Jain Publishers (P) LTD, 2007.

#### **How to Cite This Article**

Sawant SR, Mane AM, Ghevde VM, Nimankar PS, Shinde PS, Jogdande SM. Efficacy of homoeopathic management in trophic skin ulceration of leprosy: A case report. International Journal of Homoeopathic Sciences. 2025;9(1):190-194.

#### **Creative Commons (CC) License**

This is an open-access journal, and articles are distributed under the terms of the Creative Commons Attribution-Non Commercial-Share Alike 4.0 International (CC BY-NC-SA 4.0) License, which allows others to remix, tweak, and build upon the work non-commercially, as long as appropriate credit is given and the new creations are licensed under the identical terms.