



International Journal of Homoeopathic Sciences

E-ISSN: 2616-4493
P-ISSN: 2616-4485
www.homoeopathicjournal.com
IJHS 2020; 4(1): 124-130
Received: 01-11-2019
Accepted: 03-12-2019

Dr. Renu Bala
Research Officer (H)
Scientist-1 Regional Research
institute for Homoeopathy,
New Checkon, Opposite Tribal
Colony, Imphal, Manipur,
India

Dr. Amit Srivastava
Research Officer (H)/
Scientist-1 Regional Research
institute for Homoeopathy,
New Checkon, Opposite Tribal
Colony, Imphal, Manipur,
India

Dr. Rabina Chingakhm
Bhms, Senior Research Fellow
Regional Research Institute
For Homoeopathy,
New Checkon, Opposite Tribal
Colony, Imphal, Manipur,
India

Corresponding Author:
Dr. Renu Bala
Research Officer (H)/
Scientist-1 Regional Research
institute for Homoeopathy,
New Checkon, Opposite Tribal
Colony, Imphal, Manipur,
India

Importance of mental symptoms in homoeopathy: A case report on vitiligo

Dr. Renu Bala, Dr. Amit Srivastava and Dr. Rabina Chingakhm

Abstract

Vitiligo is an acquired immune condition, characterized by the destruction of epidermal melanocytes causing loss of pigmentation of the skin and can cause significant psychological stress and stigmatization. Unlike conventional method of treatment, Homeopathy considers local manifestations to be the outward expression of the inward and spiritual force, which when disturbed expresses itself in external signs and can only be treated by involving the person as a whole. This is a case report of a female patient with the complaint of white patches in the lateral border of right index finger and some spots on the dorsum of the right hand developed after a history of grief. Case with abundance of mental symptoms was repertorized and Homoeopathic medicine *Ignatia amara* in different potencies was prescribed based on Homoeopathic principles. The disappearance of white patches proved the efficacy of Homoeopathy and its principles in Local maladies.

Keywords: Vitiligo, Ignatia amara, mental generals, homoeopathy

1. Introduction

The word vitiligo is derived from the Greek word ‘vitelius’, meaning ‘calf’. The white spots of vitiligo resemble white patches on a calf [1]. Vitiligo is a common chronic skin depigmentation disorder. It is due to stoppage of melanin formation by the melanocytes and presents as asymptomatic depigmented macules anywhere on the body including mucous membranes of lips and genitalia. In vitiligo, there is a marked reduction or even absence of melanocytes and melanin in the epidermis. Histo-chemically, there is a lack of dihydroxyphenylalanine (DOPA) positive melanocytes in the basal layer of epidermis. The macules vary in size and shape as well as in colour. Some of the lesions or some parts of the lesions may be hypopigmented rather than depigmented. The course of the disease is very variable. The lesions in some patients may remain static or progress very slowly, whereas, in others, the disease progresses very fast and cover the whole body in few months. In few cases, spontaneous repigmentation has been noticed. It is usually perifollicular [2].

Vitiligo vulgaris/nonsegmental vitiligo is an acquired chronic depigmentation disorder characterized by white patches. These are often symmetrical and usually increase in size with time. This corresponds with a substantial loss of functioning epidermal and, sometimes, hair follicle melanocytes. Segmental vitiligo is a variant of vitiligo confined to one unilateral segment. One unique segment is involved in most patients but two or more segments on the same or opposite sides may be involved [3].

It affects around 0.5%–1% of the world population [4, 5]. As high as 8.8% prevalence have been reported in India [6].

Vitiligo has much psychosocial impact. Many studies show that there is a lot of social stigma, low self esteem, adjustment disorder, poor body image and low quality of life associated with vitiligo patients. Fifty percent of cases appear before the age of 20, with the disfigurement resulting in psychiatric morbidity in 16%–35% of those affected [7-16].

The proportion of patients with positive family history varies from one part of the world to another. In India, in particular, it ranges from 6.25% to 18%. Some studies reveal it as high as 40% [17].

The disease pathogenesis of vitiligo has not been fully elucidated. Autoimmune, biochemical and oxidative stress, genetic, neuronal and environmental factors are thought to interact and contribute to the development of vitiligo [16].

Various systems of medicine have claimed to have good results but not without side effects, like erythema, xerodermia, pruritus, acne form pustules and telangiectasia [18].

Patients frequently seek treatment of vitiligo from homoeopathic practitioners. The homoeopathic literature [2,19-21] suggested a number of medicines for the conditions

mentioned as 'vitiligo', 'leucoderma', 'hypopigmented spots.'

Relevant publications concerning Homoeopathic treatment of Vitiligo was searched in the electronic databases such as Research Gate [22], PubMed [23], IJRH [24] and AYUSH Research Portal [25]. The keywords used for the search were 'Vitiligo', and 'Homoeopathy'. In this search, 12 articles related to Homoeopathy on Vitiligo were identified in which four were clinical observational studies [26-29], three were case records [30-32] and one study each on review article [33], case series of fourteen cases [34], pilot data collection study [35], telephonic survey [36], and a double-blind, randomized, placebo-controlled homoeopathic pathogenetic trial [37] was found respectively.

Homoeopathy has given innumerable successful results in the treatment of Vitiligo when prescribed on the basis of totality of symptoms depicting individualization. The case presented here proves the importance of mental symptoms in homoeopathic prescription.

2. Case report

2.1 Patient information

A female patient of 50 years from middle class socio economic family came with the complaint of white patches on the lateral border of right index finger, small spots on dorsum of right thumb and some tiny spots on the dorsum of the right hand since 5 years.

2.2 History of presenting complaint

She was a mother of two daughters but she lost her younger daughter 5 years back when the child was only 8 years old. The child died due to accidental drowning. The white patches developed soon after beginning from lateral border of right index finger and later in dorsum of the right hand. After the incident, she also suffered from Post Traumatic Stress Disorder (PTSD) for which allopathic treatment was taken. After the treatment, she improved and regained to normal life. To avoid over thinking of her grief she tried occupying her mind by fetching fish using fish net every day.

2.3 Past History

She was diagnosed with Hypertension 5 years ago and is taking antihypertensive drugs. She has a history of Trans Abdominal Hysterectomy (TAH) with bilateral salphingo-oophorectomy 10 years back as a consequence of Uterine fibroid.

2.4 Family History: No significant maternal and paternal family history was found. Her husband also died 2 years back.

2.5 Homoeopathic Generalities

Mental generals: She was found to be very sensitive and emotional lady under the influence of grief. She still grieves for her lost child and was weeping while narrating her complaints.

2.6 Physical generals: No significant physical generals are found, thermally a hot patient.

2.7 Local Examination

Inspection

Site- Lateral border of right index finger, dorsum of right thumb, dorsum of the right hand

Shape: Linear with irregular borders on lateral border of right index finger, circular/oval on dorsum of right thumb and dorsum of the right hand

| | | |
|----------|---|-----------------|
| Symmetry | : | Non symmetrical |
| Border | : | Irregular |
| Colour | : | Hypopigmented |
| Crusting | : | Not present |

2.8 Clinical Diagnosis

Vitiligo

2.9 Differential Diagnosis [3]

The differential diagnosis has been given in Table 1

2.10 Analysis of the case

Detailed case taking revealed peculiar characteristic mental symptoms. Following characteristic mental general symptoms along with few physical general and particular symptoms were considered for totality of the case:

1. Sensitive
2. Weeping tendency
3. Bad effects of recent grief
4. Wants to be busy
5. Bad effects of death of children
6. Keeps thinking over her grief
7. Bad effects of mental shock
8. White spots on skin
9. Hot patient

2.11 Repertorial Analysis

After totality of symptoms was formed, repertorization was done by Synthesis repertory using RADAR software [38]. Conversion of symptoms into rubrics has been given in Table 2. Repertorization chart is represented in Figure 1.

2.12 Therapeutic intervention

After analyzing repertorial totality, it was observed that Ignatia amara covered all the rubrics with maximum score (9/16). However, Sulphur (7/14), Natrum muriaticum (7/13) and Calcarea carb (6/11) were the next medicines in hierarchy. On consulting the materia medica [39], Ignatia amara seems to be the nearest similimum of the case. It was prescribed in 200C potency, three doses on the baseline visit. A single dose consisted of four globules of size forty of the indicated medicine. Each dose to be taken in the morning on empty stomach for three days.

2.13 Follow up

The follow up with assessment of Measure Yourself Medical Outcome Profile 2 (MYMOP2) [40] and Outcome Related to Impact in Daily Living (ORIDL) [41] are given in Table 3. The image of the case at baseline and after treatment are given in Figure 2 and Figure 3 respectively.

3. Discussion

Vitiligo is considered to be difficult and takes long duration to treat. Unlike conventional method of treatment, Homoeopathy condemns the local application and considers it to be most pernicious. All external maladies arise and grow worse with the involvement and participation of the entire organism. It is the person who is ill before the appearance of the manifestation on skin. Hence the treatment must be directed to the totality which comprises of the characteristics of local malady in conjunction with all

the changes and symptoms of the rest of the patient's economy. As local malady depends exclusively on the disease of rest of the organism, so local diseases must be regarded as an inseparable part of the whole disease^[42].

After taking the case according to the guidelines laid down in the Organon, all the mental symptoms and all conditions predicated of the patient himself were evaluated followed by repertorization. The symptom picture was examined collectively, comparatively and individually, and lastly study of the Materia Medica of such remedies as run through the symptoms of the case was made until there was no doubt about which was the most similar of all remedies.

The method of working out a case from generals to particulars is the most satisfactory. If a case is worked out merely from particulars it is more than probable that the remedy will not be seen, and frequent failure will be the result^[43].

Among the general symptoms (i.e. those symptoms pertaining to the whole person), the mental/emotional symptoms rank higher than the physical generals. Hahnemann and Kent recognized over 100 years ago the high place they take in our hierarchy of symptoms^[44].

The case had peculiar mental generals which formed the totality of the case with very few particulars. The mental state, reflecting the inner core of the being is of the utmost importance. Illness starts first on the mental plane and then the physical changes appear^[44]. The patches of Vitiligo appeared soon after the death of the child. This mental trauma and grief had affected the patient on the mental plane to the greatest extent as a result of which the patches developed. This is where the importance of 'Never well since' is established. This symptom is available in the Repertory with the rubric "ailments from" with suitable sub rubrics. The keynote symptom of 'bad effect of grief' represented in rubric 'ailment grief from, recent' with single remedy, Ignatia amara, could have been the basis of prescribing the remedy. But Hahnemann condemns prescribing on one symptom only as an allopathic way of practicing homoeopathy, "The single symptom is no more the disease, than a single foot is the man himself." Dr. Guernsey, the so-called "father of the keynote system", explicitly states that keynotes should not form the sole basis of a prescription, but all keynotes must be in harmony with and confirmed by the totality of the accompanying symptoms"^[44].

The general rubric included all the remedies that were related to the symptom, and after this the particulars were gone into and the remedy which runs through the general rubrics was found to have the particular symptoms, thus aided in its choice as the one to be prescribed^[43]. The remedy Ignatia amara in this case was reflected in all the mental general rubrics and also runs through the particulars of the case.

The rubric "ailments from-grief, recent" indicating single remedy was taken along with other peculiar mental symptoms. The remedy was confirmed by covering the totality of the case as a whole. Further, careful consideration and comparison of all the symptoms of Ignatia amara with Materia medica was made which is as below:

As per H.C.Allen, "Especially suited to nervous temperament; women of a sensitive, easily excited nature; dark hair. Bad effects of anger, grief, or disappointed love. Broods in solitude over imaginary trouble. Ill effects, from bad news"^[45].

J.T. Kent wrote, "A woman loses her child or her husband. A sensitive, delicate woman and she suffers from this grief. In spite of her best endeavors, her grief has simply torn her to pieces. She is unable to control her emotions and her excitement. Great grief after losing persons or objects very near"^[39].

According to Lippe, "Bad effects from fright and sorrow"^[46].

Thus Ignatia amara seemed to be the most indicated among all the remedies in hierarchy and was prescribed in a high potency (200 C). But even after repetition of the remedy there was no visible change. So the potency was further increased to 1M. After one month, patient returned with a normal skin colour over the lateral border of right index finger, dorsum of right thumb and dorsum of right hand. The methods used to assess the changes in the patches were based on visual assessments and analysis of photographs taken before and after treatment under visible light.

Overall well being of the patient was also improved gradually as assessed by MYMOP 2 and ORIDL score. The MYMOP2 questionnaire at baseline defines symptom of white patch on the lateral border of right index finger as the most bothersome (Symptom 1). Symptom 1 showed diminution from 6 (as bad as it could be) to 0 (as good as it could be) in the follow up. The MYMOP2 subscale of activity measures the work which the complaint prevents or makes it difficult to do. Patient recorded it to be mental activity which decreased from 6 (as bad as it could be) to 0. The wellbeing subscale improved on a likert scale from 6 to 1. The MYMOP2 Profile Score showed a significant change from a baseline score of 6 to 0.3 depicting significant improvement in all the domains.

Assessment of response to the previous prescription on main complaint as well as on overall well being was made through 'The Outcome in Relation to Impact on Daily Living (ORIDL)' instrument in which for main complaint patient showed no change (0) during follow up 1 and 2 but was finally cured/back to normal (+4) in follow up 4. For overall well being, patient showed no change (0) in first follow up, proceeding to slight improvement (+1), moderate improvement (+2) and finally to major improvement (+3) during follow ups.

The final outcome and possible causal attribution of the changes in this case were assessed using the Modified Naranjo Criteria as proposed by HPUS Clinical data Working Group (December 2015)^[47]. The total score of outcome in this case was nine which was close to the maximum score of 13 as per Modified Naranjo Criteria. [Table 4]

Homoeopathy recognizes the importance of mental trauma and its manifestations on physical plane. This case report clearly brings forward the supreme importance of mental symptoms in Homoeopathy. It is one of the homoeopathy's strengths that it can prescribe on the slightest emotional or mental factors, forestalling the development of subsequent pathology^[44].

Table 1: Differential Diagnosis of Vitiligo

| Halo naevus | Hypopigmented naevus | Naevus of Ito |
|---|--|---|
| Leprosy | Piebaldism | Pityriasis alba |
| Melanoma-associated leucoderma | Topical or drug-induced depigmentation | Naevus anaemicus |
| Mycosis fungoides-associated depigmentation | Post inflammatory depigmentation, e.g. scleroderma, psoriasis, atopic eczema | Lichen sclerosus (for genital vitiligo) |
| Melasma | Pityriasis versicolor | Pityriasis versicolor |
| Tuberous sclerosis | Idiopathic guttate hypomelanosis | |

Table 2: Conversion of symptoms into rubrics

| Symptoms | Rubrics |
|----------------------------------|--|
| Sensitive | Mind- Sensitive |
| Weeping tendency | Mind- Weeping |
| Bad effects of recent grief | Mind- Ailments from-grief, recent |
| Wants to be busy | Mind- Busy, fruitlessly |
| Bad effects of death of children | Mind- Ailments from-death of loved ones, children of |
| Keeps thinking over her grief | Mind- Brooding, grief over |
| Bad effects of mental shock | Mind- Ailments from- mental shocks, from |
| White spots on skin | Skin- Discoloration- white spots |
| Hot patient | Generals- Warm agg |

Table 3: Follow up with assessment of Measure Yourself Medical Outcome Profile 2 (MYMOP2) and Outcome Related to Impact in Daily Living (ORIDL)

| | Baseline (08.08.16) | Follow up 1 (12.09.16) | Follow up 2 (17.10.16) | Follow up 3 (21.11.16) | Follow up 4 (28.12.16) |
|---|---|---|---|--|--|
| Right Index Finger | White patch on the lateral border of right index finger | Same as before | Same as before | Same as before | No white patch seen over lateral border of right index finger. |
| Right Thumb | Small spots on dorsum of right thumb | Same as before | Same as before | Same as before | Small spots on dorsum of right thumb also disappeared |
| Right Hand | Tiny spots on the dorsum of the right hand | Same as before | Same as before | Same as before | No spots on the dorsum of the right hand visible |
| MYMOP Symptom 1- White patch on the lateral border of right index finger | 6 | 6 | 6 | 6 | 0 |
| Activity- Mental | 6 | 6 | 6 | 6 | 0 |
| General feeling of well being | 6 | 5 | 4 | 2 | 1 |
| MYMOP profile score | 6 | 5.6 | 5.3 | 4.6 | 0.3 |
| ORIDL score Main complaint | | 0 | 0 | 0 | 4 |
| Overall well being | | 0 | +1 | +2 | +3 |
| Treatment | Ignatia 200/3 doses, 1 dose daily morning for 3 days, followed by Placebo for 1 month | Ignatia 200/ 3 doses,1 dose daily morning for 3 days, followed by Placebo for 1 month | Ignatia 200/ 3 doses,1 dose daily morning for 3 days, followed by Placebo for 1 month | Ignatia 1M/ 3 doses,1 dose daily morning for 3 days, followed by Placebo for 1 month | Placebo for 1 month |

Table 4: Assessment of outcome with Modified Naranjo Algorithm

| Modified Naranjo algorithm | Yes | No | Not sure or N/A |
|---|-----|----|-----------------|
| 1. Was there an improvement in the main symptom or condition for which the homoeopathic medicine was prescribed? | +2 | | |
| 2. Did the clinical improvement occur within a plausible timeframe relative to the medicine intake? | +1 | | |
| 3. Was there an initial aggravation of symptoms? | | 0 | |
| 4. Did the effect encompass more than the main symptom or condition (i.e., were other symptoms ultimately improved or changed)? | +1 | | |
| 5. Did overall wellbeing improve (suggest using validated scale)? | +1 | | |
| 6 (a). Direction of cure: did some symptoms improve in the opposite order of the development of symptoms of the disease? | | | 0 |
| 6 (b). Direction of cure: did at least two of the following aspects apply to the order of improvement of symptoms: | | | 0 |

| | | | |
|--|----|----|----|
| From organs of more importance to those of less importance, deeper to more superficial aspects of the individual, From the top downwards | | | |
| 7. Did 'old symptoms' (defined as non seasonal and non cyclical symptoms that were previously thought to have resolved) reappear temporarily during the course of improvement? | | 0 | |
| 8. Are there alternative causes (other than the medicine) that with a high probability could have caused the improvement? (consider known course of disease, other forms of treatment and other clinically relevant interventions) | | +1 | |
| 9. Was the health improvement confirmed by any objective evidence? (e.g. lab test, clinical observation, etc.) | +2 | | |
| 10. Did repeat dosing, if conducted, create similar clinical improvement? | +1 | | |
| Total score: | | | +9 |

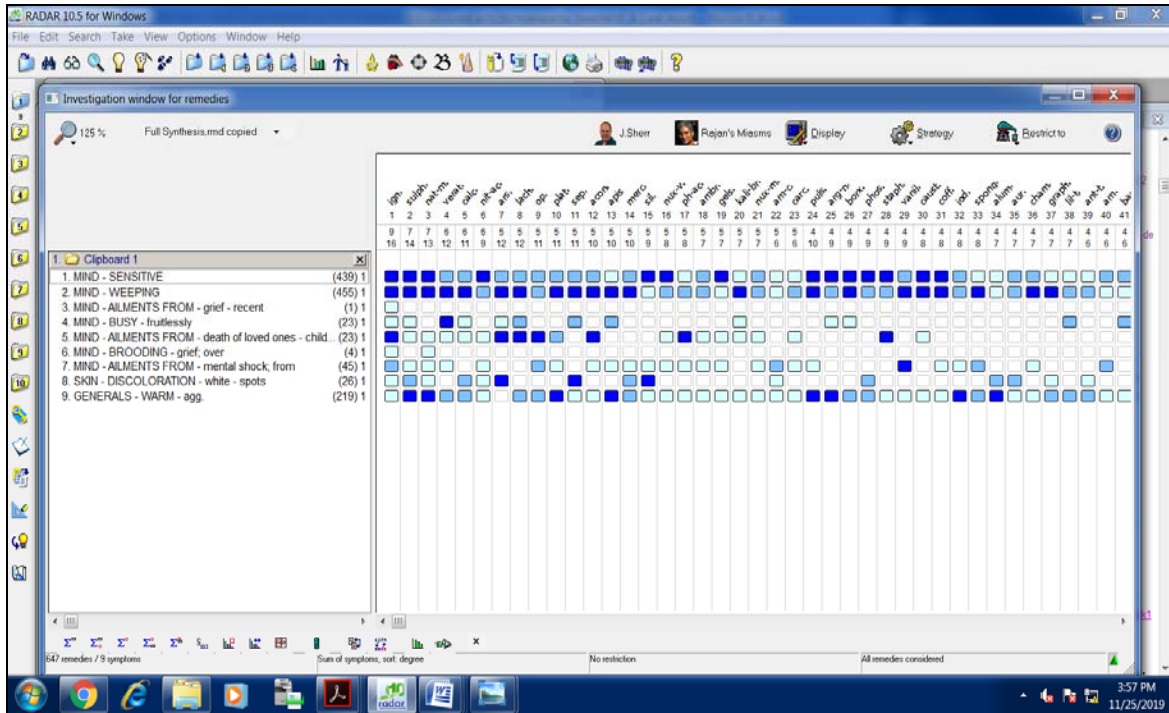


Fig 1: Repertorization chart

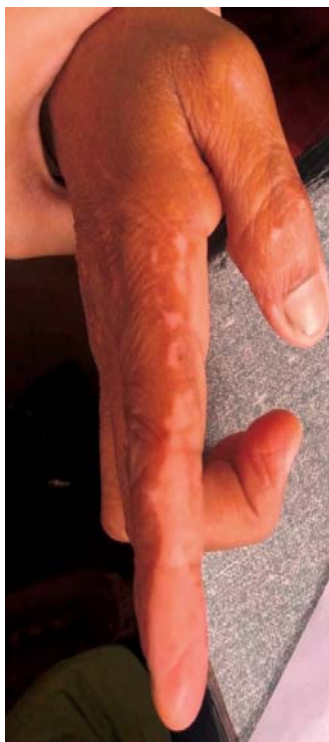

Fig 2: Image of the patient at baseline (08.08.16)

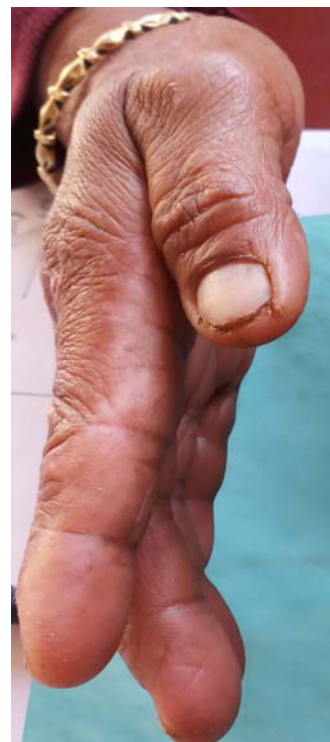

Fig 3: Image of the patient after treatment (28.12.16)

4. Conclusion

Natural course of Vitiligo include flares and remissions due to which its treatment is acknowledged as being difficult. It is essential to know the initial extent and severity of Vitiligo for making prognosis and therapeutic choices which is fundamental to the evaluation of treatment efficacy. In this case, the holistic approach of Homoeopathic treatment cured the condition of Vitiligo along with improvement in her overall general well being. The case re-establishes the importance of mental generals in Homoeopathy which reflect the inner core of the individual. Many Studies have identified a positive role of Homoeopathy in Vitiligo where treatment was based on homoeopathic principles of totality. The result which we get from this case shows that Homoeopathy treatment has an ultimate scope towards the treatment of Vitiligo. Many evidence based studies are required to establish a scientific base of Homoeopathy in treatment of Vitiligo.

5. References

- Kaur S, Singh HP, Dhir K. A review on Leucoderma. *Res J Pharm, Biol Chem Sci.* 2013; 4(4):700-07.
- Gupta R, Manchanda RK. Disorders of Pigmentation In *Textbook of Dermatology for Homeopaths.* 3rd ed. B. Jain Publisher, New Delhi. 2009, 140-44.
- Gawkrodger DJ, Ormerod AD, Shaw L, Mauri-Sole I, Whitton ME, Watts MJ *et al.* Guideline for the diagnosis and management of Vitiligo. *Br J Dermatol.* 2008; 159(5):1051-76.
- Eleftheriadou V, Thomas KS, Whitton ME, Batchelor JM, Ravenscroft JC. Which outcomes should we measure in vitiligo? Results of a systemic review and a survey among patients and clinicians on outcomes in vitiligo trials. *Br J Dermatol.* 2012; 167(4):804-14.
- Ezzedine K, Eleftheriadou V, Whitton M, van Geel N. Vitiligo. *Lancet.* 2015; 386(9988):74-84.
- Whitton ME, Pinart M, Batchelor J, Leonardi Bee J, González U, Jiyad Z *et al.* Interventions for vitiligo. *Cochrane Database of Systematic Reviews* 2015, Issue 2. Art. No.: CD003263. [Cited 2019 Nov 12] Available from: <https://www.cochranelibrary.com/cdsr/doi/10.1002/14651858.CD003263.pub5/full#>
- Porter JR, Beuf AH, Lerner A, Nordlund J. Psychosocial effect of vitiligo: a comparison of vitiligo patients with “normal” control subjects, with psoriasis patients, and with patients with other pigmentary disorders. *J Am Acad Dermatol.* 1986; 15(2Pt 1):220-4.
- Mattoo SK, Handa S, Kaur I, Gupta N, Malhotra R. Psychiatric morbidity in vitiligo: prevalence and correlates in India. *J Eur Acad Dermatol Venereol.* 2002; 16(6):573-8.
- Parsad D, Dogra S, Kanwar AJ. Quality of life in patients with Vitiligo. *Health Qual Life Outcomes.* 2003; 1:58
- Parsad D, Pandhi R, Dogra S, Kanwar AJ, Kumar B. Dermatology Life Quality Index score in Vitiligo and its impact on the treatment outcome. *Br J Dermatol.* 2003; 148(2):373-4.
- Firooz A, Bouzari N, Fallah N, Ghazisaidi B, Firoozabadi MR, Dowlati Y. What patients with vitiligo believe about their condition. *Int J Dermatol.* 2004; 43(11):811-814.
- Ongenae K, Van Geel N, De Schepper S, Naeyaert JM. Effect of vitiligo on self-reported health-related quality of life. *Br J Dermatol.* 2005; 152(6):1165-72.
- Ongenae K, Beelaert L, van Geel N, Naeyaert JM. Psychological effects of Vitiligo. *J Eur Acad Dermatol Venereol.* 2006; 20(1):1-8.
- Schmid-Ott G, Künsebeck HW, Jecht E, Shimshoni R, Lazaroff I, Schallmayer S *et al.* Stigmatization experience, coping and sense of coherence in vitiligo patients. *J Eur Acad Dermatol Venereol.* 2007; 21(4):456-61.
- Manoolache L, Benea V. Stress in patients with alopecia and vitiligo. *J Eur Acad Dermatol Venereol.* 2007; 21(7):921-928.
- Szczurko O, Shear N, Taddio A, Boon H. Ginkgo biloba for the treatment of vitiligo vulgaris: An open label pilot clinical trial. *BMC Complement Altern Med* 2011; 11:21.
- Sehgal VN, Srivastava G. Vitiligo: Compendium of clinico-epidemiological features. *India J Dermatol Venereol Leprol* 2007; 73:149-56.
- Forschner T, Buchholtz S, Stockfleth E. Current state of vitiligo therapy— evidence-based analysis of the literature. *J German Soc Dermatol.* 2007; 5(6):467:475.
- Douglass MF. *Skin Diseases- Their Description, Etiology, Diagnosis And Treatment According To The Law Of The Similars.* B Jain Publishers (P) Ltd. New Delhi. 1899, 379-82.
- Lilienthals S. *A Treatise on Diseases of the Skin:* B. Jain Publishers (P) Ltd, New Delhi, India. 2002, 113-7.
- Boericke W. *Boericke’s New Manual of Homeopathic Materia Medica with Repertory.* 3rd Revised and Augmented ed. Based on 9th ed. B. Jain Publishers (P) Ltd, New Delhi, India. 2010, 302.
- ResearchGate [Internet]. Berlin: 2008- [cited 2019 November 12] Available from: <https://www.researchgate.net/>
- Pubmed [Internet]. Bethesda: US National Library of Medicine, National Institutes of Health 1988- [cited 2019 November 12]. Available from: <https://www.ncbi.nlm.nih.gov/pubmed/>
- Indian Journal of Research in Homoeopathy [Internet]. New Delhi: Central Council for Research in Homoeopathy, Ministry of Ayush, Govt of India; 2019- [cited 2019 November 12]. Available from: <http://www.ijrh.org/>
- Ayush Research Portal [Internet]. India: Ministry Of Ayush, Govt. Of India; 2011- [cited 2019 November 12]. Available from: <http://ayushportal.nic.in/>
- Chakraborty PS, Kaushik S, Debata L, Ram B, Kumar R, Shah M *et al.* A multicentric observational study to evaluate the role of homoeopathic therapy in vitiligo. *Indian J Res Homoeopathy.* 2015; 9:167-75.
- Ganguly S, Saha S, Koley M, Mondal R. Homeopathic treatment of vitiligo: An open observational pilot study. *Int J High Dilution Res.* 2013; 12:168-77.
- Samanta B. Clinical study on vitiligo and its homoeopathic treatment: Research (Phase- I) report (For the year 2002-2005). *Bull Natl Inst Homoeopathy* 2010; 13(4).
- Prasad RV, Raveender CH, Lakshmi B, Singh K, Vichitra AK, Oberai P *et al.* Clinical Evaluation of Predefined Homoeopathic Medicine in Vitiligo. *Clinical Research Studies Series– II, Central Council for Research in Homoeopathy, New Delhi (India);*

- 2009, 85-92. [cited 2019 November 12]. Available from:
<https://www.ccrhindia.nic.in//admnis/admin/showimg.aspx?ID=13103>.
30. Jha DK, Debata L. A case of vitiligo treated by Sulphur. *Indian J Res Homoeopathy* 2009; 3(3):34-40.
 31. Kumar SR. A case of vitiligo treated with phosphorus. *Indian J Res Homoeopathy* 2008; 2(1):49-57.
 32. Behera M. Homoeopathy and Vitiligo – A Case Report, *Hopathy Ezine*; April, 2016- [cited 2019 November 12]. Available from: <https://hopathy.com/clinical-cases/homoeopathy-and-vitiligo-a-case-report/>.
 33. Dewan D, Taneja D, Singh U, Mittal R, Khurana A. Homoeopathic research in vitiligo: Current scenario. *Indian J Res Homoeopathy* 2017; 11(4):226-36.
 34. Mahesh S, Mallappa M, Tsintzas D, Vithoulkas G. Homoeopathic Treatment of Vitiligo: A Report of Fourteen Cases. *Am J Case Rep.* 2017; 18:1276-1283.
 35. Thompson EA, Mathie RT, Baitson ES, Barron SJ, Berkovitz SR, Brands M, *et al.* Towards standard setting for patient-reported outcomes in the NHS homeopathic hospitals. *Homeopathy* 2008; 97(3):114-21.
 36. Endrizzi C, Rossi EG. Patient compliance with homeopathic therapy. *Homeopathy* 2006; 95(4):206-14.
 37. Shah R. Hydroquinone: Homoeopathic pathogenetic trial. *Indian J Res Homoeopathy* 2013; 7(2):47-61.
 38. RADAR 10. Archibel Homoeopathic Software. Belgium, 2009.
 39. Kent JT. Lectures on Homoeopathic materia medica. Second rearranged Edition. B Jain Publishers (P) Ltd., New Delhi. 2009, 592-593.
 40. Paterson C, Britten N. In pursuit of patient-centred outcomes: a qualitative evaluation of the "Measure Yourself Medical Outcome Profile." *J Health Serv Res Pol* 2000; 5(1):27-36.
 41. Reilly D, Mercer Stewart W, Bikker Annemieke P, Harrison Tansy. Outcome related to impact on daily living: preliminary validation of the ORIDL instrument. *BMC Health Serv Res.* 2007; 7:139.
 42. Hahnemann S. *Organon of Medicine*. Reprint ed. Translated from 6th edition by William Boericke. B. Jain Publishers, New Delhi, India. 1996, 83-84.
 43. Kent JT. *Repertory of the Homoeopathic materia medica*. Examiner printing house, Philadelphia. 1897. p. 3-4.
 44. Schepper, Luc De. *Hahnemann Revisited*. Full of Life Publications, Santa Fe. 2001, 473- 480.
 45. Allen HC. *Keynotes and characteristics with comparisons*. 8th ed. B Jain Publishers (P) Ltd. New Delhi. 2013, 156-158.
 46. Lippe, Adolph von. *Keynotes of Homoeopathic Materia Medica*. B Jain Publishers (P) Ltd. New Delhi. pp. 57.
 47. Van Haselen RA. Development of a supplement (HOM□CASE) to the CARE clinical case reporting guideline. *Complement Ther Med.* 2016; 25:78□85.