



International Journal of Homoeopathic Sciences

E-ISSN: 2616-4493
P-ISSN: 2616-4485
www.homoeopathicjournal.com
IJHS 2025; 9(1): 402-404
Received: 25-10-2024
Accepted: 30-11-2024

Dr. AK Dwivedi
Professor and HOD,
Department of Physiology and
Biochemistry, SKRP Gujrati
Medical College, Indore,
Madhya Pradesh, India

Homeopathic management of fistula: Observational study

AK Dwivedi

DOI: <https://doi.org/10.33545/26164485.2025.v9.i1.F.1383>

Abstract

An anal fistula is a passageway which develops in between the skin near the anus and end of intestine. It is triggered by infection in between the skin near the anus and end of intestine. Pus-like liquid which is sticky in nature gets accumulated in the area and makes life very pain full. It has been reported that all around the world 8.3% individuals are affected by fistula. In India it has been reported that around 1.4% individuals has suffered from fistula. In this paper we have presented an case study in which fistula has been cured using Homeopathic treatment.

Keywords: Anal track, fistula, bowel, homeopathic treatment, infection etc

Introduction

A fistula is an unusual union encompassing two body parts, it can be an organ or blood vessel and another structure. Anal fistula is typically a side effect of anal inflammation, an contaminated injury that trenches pus from your anus. This condition is more common in men than in women ^[1].

An anal fistula appears as a hole in the skin adjacent to anus. The hole is in fact the farthest segment of the passageway, which links to the swelling inside. It may discharge pus, blood or poop, specifically the minute you tap the skin around it. This leads to the discomfort and swelling till the fistula wind down to let out the drainage ^[2].

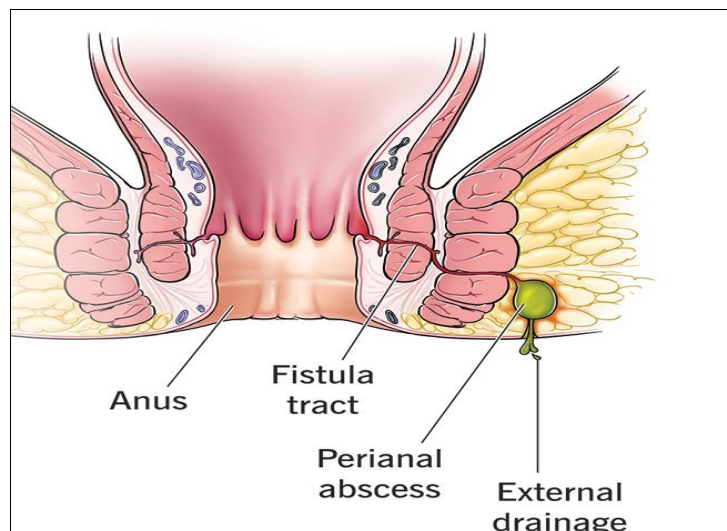


Fig 1: Image of Anal Fistula

Symptoms of Fistula ^[3]

- Anal inflammation when you sit, cough or poop
- Tenderness or bulge at your anus.
- Pus or Blood coming from your anus.
- Fever
- Trouble managing bowel movements

Corresponding Author:
Dr. AK Dwivedi
Professor and HOD,
Department of Physiology and
Biochemistry, SKRP Gujrati
Medical College, Indore,
Madhya Pradesh, India

Risk involve for the person suffering from Anal Fistula

[4]

- Crohn's disease
- Distress to the anal area
- Infections of the anal area

Diagnosis of Fistula [5]

- Physical Examination
- MRI Fistulogram
- Flexible sigmoidoscopy or colonoscopy
- Endoscopic ultrasound

Homeopathic management of Fistula

Homeopathy is a reliable, accepted, and non-aggressive form of therapy which can be an efficient method to cure fistulas with no need for surgery.

Case Study

In this paper we have discussed an case study of an 67 years old male patient suffering from anal fistula who was treated at our Advanced Homeo Health Centre, Indore, Madhya Pradesh.

- **Patients Age:** 67 years
- **Patient Sex:** Male.

Patient MRI findings before treatment

There is abnormal fistulous tract is seen with an internal opening seen at approximately 6 O'clock position of the upper anal canal with inferior extension along the posterior wall of the anal canal in the inter and trans sphincteric planes with external cutaneous opening at 6 O'clock position of the anal canal, approx. 6-7 mms away from the anal verge. Length of the tract measures about 5.4 cms.

Abnormal fistulous tract is seen with an internal opening seen at approximately 6 O'clock position of the upper anal canal with inferior extension along the posterior wall of the anal canal in the inter and trans sphincteric planes with external cutaneous opening at 6 O'clock position of the anal canal, approx. 6-7 mms away from the anal verge. Length of the tract measures about 5.4 cms. No extension superior to the levatorani is seen. No extension in the ischiorectal fossa

is seen. Findings are suggestive of perianal fistula.

Patient MRI findings After three month of treatment

There is abnormal fistulous tract is seen with an internal opening seen at approximately 6 O'clock position of the upper anal canal with inferior extension along the posterior wall of the anal canal in the inter sphincteric plane and length of the tract measures about 3.2 cm. No obvious external opening of the tract is seen. No significant post contrast enhancement or fluid is seen within the tract.

Abnormal fistulous tract is seen with an internal opening seen at approximately 6 O'clock position of the upper anal canal with inferior extension along the posterior wall of the anal canal in the inter sphincteric plane and length of the tract measures about 3.2 cm. No obvious external opening of the tract is seen. No significant post contrast enhancement or fluid is seen within the tract suggestive of healing stage of the perianal fistula.

MRI findings After Six Month of Treatment

Small abnormal fistulous tract is seen with an internal opening at approximately 6 O'clock position of the upper anal canal. It is extending postero-inferiorly along the posterior wall of the anal canal in the inter sphincteric plane and length of the tract measures about 1.5 cm.

No obvious external opening of the tract is seen. No significant post contrast enhancement or fluid is seen within the tract. No extension superior to the levator ani is seen. No extension in the ischiorectal fossa is seen.

MRI Findings after Nine Month of Treatment

No obvious residual or recurrent perianal fistula is seen on present study. Bilateral ischio-rectal fossae appear normal. Anal canal and rectum appears normal. Moderate prostatomegaly is seen measuring about 6.2 x 4.7 x 6.0 cm in size. The central zone appears enlarged and reveals inhomogeneous signal intensity with heterogeneous post contrast enhancement. Peripheral zone appears normal. Periprostatic structure appears normal.

No obvious residual or recurrent perianal fistula is seen on present study

Table 1: Medicines Prescribed

Sr. No.	Name of Medicine	Role
1	Hepar Sulph	Inflammation and promoting healing.
2	Calcarea Sulph	Yellow, purulent discharge.
3	Silicea	Chronic anal fistula and recurrent abscess formation.
4	Myristica	Deep-seated pain and abscess with Pus formation.

Recommendation

- Sits bath daily
- Avoid Non veg & Spicy food

Conclusion

From this observational research conducted we have gathered the sufficient evidence that the Homoeopathic medicine shows excellent results in the treatment of Fistula, The results suggest that homeopathic treatment is an effective and safe method in the treatment of Fistula. Without any recurrence.

Biography:

Dr. A. K. Dwivedi, BHMS (Gold Medallist), MD, MBA,

Ph.D. is an Registered Homeopath for over 25 years. He is Professor & HOD: Department of Physiology S.K.R.P. Gujarati Homoeopathic Medical College, Indore. He is a Member of Executive Council, Devi Ahilya Vishwavidyalaya Indore, MP, INDIA, He is Member Scientific Advisory Board (CCRH) Ministry of Ayush, Govt of India. Member Academic Board Madhya Pradesh Medical Science University, Jabalpur MP (India). DIRECTOR, & CEO Advanced Homeo Health Center & Homeopathic Medical Research Pvt.Ltd. Indore, Madhya Pradesh, India, EDITOR, "SEHAT EVAM SURAT" (Hindi Monthly Medical Magazine).

Conflict of Interest: Not available.

Financial Support: Not available.

References

1. De Prisco G, Celinski S, Spak CW. Abdominal abscesses and gastrointestinal fistulas. In: Feldman M, Friedman LS, Brandt LJ, eds. Sleisenger & Fordtran's Gastrointestinal and Liver Disease. 11th ed. Philadelphia, PA: Elsevier; c2021. p. chap 29.
2. Lentz GM, Fialkow M. Anal incontinence: diagnosis and management. In: Gershenson DM, Lentz GM, Valea FA, Lobo RA, eds. Comprehensive Gynecology. 8th ed. Philadelphia, PA: Elsevier; c2022. p. chap 22.
3. Harrison's Principles of Internal Medicine. 17th ed.
4. American Society of Colon & Rectal Surgeons. Abscess and Fistula Expanded Information.
5. Malik AI, Nelson RL. Surgical management of anal fistulae: A systematic review. *Colorectal Dis.* 2008;10:420-30.
6. Davidson's Principles & Practice of Medicine.
7. Kent JT. Repertory of Homoeopathic Materia Medica.
8. Dubey SK. Textbook of Materia Medica.
9. Choudhari NM. A study on Materia Medica.
10. Boericke W. Pocket Manual of Homoeopathic Materia Medica & Repertory.
11. Allen HC. Keynotes & Characteristics with Comparisons of Some Leading Remedies of the Materia Medica with Bowel Nosodes. 8th ed.
12. Uniyal P, Kinra R. Materia Medica for Students.

How to Cite This Article

Dwivedi AK. Homeopathic management of fistula: Observational study. *International Journal of Homoeopathic Sciences.* 2025;9(1):402-404.

Creative Commons (CC) License

This is an open access journal, and articles are distributed under the terms of the Creative Commons Attribution-NonCommercial-ShareAlike 4.0 International (CC BY-NC-SA 4.0) License, which allows others to remix, tweak, and build upon the work non-commercially, as long as appropriate credit is given and the new creations are licensed under the identical terms.