



# International Journal of Homoeopathic Sciences

E-ISSN: 2616-4493  
P-ISSN: 2616-4485  
[www.homoeopathicjournal.com](http://www.homoeopathicjournal.com)  
IJHS 2025; 9(2): 166-171  
Received: 17-02-2025  
Accepted: 18-03-2025

**Dr. Savari S. Volvoikar**  
PG Scholar, MD Part 1,  
Department of Case Taking  
and Repertory, Bharatesh  
Homoeopathic Medical College  
and Hospital, Belagavi,  
Karnataka, India

**Dr. Geeta B. Adi**  
Associate Professor and PG  
Guide, Department of Case  
Taking and Repertory,  
Bharatesh Homoeopathic  
Medical College and Hospital,  
Belagavi, Karnataka, India

**Corresponding Author:**  
**Dr. Savari S. Volvoikar**  
PG Scholar, MD Part 1,  
Department of Case Taking  
and Repertory, Bharatesh  
Homoeopathic Medical College  
and Hospital, Belagavi,  
Karnataka, India

## A case of viral pneumonia treated with homoeopathic medicine: A case report

**Savari S. Volvoikar and Geeta B. Adi**

**DOI:** <https://www.doi.org/10.33545/26164485.2025.v9.i2.C.1493>

### Abstract

Various viruses can cause lower respiratory tract infection. Viral pneumonia in adult are classified into two clinical groups. This case report presents a 47-year-old male diagnosed with viral pneumonia, exhibiting symptoms such as fever, breathlessness, dry cough, and stitching pain in the left hypochondriac region. The patient was treated with individualized homoeopathic remedies based on the totality of symptoms. Bryonia 200C was initially prescribed, followed by Sulphur 200C.

**Result:** Improvement was seen, with resolution of respiratory symptoms and normal clinical, physical examination findings. This case highlights the potential of homoeopathic medicine as an effective therapeutic modality in managing viral pneumonia when appropriately applied.

**Keywords:** Viral pneumonia, bryonia, sulphur, synthesis repertory, crepitations

### Introduction

Pneumonia is defined as acute infection of the lung parenchyma excluding the terminal bronchioles, by one or more co-pathogens. The term 'pneumonia' and 'pneumonitis' are often used synonymously for inflammation of the lungs, while consolidation is the term used for gross and radiologic appearance of the lungs in pneumonia<sup>[2]</sup>.

### Etiological classification

- Bacterial
- Viral
- Mycoplasmal
- Fungal
- Non infectious
- here are four stages of pneumonia
- Stages of congestion (Initial phase- 1-2 days)
- Stages of red hepatization (Early consolidation- 2-4 days)
- Stages of grey hepatization (Late consolidation- 4-8 days)
- Stages of resolution (1-3 weeks)

The microorganisms gain entry into the lungs by one of the four routes i.e. Inhalation, Aspiration, Haematogenous spread, Direct spread<sup>[2]</sup>.

Viruses of the psittacosis group, respiratory syncytial viruses and others may produce pneumonia. Various viruses which can cause lower respiratory tract infection in adults are as follows, influenza virus, hantavirus, measles virus, adenovirus, herpes virus, cytomegalo virus, varicella -zoster virus and Epstein-Barr virus. Viral pneumonia in adults can be classified into two clinical groups<sup>[1]</sup>.

1. Atypical pneumonia -in otherwise healthy host
2. Viral pneumonia in immunocompromised host<sup>[1]</sup>

### Complications<sup>[2]</sup>

1. Bacteremia
2. Lung abscess
3. Pleural effusion
4. Difficulty breathing
5. Shock and respiratory failure
6. Septic arthritis
7. Endocarditis<sup>[2]</sup>

Dr. Routh's statistics of the comparative mortality in pneumonia under homoeopathic treatment cases treated 783 among those died 45 so the mortality rate is 5.7% or 1 in 17. It is in compare with allopathic treatment, cases treated 1522 among died 373 so the mortality rate is 24.5%, or 1 in 4<sup>[7]</sup>.

### A case report

A Male patient of 47 yrs came to the OPD of Bhartesh Homeopathic Medical College and Hospital, on 3<sup>rd</sup> August 2024 with the complaints of fever since 2-3 days, breathlessness since 2-3 days, pain in the abdomen left side since 2 days.

### Details of chief complaints

1. Stitching type of pain in the left hypochondriac region since 2-3 days
  - Aggravated on turning left to right
  - Ameliorated by rest.
2. Breathlessness
  - Aggravated on lying down
  - Ameliorated by seating up
3. Dry cough since 2-3 days
  - Aggravated at night
  - With occasionally pain in the left side of the chest.
4. Also has a complaint of recurrent acidity
  - Ameliorated after vomiting.

He is a known case of HTN & has loss of hearing for left ear has a rupture of the tympanic membrane.

### Family history

Mother has HTN, muscle dystrophy of left leg  
Father died of MI, he had HTN.

### Personal history

Appetite - Decreased due to complaints  
Habits-Alcoholic  
Food agg- Oily, spicy food causes acidity  
Bowel movements- Constipated since 2 days  
Sleep -Disturbed due to complaints

### Clinical findings

On examination BP- 120/90 mmhg, PR-97 bpm, SpO<sub>2</sub>-95%, weight -82kg, RR-16 cpm. On respiratory examination crepitations heard ++++ more on left side, abdominal examination showed mild tenderness on left hypochondriac region, aggravated on turning left to right & ameliorated by rest.

### Lab investigation

Hematology report showed increase in the neutrophils count -84% (Fig 2), chest x-ray showed left basal consolidation (3/8/24) (Fig 3 (a &b)). USG abdomen showed left renal calculus.

### Diagnosis

Viral pneumonia

### Selection of the symptoms

- Pain in the hypochondria region
- Dry cough without expectoration
- Breathlessness
- Congestion of chest in left side
- Sleep disturbed
- Left side affection
- Agg on turning
- Stitching type of pain
- Sitting amel

### Repertory selected

Synthesis repertory (mobile version)

### Reportorial totality

- **Abdomen** - Hypochondria; complaints of
- **Respiration** - Difficult
- **Cough** - Dry
- **Chest** - Congestion
- **Sleep** - Sleeplessness
- **Generals** - Side - left
- **Generals** - Motion- agg.
- **Generals** - Pain- stitching pain
- **Generals** - Sitting - amel.

ABDOMEN	Remedies	ΣSym	ΣDeg	Symptoms
<b>1 ABDOMEN -</b>	bry.	9	25	1, 2, 3, 4, 5, 6, 7, 8, 9
<b>HYPOCHONDRIA; complaints of</b>				
<b>RESPIRATION</b>	sulph.	9	24	1, 2, 3, 4, 5, 6, 7, 8, 9
<b>2 RESPIRATION - DIFFICULT</b>	chin.	9	23	1, 2, 3, 4, 5, 6, 7, 8, 9
<b>COUGH</b>	nux-v.	9	22	1, 2, 3, 4, 5, 6, 7, 8, 9
<b>3 COUGH - DRY</b>	phos.	9	22	1, 2, 3, 4, 5, 6, 7, 8, 9
<b>CHEST</b>	sep.	9	22	1, 2, 3, 4, 5, 6, 7, 8, 9
<b>4 CHEST - CONGESTION</b>	acon.	9	21	1, 2, 3, 4, 5, 6, 7, 8, 9
<b>SLEEP</b>	bell.	9	20	1, 2, 3, 4, 5, 6, 7, 8, 9
<b>5 SLEEP - SLEEPLESSNESS</b>	merc.	9	20	1, 2, 3, 4, 5, 6, 7, 8, 9
<b>GENERALS</b>	puls.	9	20	1, 2, 3, 4, 5, 6, 7, 8, 9
<b>6 GENERALS - SIDE - left</b>				
<b>7 GENERALS - MOTION - agg.</b>				
<b>8 GENERALS - PAIN - stitching pain</b>				
<b>9 GENERALS - SITTING - amel.</b>				


Fig 1: Reportorial chart

**Prescription**

Bryonia 200C 1 dose on (3/8/2024)

**Follow up**

Date	Complaints	Prescription
4/8/2024 10.00am	<ul style="list-style-type: none"> <li>Breathlessness persistent</li> <li>Dry cough present</li> <li>Pain in the hypochondria region</li> <li>Crepitation present</li> <li>Sleep improved</li> </ul>	PL
5/8/2024 10.00am	<ul style="list-style-type: none"> <li>Breathlessness slightly better than before</li> <li>Dry cough present</li> <li>Pain in the hypochondriac region slightly present</li> <li>Crepitations present</li> </ul>	PL
6/8/2024 10.00am	<ul style="list-style-type: none"> <li>Chest X-ray showed no congestion (fig 4)</li> <li>Slight crepitations can be still heard</li> <li>Pain in the hypochondriac region reduced completely</li> <li>Dry cough present</li> <li>Patient discharged from hospital</li> </ul>	PL
12/8/2024 11.30 am	<ul style="list-style-type: none"> <li>No crepitations heard</li> <li>Pain reduced completely</li> <li>Slight cough present</li> </ul>	Sulphur200C 1dose (follow well)
24/8/2024 11.00am	<ul style="list-style-type: none"> <li>No symptoms pt recovered</li> </ul>	



# DISHA

(UNDER THE AUSPICES OF)

## BELGAUM DIAGNOSTIC & CARDIAC CENTRE PVT. LTD.

No. 11 & 12, Ground Floor, Radio Complex, Shivaji Road, BELGAUM - 590 001.

Phone : 0831-2422490 / 4217230 / 4810618 / 4810619 Cell : +91 91132 29152 E-mail : dishabelgaum@yahoo.com

FACILITIES : Pathology, Endoscopy, Video Gastroscopy, R.I.A. Studies, Elisa, Stress Test, ECG, Micro Biology, Pulmonary Function Test, Digital "X" Ray, Ultra Sound, Colour Doppler, E E G, Echo Cardiography, Allergy Test

---

Patient Name :  
 Sex : Male
 Lab No : **65**

Age : 47 years
 Referred by: Dr. Arya
 Date : 03/08/2024


(Thank you for reference)


---


### HAEMATOLOGY REPORT

Haematology performed by CELLTAC Computerised Cell Counter.

Haemoglobin (Hb%)	: 14.8	gms%	Normal Range
			13 - 15.5 gms%
Total W.B.C Count	: 10,700	cells/cumm	4,000 - 11,000 Cells/cumm
<b>Differential Count</b>			
Neutrophils	: 84	%	40 - 70%
Lymphocytes	: 10	%	25 - 45 %
Eosinophils	: 02	%	1 - 5 %
Monocytes	: 03	%	2 - 8 %
Basophils	: 01	%	0 - 2 %
<b>Platelet Count</b>	: 2.53 Lakhs/cu.mm.		1.5 - 4.5 Lakhs/cu.mm
<b>Rapid Malaria Test</b>	: Negative		

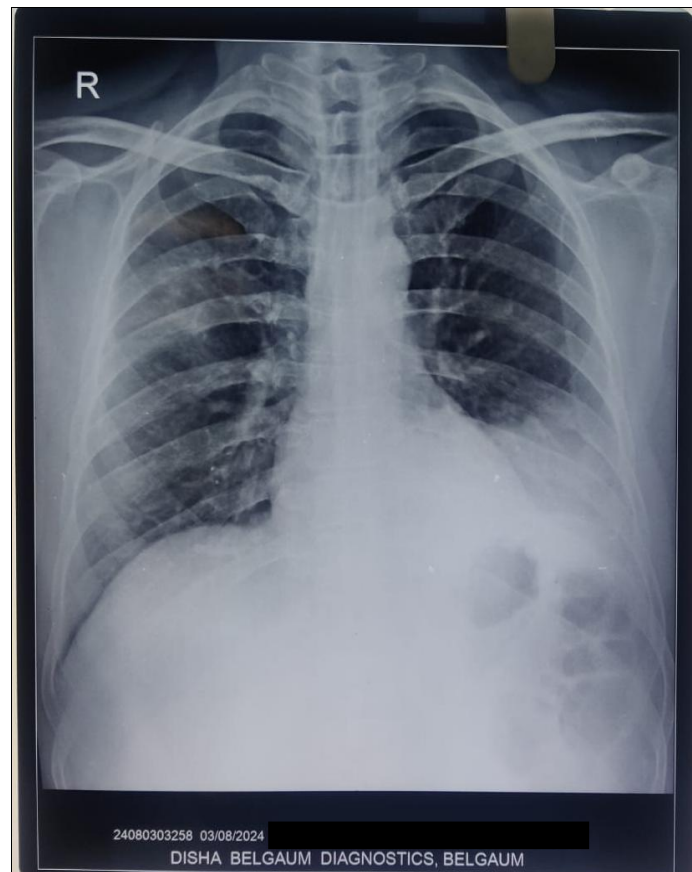Printed by   
 (Shahid/Renuka)

  
 Lab. Technician

  
 Dr. Krishna G Mane  
 MD(Path)

Note- Investigations have their limitations. Solitary Pathological & other investigations never confirm the final diagnosis. They only help in diagnosing the disease in co-relation to clinical symptoms & other related tests. Please interpret accordingly.

**Fig 2**



(a)

**DISHA**  
(UNDER THE AUSPICES OF)  
BELGAUM DIAGNOSTIC & CARDIAC CENTRE PVT. LTD.

No. 11 & 12, Ground Floor, Radio Complex, Shivaji Road, BELGAUM-590 001.  
Phone : 0831- 2422490 / 4217230 / 4810618 / 4810619 Cell : +91 91132 29152 Email : dishabelgaum@yahoo.com

FACILITIES : Pathology, Endoscopy, Video Gastroscopy, R.I.A. Studies, Elisa, Stress Test, ECG, Micro Biology, Pulmonary Function Test, Digital "X" Ray, Ultra Sound, Colour Doppler, E E G, Echo Cardiography, Allergy test.

Name : [REDACTED] Age/Sex : 47 Yrs/M

Ref. by : Dr. Arya. 03/08/2024  
(Thanks for reference).

**RADIOGRAPH OF CHEST PA VIEW:**

- \* Left basal region shows nonhomogeneous opacities silhouetting the left dome of diaphragm.
- \* Both the hila are normal in position and radiodensity.
- \* Right CP angle is free.
- \* Right dome of diaphragm is normal in position & contour.
- \* Cardiac shadow appears normal.
- \* Bones & soft tissue of the chest wall appear normal.

**Impression:**

- \* Left basal consolidation.

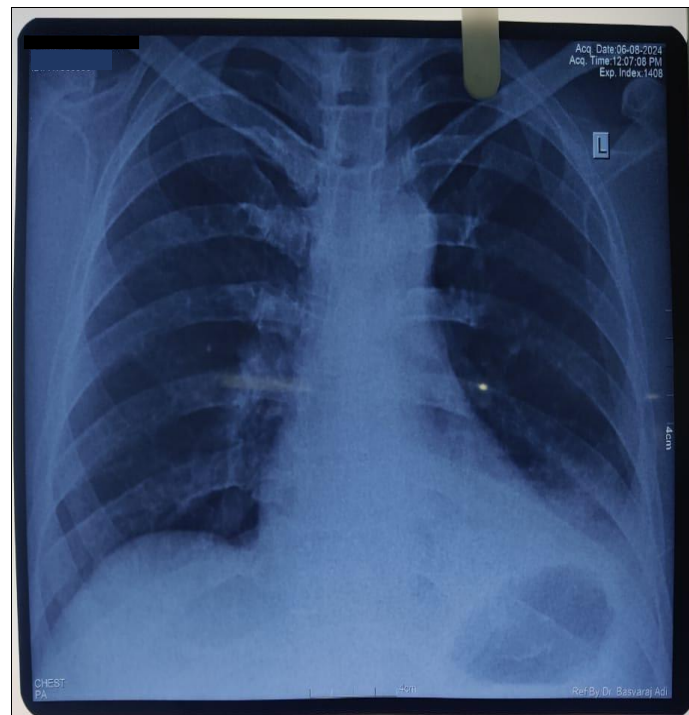
Dr. Geeta K. Pattanshetti, DMRD DNB  
Radiologist

*Investigation have their limitations. Solitary pathological/Radiological and other investigation never confirm the final diagnosis. They only help in diagnosing the disease in correlation to clinical symptoms and other related tests. Please interpret accordingly. Note : please bring this report for next scan.*

(b)

Fig 3: Date -3/8/2024





**Fig 4:** Date-6/8/2024

### Differential remedies of pneumonia

#### **Bryonia** <sup>[4]</sup>

- There is a frequent desire to take a long breath and feels as if he must expand lungs.
- Respiration is difficult and quick getting worse with every movement and caused by stitches in chest.
- During Cough there is a feeling as if chest would fly into pieces so presses his head on sternum; feels as if chest need to be supported.
- Tough mucus in trachea can loosened only with much hawking. Entering into the warm room excites cough.
- There is a feeling of heaviness beneath the sternum which is extending towards the right shoulder.
- There is Stitching sensation in the cardiac region.
- Aggravated on motion <sup>[4]</sup>.

#### **Sulphur** <sup>[4]</sup>

- Sensation of burning and heaviness in the chest
- Difficulty in breathing, desires windows open.
- Loose cough which is aggravated by talking and also in the morning.
- Chest feels heavy as of a load on chest.
- Stitching type of a pain radiating to the back, which is worsened by lying on back or taking deep breath.
- Dyspnoea caused in the mid night, which is relieved by sitting upright <sup>[4]</sup>.

#### **Phosphorus** <sup>[4]</sup>

- Cough caused by tickling in the throat, worsened by cold air, reading, laughing, talking, from going from warm room into cold air as there is sudden change in temperature.
- While coughing there is a sweetish taste in the mouth.
- Cough is hard, dry, tight and exhausting.
- Lungs feel as if congested.
- Sensation of burning pain as if heat in the chest.
- Tightness around the chest.

- Feels there is a great weight on the chest
- Sharp stitching type of pain in the chest with quick respiration.
- Pneumonia with sense of oppression, worse when lying on left side.
- Trembling of the whole body during cough.
- Pain in the throat during coughing. Nervous coughs triggered by strong odors, entrance of a stranger <sup>[4]</sup>.

#### **Arsenicum album** <sup>[4]</sup>

- Unable to lie down due to fear of suffocation.
- Airways constricted.
- Severe Burning sensation in chest.
- Cough aggravated after midnight and when lying on back.
- Cough with scanty, frothy expectoration.
- Darting pain through the upper third of right lung.
- Wheezing.
- Cough dry, as if from sulphur fumes worse after drinking <sup>[4]</sup>.

### Rubrics related to pneumonia

- Kent <sup>[3]</sup>

Chest - Hepatization of lungs

Chest - Inflammation - lungs

- Boerick <sup>[4]</sup>

Resp. system- Inflammation-

- Bronchopneumonia
- Croupous pneumonia
- Stages of pneumonia -congestive
- Stage of Consolidation
- Stage of resolution

### Complete repertory <sup>[5]</sup>

Respiration-difficult; pneumonia,

Chest-Inflammation; lungs, pneumonia

## Conclusion

This case demonstrates the successful management of viral pneumonia using homoeopathic medicine. The patient's symptoms, including breathlessness, dry cough, stitching pain, and disturbed sleep, were effectively addressed through individualized remedy selection based on totality of symptoms. Bryonia 200C was selected initially, followed by Sulphur 200C, leading to a marked improvement in clinical condition, as evidenced by the resolution of crepitations, reduction of pain, and overall symptom relief. This highlights the importance of detailed case-taking, proper repertorization, and individualized homoeopathic remedy selection in managing acute respiratory conditions like pneumonia. While further research and larger clinical trials are needed, this case adds to the growing body of evidence supporting homoeopathy as a viable therapeutic approach in certain cases of pneumonia.

## References

1. Kim EA, Lee KS, Primack SL, Yoon HK, Byun HS, Kim TS, *et al.* Viral pneumonias in adults: radiologic and pathologic findings. Radiographics [Internet]. 2002;22 Spec No(suppl\_1):S137-S149. Available from: [http://dx.doi.org/10.1148/radiographics.22.suppl\\_1.g02oc15s137](http://dx.doi.org/10.1148/radiographics.22.suppl_1.g02oc15s137)
2. Mohan H. Textbook of pathology. 5th ed. Royal Tunbridge Wells (GB): Anshan, 2005.
3. Kent JT. Repertory of the homeopathic materia medica. New Delhi (IN): B Jain, 2023.
4. Boericke W. Pocket manual of homeopathic materia medica & repertory. New Delhi (IN): B Jain, 2007.
5. Zandvoort R. Complete Repertory 2022, Repertory by Roger Zandvoort. Homopath.com; [cited 2024 Jun 8]. Available from: <https://homopath.com/complete-repertory-2022>
6. Suri DMC. Role of homoeopathic in management of broncho-pneumonia. Int J Homoeopathic Sci [Internet]. 2021;5(1):99-103. Available from: <http://dx.doi.org/10.33545/26164485.2021.v5.i1b.301>
7. RadarOpus. The Synthesis App. Radaropus.com; 2015 [cited 2025 Apr 22]. Available from: <https://www.radaropus.com/products/apps/synthesis-app>

### How to Cite This Article

Savari S. Volvoikar and Geeta B. Adi. A case of viral pneumonia treated with homoeopathic medicine: A case report. International Journal of Homoeopathic Sciences. 2025;9(2):166-171.

### Creative Commons (CC) License

This is an open access journal, and articles are distributed under the terms of the Creative Commons Attribution-NonCommercial-ShareAlike 4.0 International (CC BY-NC-SA 4.0) License, which allows others to remix, tweak, and build upon the work non-commercially, as long as appropriate credit is given and the new creations are licensed under the identical terms.