



International Journal of Homoeopathic Sciences

E-ISSN: 2616-4493
P-ISSN: 2616-4485
Impact Factor (RJIF): 5.96
www.homoeopathicjournal.com
IJHS 2025; 9(3): 1331-1334
Received: 05-07-2025
Accepted: 07-08-2025

Dr. Vijay Kumar Pushkar
MD (Hom.), Principal, State
National Homoeopathic
Medical College and Hospital,
Lucknow, Uttar Pradesh,
India

Dr. Iffat Ahmad Rayeen
MD(Hom.) and Lecturer,
Department of Organon of
Medicine and Homoeopathic
Philosophy, State National
Homoeopathic Medical College
and Hospital, Lucknow, Uttar
Pradesh, India

Dr. Shwetha Shree
PG Scholar, Department of
Organon of Medicine and
Homoeopathic Philosophy,
State National Homoeopathic
Medical College and Hospital,
Lucknow, Uttar Pradesh,
India

Dr. Vaishali
PG Scholar, Department of
Organon of Medicine and
Homoeopathic Philosophy,
State National Homoeopathic
Medical College and Hospital,
Lucknow, Uttar Pradesh,
India

Corresponding Author:
Dr. Vijay Kumar Pushkar
MD (Hom.) and Principal,
State National Homoeopathic
Medical College and Hospital,
Lucknow, Uttar Pradesh,
India

Individualized homoeopathic management of atopic dermatitis: A case report

Vijay Kumar Pushkar, Iffat Ahmad Rayeen, Shwetha Shree and Vaishali

DOI: <https://www.doi.org/10.33545/26164485.2025.v9.i3.U.1826>

Abstract

Atopic dermatitis is a chronic, relapsing, inflammatory skin disorder that severely affects quality of life. In conventional medicine, symptomatic relief is often temporary and dependent on topical or immunosuppressive agents. Homoeopathy, grounded in the holistic understanding of disease and the principle of individualization, offers an alternative and curative approach by treating the internal miasmatic cause. This article presents a detailed case of a 36-year-old female patient suffering from chronic eczematous eruptions on both hands. Based on a thorough case-taking process, a remedy was selected in accordance with the totality of symptoms and miasmatic analysis. The patient's response over multiple follow-ups shows the scope of classical homoeopathic intervention in chronic dermatological conditions like eczema.

Keywords: Dermatitis, homoeopathy, atopic, miasm

Introduction

Eczema or dermatitis is a common skin condition characterized by inflammation, erythema, vesiculation, oozing, crusting, and scaling. The word eczema is derived from the Greek term meaning “to boil out,” describing the vesicular nature of acute eruptions. In clinical terms, eczema refers to both exogenous (irritant/contact) and endogenous (atopic) varieties. Atopic dermatitis (AD) is a chronic, pruritic skin disease typically seen in individuals with a personal or family history of atopic conditions like asthma, rhinitis, or food allergies ^[1].

From a homoeopathic perspective, eczema is not merely a superficial skin disorder but a dynamic expression of internal disequilibrium. As described by Dr. Hahnemann in his work *The Chronic Diseases*, suppression of skin eruptions may lead to more serious internal ailments. Therefore, the skin must be allowed to express this inner imbalance, and the remedy must act from within.

Homoeopathy treats eczema using the principle of *similia similibus curentur*-like cures like-where a remedy is selected based on a holistic evaluation of the case, including mental, emotional, and physical generals, as well as miasmatic tendencies.

This article presents a classical homoeopathic management of a chronic case of atopic dermatitis, demonstrating the efficacy of individualized treatment over multiple follow-ups and highlighting the role of miasmatic analysis and repertorization.

Case Report

Patient Details

- **Name:** Mrs. XYZ
- **Age/Sex:** 36/F
- **Marital Status:** Married
- **Religion:** Hindu
- **Date of first visit:** 25-04-2024

Present Complaints

Eczematous eruptions on the back of both hands for 3 years.

Dry, cracked, thickened skin with intense itching and rawness post scratching.

No discharge present.

Itching worse in the morning, slightly relieved by cold application although no significant relief.
Pain with stiffness in nape of neck with pain radiation to right arm since 2.5 months.

History of Presenting Complaint

Complaints started in December 2021 with mild itching and rashes.

Symptoms gradually worsened despite allopathic treatment and ointment use.

Temporary relief followed by recurrence.

Past Medical History

Tubercular lymphadenitis (Feb 2019) - Got homoeopathic treatment for it.

Typhoid fever (2016 and 2017).

No major surgeries or chronic illnesses apart from the current skin condition.

Family History

- **Father:** Diabetes mellitus, arthritis.
- **Mother:** Allergic rhinitis.

Physical Generals

- **Appetite:** Good
- **Thirst:** Thirstless
- **Stool:** Normal, constipated before menses and after having junk food.
- **Urine:** Normal
- **Perspiration:** Profuse on forehead and axilla; offensive
- **Thermal Reaction:** Chilly
- **Desire:** Sweet

Gynecological & Obstetric History

- **LMP:** 19/04/2024
- **Cycle:** Regular, 28-day cycle
- **Flow:** Profuse on first and second day
- **Obstetric History:** G2P2A0L2
- **Mode of Delivery:** Caesarean Section

Mental Generals

Anxious, especially about new or unexpected situations.

Palpitations when startled.

Introverted and emotionally dependent on her husband.

Feels unsupported, especially in domestic conflicts with in-laws.

Feels emotionally isolated despite physical relocation with husband.

Case Processing

Totality of Symptoms

1. Ailment from domination.
2. Despair of recovery.
3. Fear of contagious disease.
4. Anxiety, especially related to emotional neglect.
5. Eczema with intense pruritus.
6. Personal history of tuberculosis.

7. Desire for sweets.

8. Emotional dependency and introversion.

Diagnosis of disease (nosological): Atopic Dermatitis

Homoeopathic diagnosis: Chronic fully developed miasmatic disease.

Miasmatic Analysis

- Psoric Symptoms.
- Anxiety
- Itching
- Desire for sweets
- Introversion
- Sycotic Symptoms
- Cracked skin
- Chronicity of eruptions
- Thickened skin.

Miasmatic Diagnosis: Psora + Sycosis.

Repertorial Analysis

Indicated remedy: Calcarea Carb. 200/3 doses

Early morning on empty stomach

Saclac 30 tds/ 15 days

General Management

- Avoid stress and irritants.
- Apply coconut oil to affected areas.
- No topical ointments or steroids.
- Maintain hydration and proper nutrition.

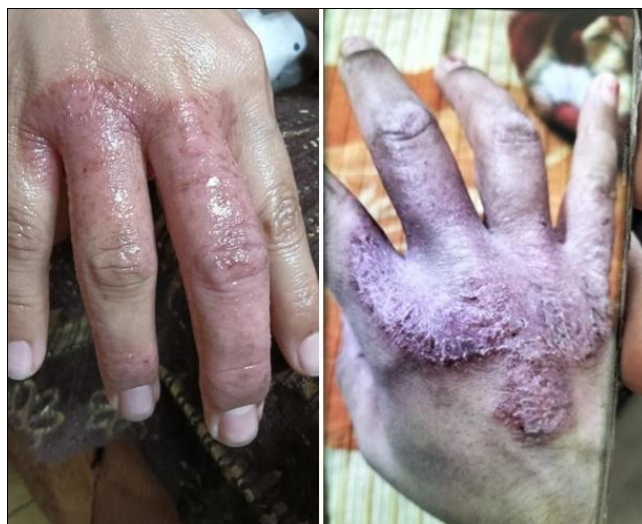

Fig 1: First Visit-25/04/2024

Follow-up





1st Follow-up (13/05/2024)

No significant change.

Rx: Rubrum Metallicum 200 / 3 doses

Saclac 30 / TDS × 15 days

Table 1: Follow-up Dates, Observations, and Prescriptions of the Patient from May to August 2024

S. No.	Date	Follow Up	Prescription
1.	13-05-2024	No significant changes	Saclac 30 tds 15days.
2.	03-06-2024	No significant changes	Saclac 30 tds for 15 days
3.	21-06-2024		Saclac 30 tds 15 days
4.	19-07-2024		Calcarea carb 200/3 doses.
5.	05-08-2024		Saclac 30 tds for 15 days.
6.	25-08-2024		Saclac 30 tds for 15 days.

Conclusion

The case of atopic dermatitis improved remarkably under individualized homoeopathic treatment, with reduction in itching, dryness, and recurrent flare-ups. Holistic management addressed both physical and emotional factors, leading to lasting relief and better quality of life. This highlights homeopathy's potential in chronic dermatological conditions through constitutional prescribing.

Conflict of Interest

Not available.

Financial Support

Not available.

References

1. Khanna N. Illustrated Synopsis of Dermatology and Sexually Transmitted Diseases. New Delhi: Elsevier.
2. Longo DL, Kasper DL, Jameson JL, Fauci AS, Hauser SL, Loscalzo J, editors. Harrison's Manual of Medicine. 19th ed. New York: McGraw-Hill Education.
3. Banerjee SK. Miasmatic Prescribing. 2nd ed. New Delhi: B. Jain Publishers.
4. Bailey PM. Homoeopathic Psychology: Personality Profiles of the Major Constitutional Remedies. London: North Atlantic Books.
5. Hahnemann S. Organon of Medicine. 6th ed. New Delhi: B. Jain Publishers.

How to Cite This Article

Pushkar VK, Rayeen IA, Shree S, Vaishali. Individualized homoeopathic management of atopic dermatitis: A case report. International Journal of Homoeopathic Sciences. 2025; 9(3): 1331-1334.

Creative Commons (CC) License

This is an open access journal, and articles are distributed under the terms of the Creative Commons Attribution-NonCommercial-ShareAlike 4.0 International (CC BY-NC-SA 4.0) License, which allows others to remix, tweak, and build upon the work non-commercially, as long as appropriate credit is given and the new creations are licensed under the identical terms.