



International Journal of Homoeopathic Sciences

E-ISSN: 2616-4493

P-ISSN: 2616-4485

www.homoeopathicjournal.com

IJHS 2020; 4(3): 87-91

Received: 17-05-2020

Accepted: 20-06-2020

Dr. Ranjit Sonny

BHMS (Hons), MD(Hom),
NIH, Kolkata, Research
Officer, (Homoeopathy)
Scientist-1, Officer- In-charge,
Regional Research Institute
(Homeopathy), under CCRH,
Ministry of AYUSH Govt. of
India, Guwahati, Assam, India

Verruca vulgaris amenable to individualised homeopathy: A case report

Dr. Ranjit Sonny

Abstract

Verruca vulgaris is a type of wart esp located on the fingers, around the nails, on the back of the hands and where skin was broken. In this case multiple common warts were present on the back of right hand, fingers and toes associated with chronic otorrhoea and impaired hearing. Natrum muriaticum, Silicea and Thuja occidentalis were prescribed at different points of time. Prescriptions were done on the basis of individualisation and indications as appeared time to time. Patient reported complete disappearance of warts from Natrum mur applied in various potencies.

Keywords: Warts, human papilloma virus, homoeopathy, natrum muriaticum, Silicea, Thuja Occidentalis, Miasm

Introduction^[1]

AIM: This case report is aimed at sharing with the profession the efficacy of homeopathy and affinity of Natrum muriaticum in case of warts on fingers and toes.

Warts are common worldwide affecting approximately 10% of the population in both sexes. It is a benign lesion that occurs in the mucosa and skin caused by Human papilloma virus (HPV). There are around 100 subtypes of HPV. Any age group can be affected but children, teens, people who bite their nails or pick at hangnails and people with a weakened immune system are more susceptible. On the basis of location and appearance warts may be of following types-

Verruca vulgaris or Common warts: It grows most often on the fingers, around the nails, on the back of the hands and where skin was broken. HPV sub types 2 and 4 are mainly responsible for this. They have black dots that look like seeds, often called “seed” warts and feel like rough bumps.

Plantar warts or Foot warts or mosaic warts: It grows most often on soles, plantar surface of the feet in clusters. They grow flat or inward and have black dots and caused by HPV sub types 2, 3, 4, 27, and 57.

Flat wart: It usually grow on the face, beard area and legs. They are smaller and smoother and tend to grow in large numbers – 20 to 100 at a time and caused by HPV sub types 3, 10 and 28.

Filiform wart: It looks like long thread or thin fingers that stick out and grows on the face around the mouth, eyes and nose. It is caused by HPV sub types 2 and 4.

Verruca vulgaris are easily transmitted by direct or indirect contact, especially if there is disruption of the normal epithelial barrier. In general they are benign but HPV strains 5, 8, 20 and 47 have the malignant potential and sometimes develop into what is known as Verrucous carcinoma. The Verrucous carcinoma is a slow growing tumor and is classified as a well-differentiated squamous cell malignancy that often mistaken for a common wart. Homoeopathy enjoys a reputation of providing a successful management of wart conservatively which has been validated by various research studies. Individualised homeopathy i.e medicine prescribed on the basis of strict individualisation of the given case, not only removes the wart but also the disposition to develop this condition. Through this case report we shall discuss how an inveterate case of V. vulgaris can be managed on the basis of symptoms similarity.

Corresponding Author:

Dr. Ranjit Sonny

BHMS (Hons), MD(Hom),
NIH, Kolkata, Research
Officer, (Homoeopathy)
Scientist-1, Officer- In-charge,
Regional Research Institute
(Homeopathy), under CCRH,
Ministry of AYUSH Govt. of
India, Guwahati, Assam, India

Case report

A 20 years old, student, Islam by religion came for treatment in General OPD of Regional Research Institute (Homoeopathy), Guwahati on 07/07/2017. He was suffering from multiple Verruca vulgaris (B07.0-ICD-10) on back of right hand, fingers and left foot for more than 1 year (figure-1&2). He was also having purulent discharge from both ears with impaired hearing for the last 3 years.

Medical History

Otoendoscopy done on 16.08.2016 showed retraction of postero- superior quadrant of left tympanic membrane and central perforation with scanty mucoid discharge from right tympanic membrane. ENT specialist advised for surgical treatment. But patient declined for surgery and came for homoeopathic treatment in the OPD of Regional Research Institute (Homoeopathy), CCRH, Guwahati.

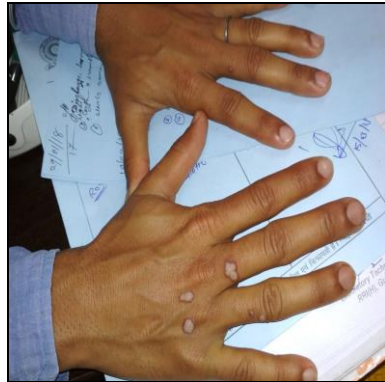


Fig 1: Before treatment.

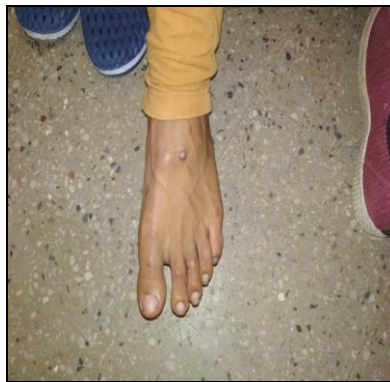

Fig 2: Before treatment

Homoeopathic Generalities

Mental

Mild and earnest disposition.

Physical

Patient was lean, thin having fair complexion. Appetite was good. Desire for sweet, sour, meat, onion and tea. Thirst was excessive. Stool constipated usually at 2 days interval. Perspiration profuse. Tongue was clean and moist.

Past History

Nothing in particular.

Family History

Nothing in particular.

Evaluation of symptoms

After case taking following symptoms were considered to be important for evaluation, miasmatic analysis and repertorisation.

1. Common warts on right hand, fingers and left foot with no tenderness.
2. Discharge from ear.
3. Impaired hearing.
4. Mildness.
5. Physically Lean, thin, fair complexion.
6. Thirst increased.

7. Constipated.
8. Perspiration profuse.
9. Desire for sweet, sour, meat, onion, tea.

Miasmatic Analysis [2, 3, 4]

Psoric miasm

1. Constipated
2. Perspiration profuse
3. Desire for sweet
4. Desire for meat

Sycotic miasm

1. Warts on right palm and toes.
2. Desire for sour.

Syphilitic miasm

1. Purulent discharge from ear.
2. Impaired hearing.
3. Mildness.

Repertorisation [5]

Repertorization done with the help of Radar 10.5 for windows; Schroyens F; Synthesis TE 2009 (SE 2009). After repertorization Natrum muriaticum, Sulphur and Calcarea carbonicum emerged as top three medicines as given in Figure 1.

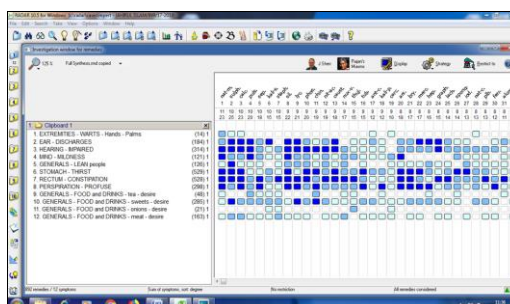


Fig 3: Repertorial sheet

Treatment and follow UP

After case taking, case analysis and repertorization Natrum

muriaticum 30, 4 doses, OD, was prescribed as first prescription. Follow ups are given in the table no. 1.

Table 1: Follow-ups and Prescriptions

05.09.2017 F.U-01	-Warts same as before. New warts appear on hand and dorsum of feet. -Watery discharges from both ears X 15 days. - Blister formation in finger of right hand	Silicea 30c Placebo	Bd x 2 days OD x 14 days
12.09.2017 F.U-02	- Patient in general improved than before - Watery discharges from ear is slightly improved. -Warts same as before.	Placebo	OD x 15 days
23.09.2017 F.U-03	- Patient is better in general - Pain and discharges from ear less than before. - warts same as before	Silicea 200 Placebo	OD x 2 days OD x 14 days
21.10.2017 F.U-04	- Patient is better in general. - Hearing improving. - Watery discharges from ears much less than before.	Silicea 1M Placebo	OD x 2 days OD x 14 days
06.11.2017 F.U-05	- Patient is improved in general. - Hearing improved by 70% (According to patient) - Otorrhea slightly persists - Warts same as before	Silicea 1M Placebo	OD x 2 days OD X 30 days
25.11.2017 F.U-06	- On report - Patient is improved in general	Placebo	OD x 14 days
23.12.2017 F.U-07	-Hearing of ears improved - Purulent discharge of fluid from both ears reappears since 4 days. - Warts over dorsum of hand increased in size.	Thuja Occidentalis 200 Placebo	OD x 2 days Od x 30 days
29.01.2018 F.U-08	- Discharges from both Ears slightly present, - Warts same as before N/C -Dry cough since 1 month	Thuja Occidentalis 200 Placebo	OD x 3 days OD x 30 days
19.03.2018 F.U-09	-Hearing Improved, but discharges from ear persists. - Cough improved. - Warts size increasing- on Right hand, left hand, and feet.	Thuja occidentalis 200 Placebo	OD x 4 days OD x 14 days
02.04.2018 F.U-10	-Patient is better in general - Warts remain same	Thuja occidentalis 1M Placebo	Od x 2 days Od x 14 days
17.04.2018 F.U-11	- Ear complaint decreased by 60% - Purulent discharges from left Ear persists - Warts remain same.	Thuja Occidentalis 1M Placebo	Od x 2 days Od x 30 days
29.05.2018 F.U-12	-No discharges from ear - Hearing impairment slightly present. Warts on feet become hard and size increasing.	Natrum Muriaticum 200 Placebo	Od x 4 days Od x 30 days
11.07.2018 F.U-13	- Hearing complaints much improved - No discharges from ear - Warts same as before N/C – Acne on face	Natrum mur 1M Placebo	Od x 2 days Tds x 30 days
28.08.2018 F.U-14	- Ear discharges reappear, slightly -warts slightly decreased in size	Natrum mur 1M Placebo	Od x 4 days Od x 14 days
22.09.2018 F.U-15	- Warts over feet disappeared - warty growth over fingers much decreased but few still persisting - Discharges from right ear	Natrum mur 10M Placebo	Od x 2 days Od X 14 days
29.10.2018 F.U-16	- Discharges from ear decreased by 60% - Warts in hands, feet diminished. -Acne less than before	Placebo	Od x 14 days
14.11.2018 F.U-17	- Patient is improving in general	Placebo	Od x 14 days
24.11.2018 F.U-18	- Watery discharges from right ear slightly persist. - Acne on face decreased - Warts on finger and feet disappeared, few remaining	Natrum mur 10 M Placebo	Od x 2 days Od x 14 days
03.01.2019 F.U-19	-Patient is better than before in general - Acne on face.	Natrum mur 10M Placebo	Od x 2days Od X 14 days
21.01.2019 F.U-20	- Warts on hand and feet disappeared - Acne on face stands still - Watery discharges from ear persists	Natrum mur 10M Placebo	Od x 4 days Od x 30 days

Discussion

Verruca vulgaris is a kind of disease which looks inert on the surface of skin but it has deep rooted origin in the form of defective dynamis or vitality. Basic research has discovered its immediate cause as Human papilloma virus. In Organon of Medicine Master Hahnemann has categorised warts under sycotic miasm [6]. He has discussed in detail about its underlying dynamic pathology and way of

treatment esp in 6th edition. For its treatment external application with potency of same medicine internally has been advocated. But no external application was used in this case. It is easily amenable to homoeopathic treatment. In a randomized double – blind clinical trial conducted by J.T. Kainz *et al.* showed that there is a difference between the effectiveness of homeopathic therapy and placebo in common warts [7]. In the study conducted by Dr. Ramji

Gupta *et al.* out of 21 out of 22 cases of Verruca vulgaris recovered completely from Thuja, Ruta, Nit. Acid, Calc carb, Nat mur, Causticum, Antim crud and Opium^[8]. In this condition homeopathic LM potency is also effective as shown in the case series by Md. Ismail Shaikh^[9]. Though the affinities of above mentioned medicines vary according to the presentation esp location, shape and size of the wart. In this case patient was suffering from multiple Verruca vulgaris on back of right hand, fingers and toes of left foot associated with chronic otorrhoea and impaired hearing. After case taking symptoms as given under heading "Evaluation of symptoms" could be found as totality of symptoms. After repertorization and referring to materia medicas^[10, 11, 12], Natrum muriaticum emerged as the top most medicine. Natrum muriaticum 200 was prescribed. In first follow up after 2 months of first visit, warts on hand and foot were almost same. Purulent discharge from both ears was aggravated. Considering the acuteness of the condition Silicea 30/4 doses, BD was prescribed. Subsequently discharge from ear diminished. Placebo was given. After that in three consecutive follow ups patient reported gradual improvement with increasing potencies of Silicea. As the discharge from ear diminished but warts over dorsum of hand and feet aggravated both in number and size. This phenomenon may be because of process of curing, movement of disease from more important organ to less important organ or because of suppression of ear discharge. A re-evaluation of the case was done and Thuja occidentalis 200, 2 doses, OD was prescribed taking into account the miasmatic block that may be persisting as Natrum muriaticum being well indicated, failed previously. Thuja was continued for next four follow ups in increasing potencies. During this period, discharge from ear was better but no improvement in the warts as expected. Hence re-evaluation of the case was done. Author has a good, successful experience with Natrum mur in warts of palms and fingers in the past. It is in second grade in repertories like the Essential Synthesis Repertory^[13] and Kent's Repertory^[14] etc having rubrics Extremities- warts- back of hands and Extremities –warts- back of hands respectively. Further Natrum mur was not given sufficient time in higher potencies during first prescription in this case. Hence Natrum mur was again prescribed. After re-administration of Natrum mur patient started improving which was continued till next eight follow ups. During this period Verruca vulgaris gradually diminished in size and number. After Natrum mur 10M warts on hands, fingers and foot completely vanished leaving the area absolutely normal, as if nothing had happened in the past as shown in the post treatment photograph (figure- 4). From this case several lessons are to be learnt. The first prescription should have been given more time or next higher potency should have been applied before switching over to Silicea. Several factors interplay during process of curing esp. chronic disease like miasm, concomitants, wait and watch after prescription, choice of second prescription etc. Anti miasmatic treatment may not relieve the presenting complaints in first instance but pave the way for other indicated medicine as happened here. We should not change medicine till improvement continues. Frequent change of medicine like in every follow up spoil the case and make it almost incurable. As per Organon of Medicine whatever may be the name of the disease the symptom similarity and individualisation is our soul guide as vindicated in this case

^[6]. Natrum mur not only removed the Verruca vulgaris, but also eradicated the tendency or disposition of its recurrence. Though most of the warts easily give in to homoeopathy still more intense research studies are warranted for evaluating the efficacy of several medicines in such condition as mentioned in our materia medicas and repertories.



Fig 4: After treatment

Conclusion

In consonance to its reputation homeopathic medicine acted successfully in case of Verruca vulgaris. Although three medicines were applied as per demand time to time but ultimately it was Natrum muriaticum in high potency which resolved the inveterate looking warts. It shows whatever may be the name of the disease symptoms similarity is the only way to follow. From homeopathic point of view wart having pathology deep inside the defective vitality can only yield to treatment modality when dynamic pathology is corrected by dynamic homeopathic medicine prescribed on the basis of symptom similarity after individualisation taking care of the underlying miasm.

Financial support and sponsorship

The study was funded by Ministry of AYUSH, Government of India.

Conflicts of interest

None declared.

References

1. Al About AM, Nigam PK. Wart (Plantar, verruca vulgaris, verrucae) [updated 2020 Apr 28]. In: Stat pearls [Internet]. Treasure Island (FL): Stat pearls publishing, 2020. Jan-Available from <https://www.ncbi.nlm.nih.gov/books/NBK431047/>
2. Heudens H. The foundation of the chronic miasms in the practice of homoeopathy. 1st ed. Leuven: Lutea Press, LLC, 2005, 21-67.
3. Degroote F. Notes on miasm, heredity and nosodes. 2nd ed. India: B. Jain publishers (P) LTD, 2010, 11.
4. Allen JH. The chronic miasm psora and pseudo-psora, New Delhi: B. Jain publishers (P) LTD, 1988.

5. Radar 10-EH. Belgium: Archibel homeopathic software, 2009.
6. Hahnemann S. Organon of Medicine, Fifth Ed. New Delhi: B. Jain Publishers (P) Ltd., 2002, 70.
7. Kainz JT, Kozel G, Haidvogel M. Homoeopathic versus Placebo therapy of children with warts on the hands: A randomized, double-blind clinical trial, *Dermatology*. 1996; 193:318-20.
8. Gupta R, Manchanda RK. Homoeopathy in the treatment of Warts. *British homoeopathic J*. 1991; 80:108-11.
9. Shaikh MI. Case studies for treatment of warts with Homoeopathy. *Indian J res homoeopathy*. 2016; 10:272-8.
10. Allen HC. Keynotes and Characteristics with Comparisons of some of the leading remedies of the materia medica with bowel nosodes, eight ed. New Delhi: B Jain Publishers (P) Ltd., 2002, 220.
11. Clarke JH. Adictionary of practical material medica, Vol-1, India B. Jain Publishers (P) Ltd., 561.
12. Boericke W. Boericke's New Mannual of Homoeopathic Materia Medica with repertory, Ninth ed. New Delhi: B. Jain publishers (P) Ltd; 2007. ria Medica With Repertory, Ninth ed. New Delhi: B. Jain Publishers (P) Ltd., 2007, 410.
13. Schroyens F. The essential synthesis, New Delhi, B. Jain Publishers (P) Ltd., 2012, 1640.
14. Kent JT. Repertory of the homoeopathic materia medica, sixth ed. Delhi: B Jain publishers (P) Ltd., 2001.