International Journal of Homoeopathic Sciences

E-ISSN: 2616-4493
P-ISSN: 2616-4485
Impact Factor (RJIF): 5.96
www.homoeopathicjournal.com
IJHS 2025; 9(4): 1051-1053
Received: 08-09-2025
Accepted: 10-10-2025

Dr. Sai Sanjay Kadam
Dr. D. Y. Patil Homoeopathic Medical College and Research Centre, Sant Tukaram Nagar, Pimpri, Pune, Maharashtra, India

Corresponding Author:
Dr. Sai Sanjay Kadam
Dr. D. Y. Patil Homoeopathic Medical College and Research Centre, Sant Tukaram Nagar, Pimpri, Pune, Maharashtra, India

A case of Tinea corporis managed with individualised homoeopathic treatment

Dr. Sai Sanjay Kadam

DOI: https://www.doi.org/10.33545/26164485.2025.v9.i4.P.2039

Abstract
Tinea Corporis is a superficial dermatophyte infection presenting with erythematous annular lesions and intense pruritus. Increasing resistance to antifungal therapy has resulted in many chronic or recurrent cases. This case report describes an 18-year-old male with tinea Corporis unresponsive to conventional antifungal treatment who improved significantly with individualised homoeopathic medicine. The clinical presentation, diagnostic criteria, intervention, and outcome are discussed. This case highlights the possible role of homoeopathy as an adjunct modality when conventional therapy provides inadequate relief.

Keywords: Tinea corporis, homoeopathy, sepia officinalis, individualise

Introduction
Tinea Corporis, commonly known as ringworm, is caused primarily by Trichophyton and Microsporum species and affects glabrous skin.[1] Typical features include annular erythematous plaques with a scaly advancing margin and central clearing.[2] In recent years, India has seen a marked rise in chronic dermatophytosis, attributed to humid climatic conditions, misuse of topical corticosteroids, and emerging antifungal resistance.[3]
Individualised homoeopathic treatment aims to stimulate the host's natural defence mechanism through medicines selected on the basis of characteristic signs, general tendencies, and emotional disposition.[4] This case illustrates successful improvement in chronic tinea Corporis under homoeopathic care.

Case Report

Patient Information
An 18-year-old young boy presented with recurrent skin lesions on the extremities and groin for four to five months. Itching primarily aggravated at night.

Personal History
The patient was vegetarian with a good appetite and strong preference for sweets. He drank 3-4 litres of water daily and maintained regular bowel and bladder habits. Perspiration was profuse, with a pronounced offensive odour and yellow staining of clothing. Sleep was sound and refreshing. Thermally he felt hot, preferred open air, required the fan constantly, and bathed in cold water. No addictions were reported.

History of Present Illness
The condition began with a solitary red, itchy lesion on the left hand, which progressively spread to the right hand, left leg, and groin. The lesions were circular, scaly, and associated with marked itching and burning, worsened at night, with sweating, and by tight clothing. The patient used topical and oral antifungals and antihistamines prescribed elsewhere but reported no substantial or lasting improvement.

Past History
No significant past medical illnesses.

Family History
Father had recently been diagnosed with hypertension; mother was apparently healthy; sister

had history of polycystic ovarian disease.

Mentals

The patient was easily irritated, reacted strongly to minor triggers, and tended to shout when angry. He disliked staying alone and preferred to be in company. He experienced restlessness and difficulty remaining seated for long.

Clinical Findings

General Examination

Vital signs were stable (BP 130/80 mmHg, Pulse 80/min, RR 18/min, afebrile). Cardiovascular, respiratory, neurological, and abdominal examinations were within normal limits.

Local Examination

Annular, erythematous patches with peripheral scaling and mild oedema were present over the extremities and groin. The lesions were rough on palpation and intensely pruritic but non-tender.

Differential Diagnosis

- Discoid eczema
- Psoriasis
- Seborrheic dermatitis
- Allergic contact dermatitis

Diagnostic Criteria

The diagnosis of tinea Corporis was made clinically on the basis of the typical morphology and behaviour of the lesions. The characteristic features observed in this patient annular erythematous plaques with a sharply demarcated and scaly active border, along with relative central clearing are hallmark signs described in established dermatological literature.[1, 2, 3, 4, 5] The chronic itching, particularly with worsening during perspiration and occlusion, further supported dermatophyte involvement. The spread of lesions from one body site to adjacent areas and the absence of response to conventional topical and oral antifungal therapy reinforced the likelihood of a fungal aetiology rather than eczema or psoriasis. The distribution of lesions on extremities and groin, together with the progressive course over months, matched the typical pattern of tinea Corporis. Considering this constellation of signs morphology, symptom modalities, pattern of progression, and poor response to previous antifungal treatment the diagnosis of tinea Corporis was confirmed.

Fig 1: Before Treatment

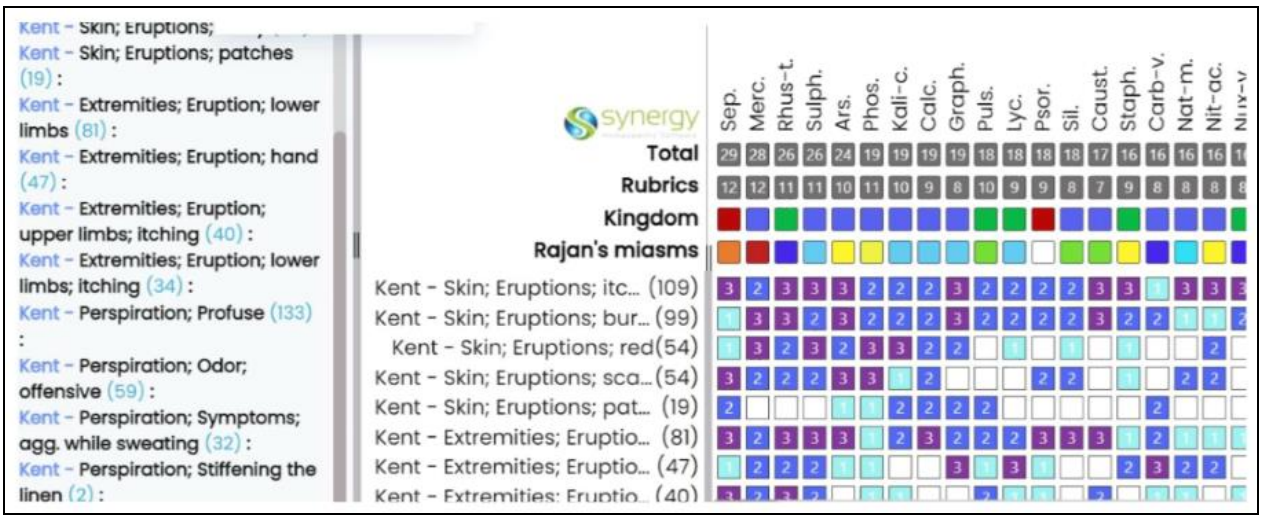

Fig 2: Repertory Sheet

Therapeutic Intervention

A single homoeopathic remedy, Sepia officinalis 200C, was prescribed in the dose of four pills thrice daily for seven days, selected based on the patient's characteristic general features, thermal state, perspiration pattern, irritability, craving for sweets, and modalities.

Auxiliary Measures Advised

- Maintain hygiene and keep affected area dry
- Avoid occlusive or tight clothing
- Do not share towels or personal garments
- Wash clothes and bed linen frequently
- Avoid scratching

Follow-up and Outcomes

First Follow-up (Day 7)

Marked reduction in itching and erythema; scaling decreased. Sac Lac- 4 pills to be taken three times in a day was prescribed for 15 days.

Second Follow-up (Day 22)

Further reduction in itching, healing of lesions, and no new eruptions. Sac Lac- 4 pills to be taken three times in a day was prescribed for 15 days.

Further follow-up
Subsequent monitoring indicated continued improvement without recurrence.

Fig 3: After Treatment

Discussion
Recurrent dermatophytosis has become increasingly challenging due to antifungal resistance, environmental factors, and corticosteroid misuse.[3, 6] This patient experienced no sustained relief despite conventional antifungal therapy. Under homoeopathic treatment, however, he showed rapid and steady improvement.

Sepia officinalis corresponds well to individuals who are hot-blooded, irritable, prefer company, perspire offensively, and crave sweets—features seen clearly in this patient.[7] Constitutional treatment may help reduce susceptibility and thereby enhance recovery. Case reports and observational studies have documented similar benefits of individualised homoeopathy in dermatological conditions.[8, 9, 10] Further controlled trials are needed to evaluate efficacy systematically.

Conclusion
This case demonstrates notable improvement in chronic tinea Corporis following individualised homoeopathic treatment after failure of standard antifungal therapy. Homoeopathy may serve as a valuable complementary modality in chronic or recurrent dermatophytosis, provided it is used with proper clinical evaluation and hygiene practices.

Conflict of Interest
Not available

Financial Support
Not available

References
1. Hay RJ, Ashbee HR. Fungal infections. In: Griffiths C, Barker J, Bleiker T, *et al*., editors. Rook's Textbook of Dermatology. 9th ed. Wiley-Blackwell; c2016.
2. Ely JW, Rosenfeld S, Seabury Stone M. Diagnosis and management of tinea infections. Am Fam Physician. 2014;90(10):702-710.
3. Verma SB, Madhu R. The great Indian epidemic of superficial dermatophytosis. Indian J Dermatol. 2017;62(3):227-236.
4. Hahnemann S. Organon of Medicine. 6th ed. New Delhi: B Jain Publishers; 2011.
5. Gupta AK, Cooper EA. Update in antifungal therapy of dermatophytosis. Mycopathologia. 2008;166:353-367.
6. Narang T, Dogra S, Kaur I. Relapse patterns in tinea corporis and cruris in North India. J Fungi. 2021;7(5):381.
7. Boericke W. Pocket Manual of Homoeopathic Materia Medica. 9th ed. New Delhi: B Jain Publishers; 2007.
8. Oberbaum M, Singer SR. Homoeopathy in dermatology. Dermatol Ther. 2003;16(2):134-140.
9. Lamba CD, Gupta V, Vanhaso L, *et al*. Individualised homoeopathy in dermatological conditions: an observational study. Homeopathy. 2018;107:186-193.
10. Chakraborty D, *et al*. Psoric skin manifestations and their homoeopathic management. Indian J Res Homoeopathy. 2015;9(2):75-82.

How to Cite This Article
Kadam SS. A case of Tinea corporis managed with individualised homoeopathic treatment. International Journal of Homoeopathic Sciences. 2025;9(4):1051-1053.

Creative Commons (CC) License
This is an open access journal, and articles are distributed under the terms of the Creative Commons Attribution-NonCommercial-ShareAlike 4.0 International (CC BY-NC-SA 4.0) License, which allows others to remix, tweak, and build upon the work non-commercially, as long as appropriate credit is given and the new creations are licensed under the identical terms.