



International Journal of Homoeopathic Sciences

E-ISSN: 2616-4493
P-ISSN: 2616-4485
Impact Factor (RJIF): 5.96
www.homoeopathicjournal.com
IJHS 2025; 9(4): 1101-1103
Received: 23-09-2025
Accepted: 22-10-2025

Dr. Vikas Singhal
Chandigarh Director, Dr. Singhal
Homeo, Director, Homeo Saga
Pvt. Ltd., Chandigarh, India

A cured cases study of ankylosing spondylitis HLAB 27 positive: Homeopathic management

Vikas Singhal

DOI: <https://www.doi.org/10.33545/26164485.2025.v9.i4.Q.2045>

Abstract

Ankylosing spondylitis (AS) is an inflammatory arthritis greatly associated to the existence of the human leukocyte antigen B27 (HLA-B27) gene variant. It may cause discomfort, stiffness, and potential spinal fusion. It typically starts in the lower back and pelvis before progressing to other spine areas. There are many conditions which include immune system dysfunction and hereditary susceptibility, may also leads to ankylosing spondylitis. In this paper we have discussed a case study in which we have cured ankylosing spondylitis using homeopathy.

Keywords: Ankylosing Spondylitis (As), B27 (HLA-B27), spine, arthritis, homeopathy

Introduction

As ankylosing spondylitis progresses, the body forms new bone in an effort to heal inflamed areas. The new bone gradually bridges the gaps between vertebrae and eventually fuses sections of vertebrae together. Fused vertebrae can flatten the natural curves of the spine, which leads to stiffness and a hunched posture. It's a type of axial spondyloarthritis.

Symptoms can come and go over time. Some people have periods of increased pain and stiffness, followed by times when symptoms improve or go away for a while. AS is the archetype of a heterogeneous group of arthritis's within the rheumatic diseases known formerly as the seronegative spondyloarthropathies but now frequently referred to as spondyloarthritis (SpA). In addition to axial arthritis, AS can result in peripheral arthritis, enthesitis, and uveitis, all shared characteristics of the SpA.

The prevalence of this disease is 0.1% to 0.8% worldwide. The exact cause behind the autoimmune mechanism of this disease is not known but a strong association has been found with the gene HLA-B27. Male preponderance is marked (10:1) in AS. Onset is commonly observed between the ages of 20 to 30 years.

Symptoms of Ankylosing Spondylitis

- Back pain, usually most severe at night during rest.
- Early morning stiffness.
- Stooped posture in response to back pain.
- Straight and stiff spine.
- Lack of ability to take a deep breath.
- Appetite loss.
- Weight loss.
- Fatigue.
- Fever.
- Anaemia.
- Joint pain.
- Mild eye inflammation.
- Organ damage, such as to the heart, lungs, and eyes.
- Skin rashes.
- Digestive illness.

Corresponding Author:
Dr. Vikas Singhal
Chandigarh Director, Dr. Singhal
Homeo, Director, Homeo Saga
Pvt. Ltd., Chandigarh, India

Ankylosing Spondylitis Diagnoses

- Health history and physical exam
- X-ray
- ESR or SED rate
- Genetic testing

Complications Ankylosing Spondylitis

- Deterioration of the bones.
- Spinal fractures
- Heart and blood vessels related complications.

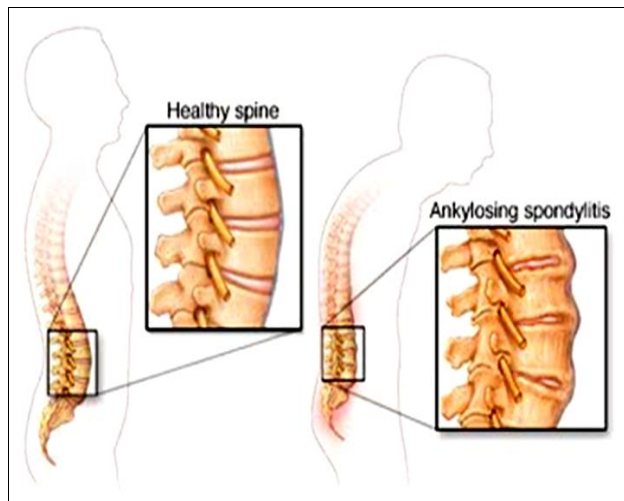


Fig 1: Image of Ankylosing Spondylitis

Homeopathic management of Ankylosing Spondylitis

The best time to begin homeopathic treatment of Ankylosing Spondylitis very early stage of the disease. Homeopathy is a safe method of treatment for May illness as it has no side effects. The homeopathy treatment is based on the person's individual identity and the medicines prescribed for different persons as different as it depends on the persons mental and physical conditions.

Case Study

- **Age:** 29 years.
- **Gender:** Male

Finding after CT scan

- Clinical information at time of scan-lower back pain x 1 month.
- Lumbar lordosis is maintained.
- Vertebral height, signal and alignment are maintained.
- No significant disc bulges / herniations are seen.
- Visualized cord and conus appear normal in MR signal intensity and morphology.

Thecal sac and cauda equina roots appear normal. No obvious compression of nerve roots in lateral recess or neural foramina.

- No gross para-spinal soft tissue abnormality seen.
- Facet joints show no significant abnormality.

Screening rest of spine revealed early cervico-dorsal spondylosis with multilevel grade II disc degeneration. Disc bulges / protrusions are seen at few cervical levels causing mild thecal sac indentation.

- **Impression:** No other significant abnormality seen.

Screening of bilateral sacroiliac joints

There is evidence of patchy areas of STIR hyperintense signal suggestive of marrow edema noted along sacral as well as iliac aspect of right sacroiliac joint inferiorly suggestive of right sacroiliitis with slight signal in right sacroiliac joint space.

- **Impression:** Right sacroiliitis as described.

Treatment

We started this case in the year 2020 during the time of COVID-19.

And now after 4 and half years of treatment patient is totally symptoms free, he has already written a Google review for this, and we are also attaching a video as a final proof.

Various medicines were used during the treatment but here it is important to mention that this was a classical homeopathic treatment means one single medicine at one single point of time.

Medicines prescribed during treatment

Only 4 medicines were used in this whole treatment

- Sulphur.
- Calcarea carb.
- Lycopodium.
- Thuja.

These medicines given in different potencies first in 50 Millesimal scale LM Potency and then decimal scale.

Sulphur 0/2 every day for first month. Followed by sulphur 200 for next 5 months one dose every month plus one sac lac dose twice a day. We have changed the medicines after 6 months to calcarea carb 0/2 every day for the first month followed by calcarea carb 200 for next 8 month as one dose every month plus one sac lac dose twice a day. Till April 30th, 2022.

Thuja 10 m one dose of 5 drops was given on 2nd May 2022. As an intercurrent medicine due to history of gonorrhoeal infection of HPV Followed by calcarea carb 1m for next 15 months as one dose every month plus one sac lac (sbr) twice a day till July 2023.

Thuja 10 m one dose of 5 drops was given on 7th August 2023 as an intercurrent medicine due to history of gonorrhoeal infection of HPV. Followed by calcarea carb 10m for next 18 months as one dose every month plus one sac lac twice a day till December 2024. As per the changed to totality of symptoms in January 2025 lycopodium 1m was given monthly one dose for 7 months followed by sac lac twice a day till July 2025.

Conclusion

From these four and a half years of study we can conclude that if proper Diagnoses and patients' physical examination are done properly and then the medicines are prescribed based on the symptoms and individual's characteristics than Ankylosing spondylitis can be cured using homeopathic medicine.

Bibliography of author

Dr. Vikas Singhal is a classical homeopath with over two decades of experience, treating patients from 70+ countries. He is Director, Homeo Saga Pvt. Ltd. He is also Director at Dr. Singhal Homeo Clinc. His expertise in managing chronic viral and autoimmune disorders, including HPV-related and syphilitic infections, reflects the power of

homeopathy as a holistic, natural system of healing. He is one of the best Homeopathic Physicians to treat acute & chronic, recurring, autoimmune, and resistant diseases in the Tricity and India. He is offering treatment for rheumatoid arthritis, Ulcerative Colitis, Vitiligo, Ankylosing spondylitis, Psoriasis, Osteomyelitis, and various rare diseases considered incurable in other systems of medicines to Indian Patients and patients from different parts of the world. Dr. Singhal is known for his individualized, evidence-based approach to treatment. His commitment to evidence-based, classical homeopathic practice has earned him respect and recognition which also earned him several honors and awards for his selfless service to human being,

he is the recipient of prestigious Bharatshri Award (2025). Dr. Singhal is a Life Member of leading professional bodies like the Indian Institute of Homeopathic Physicians (IIHP), Akhil Bhartiya Chikitsak Association (ABCA), Liga Medicorum Homoeopathica Internationalis (LMHI), and the Australian Homeopathic Association (International Allied Member Practitioner). He is also an Honorary Physician at Tiny Tots Preparatory School, Chandigarh. Dr Singhal is a well-known speaker at various national and international seminars and conferences. His channel is very popular named as Homeo Doctor, <https://youtube.com/@homeodoctor?si=gAG2li49yCKrOr0k>.

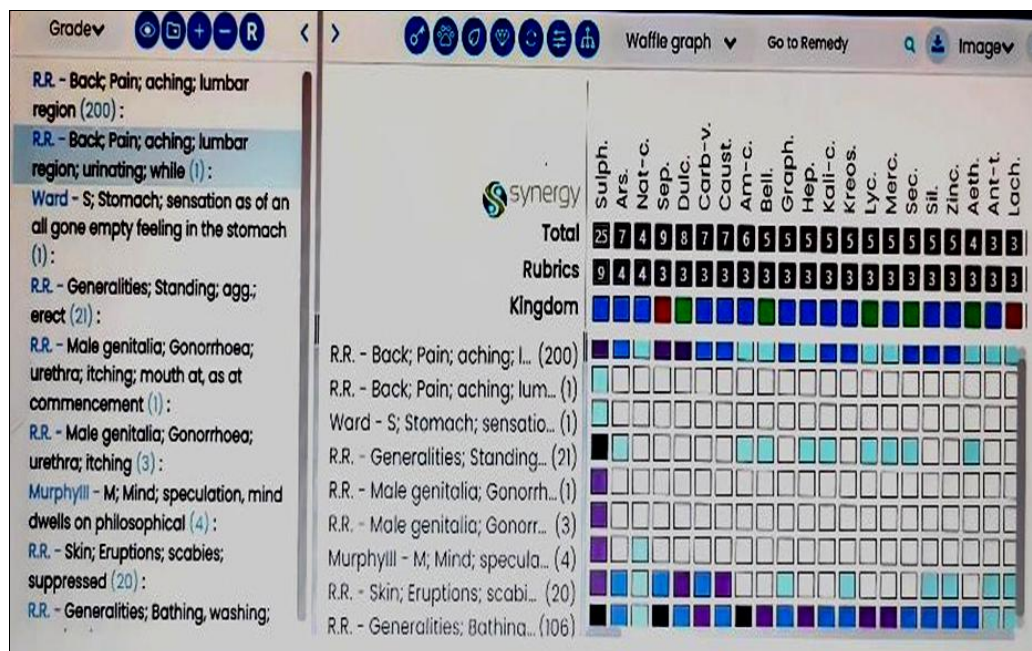


Chart 1: Chart of Medicines prescribed and relief achieved

Conflict of Interest: Not available

Financial Support: Not available

References

- Dwivedi AK. Arthritis and its treatment using homeopathy and yoga. *Paripex Indian J Res.* 2020;9(1). DOI: 10.36106/paripex.
- Vaishampayan N. Homoeopathic management of ankylosing spondylitis. *Int J Homoeopathic Sci.* 2020;4(4):132-134.
- Haslock I, Monro R, Nagarathna R, Nagendra HR, Raghuram NV. Measuring the effects of yoga in rheumatoid arthritis. *Br J Rheumatol.* 1994;33:787-788.
- Garfinkel MS, Schumacher HR Jr, Husain A, Levy M, Reshetar RA. Evaluation of a yoga-based regimen for treatment of osteoarthritis of the hands. *J Rheumatol.* 1994;21:2341-2343.
- Dash M, Telles S. Improvement in hand grip strength in normal volunteers and rheumatoid arthritis patients following yoga training. *Indian J Physiol Pharmacol.* 2001;45:355-360.
- Boericke W. *Materia Medica.*
- Boericke W. *Boericke's new manual of homeopathic materia medica with repertory.* 3rd rev & augmented Ed.
- Fauci AS, Kasper DL, Longo DL, *et al.*, editors. *Harrison's Principles of Internal Medicine.* 17th Ed.
- Davidson's Principles and Practice of Medicine.
- Kent JT. *Repertory of Homoeopathic Materia Medica.*
- Dubey SK. *Textbook of Materia Medica.*
- Choudhari NM. *A study on Materia Medica.*
- Boericke W. *Pocket Manual of Homoeopathic Materia Medica & Repertory.*
- Allen HC. *Keynotes and characteristics with comparisons of some leading remedies of the Materia Medica with bowel nosodes.* 8th Ed.
- Uniyal P, Kinra R. *Materia Medica for Students.*

How to Cite This Article

Singhal V. A cured cases study of ankylosing spondylitis HLAB 27 positive: Homeopathic management. *International Journal of Homoeopathic Sciences.* 2025;9(4):1101-1103.

Creative Commons (CC) License

This is an open-access journal, and articles are distributed under the terms of the Creative Commons Attribution-Non Commercial-Share Alike 4.0 International (CC BY-NC-SA 4.0) License, which allows others to remix, tweak, and build upon the work non-commercially, as long as appropriate credit is given and the new creations are licensed under the identical terms.