



International Journal of Homoeopathic Sciences

E-ISSN: 2616-4493
P-ISSN: 2616-4485
Impact Factor (RJIF): 5.96
www.homoeopathicjournal.com
IJHS 2025; 9(4): 1490-1499
Received: 19-09-2025
Accepted: 23-10-2025

Dr. Vikas Singhal
Director, Dr. Singhal Homeo;
Director, Homeo Saga Pvt.
Ltd., Chandigarh, India

Completely cured case of keloid (hypertrophic burn scar): Homeopathic treatment of a 9-year-old boy

Vikas Singhal

DOI: <https://www.doi.org/10.33545/26164485.2025.v9.i4.W.2106>

Abstract

Introduction: Keloid (in this case, caused by hypertrophic burn scars) is a dermal fibro proliferative disorder characterized by abnormal wound healing and collagen deposition.

Globally, around twenty lakh (20,00,000) people suffer burn injuries every year, of which more than one lakh (1,00,000) people lose their lives. In India alone, cases of burn injuries remain around sixty thousand (60,000) annually. Of these, more than 50,000 receive hospitalization and adequate treatment, while approximately 10,000 people die as a result of thermal injury, which constitutes one of the major causes of accidental deaths in India.

Burn injuries may also leave the person vulnerable to prolonged morbidity and both temporary and permanent disability. This often leads the sufferer and their family to a considerable economic burden. Besides the burn wounds and any short or long-term complications arising as a result of the same, burn scars present many individuals with various complications, including impaired function, restricted joint mobility, and growth, altered physical appearance, and psychological distress.

Hypertrophic scarring (HSc) post-burns remains a common challenge among such individuals. What is concerning here is that though HSc is almost certain after a burn injury, the treatment options still remain limited. While most HSc patients will receive some form of pressure garments as a treatment strategy, it is rarely found to work.

On the other hand, at times, Homeopathy has proven to be effective in managing not just short-term but long-term scarring, that is, hypertrophic burn scars. Homeopathic remedies such as *Causticum*, *Carbolic acidum*, *Arnica*, and *Staphysagria* have shown notable effects on wound healing and the cicatrization process.

Cicatrization (also spelled cicatrization) refers to the process of wound healing through the formation of scar tissue, which involves:

- Closure of a wound by the growth of new connective tissues (mainly collagen).
- Replacement of damaged skin with fibrous scar tissue.

This leaves the area with a visible scar called a hypertrophic burn scar. When these scars continue growing and extend beyond the affected wound area, they are referred to as keloids.

This case report highlights the positive results and, therefore, the role of the homeopathic medicine *Causticum* in treating post-burn HSc and keloids, demonstrating a visible reduction in the scar. This case report also serves to document the effectiveness and clinical value of homeopathy in managing post-burn scarring. New and continued reporting of such outcomes can help compile a comprehensive, evidence-based database to support the fact that Homeopathy can treat HSc and Keloids and will also help with more structured future research in this field.

Case summary: A 4 year and 11 month old male child presented in March 2021 with extensive keloid masses and scarring below the abdomen after accidentally falling in a tub of hot water. Having a second degree burn around the right waist, inner thigh, groin, and penis areas, the patient was subjected to allopathic treatments in the beginning and an eight month course of homeopathic treatment. Not getting any satisfactory results, the patient was then brought to Dr. Vikas Singhal for classical individualized homeopathic treatment. Here, as per the Repertorisation Chart indicating the Similimum Medicine as *CAUSTICUM*, the patient received treatment with *Causticum* in 1M - CM, followed by *Bacillinum* 10M as intercurrent medicine and ultimately *Thiosinaminum* 6X tablets to improve the affected skin coloration to conclude the treatment.

Keywords: Keloid, hypertrophic burn scars, dermal fibroproliferative, burn injuries, collagen deposition, restricted joint mobility, cicatrization and homeopathy, skin, wounds, homeopathic treatment of keloid etc.

Introduction

A Brief Introduction to Keloids & Their Conventional Management

Keloids, including hypertrophic burn scars, are benign (non-cancerous) overgrowths of fibrous tissue caused by abnormal wound healing and excessive collagen production. Unlike normal scars, they extend beyond the initial boundaries of a wound and involve deeper layers

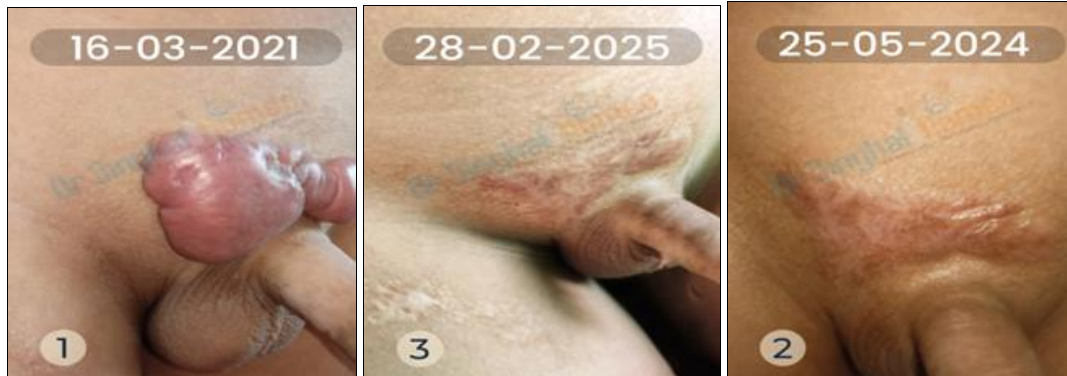Corresponding Author:
Dr. Vikas Singhal
Director, Dr. Singhal Homeo;
Director, Homeo Saga Pvt.
Ltd., Chandigarh, India

of the skin, that is, both the epidermis as well as the dermis. This often leads to chronic inflammation, cosmetic distortion, and significant psychosocial impact. Their occurrence is more frequent in younger individuals and those with darker skin tones.

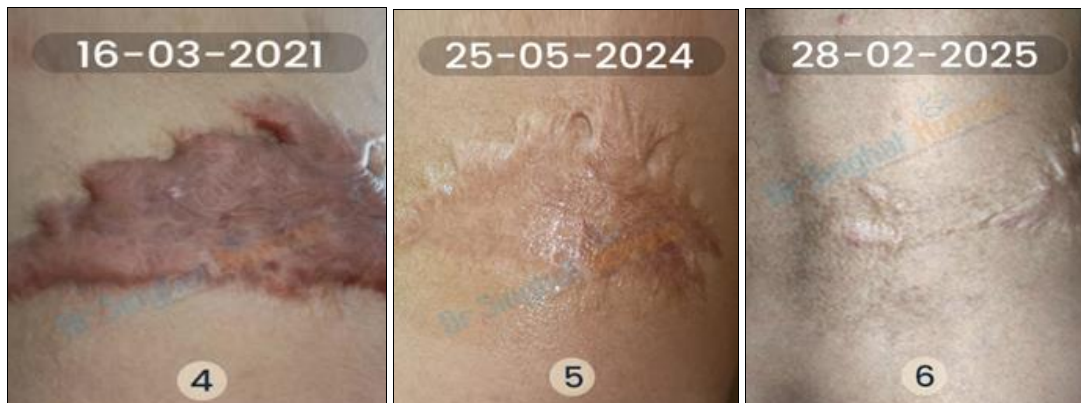
Conventional treatment methods such as intralesional corticosteroids, silicone gel sheets, cryotherapy, laser therapy, and surgical excision are commonly used to manage keloids. However, the results are generally temporary, and the keloids and HSc tend to come back again and again. Moreover, such invasive and harsh treatments are not ideal for younger patients, including kids.

Patient Information

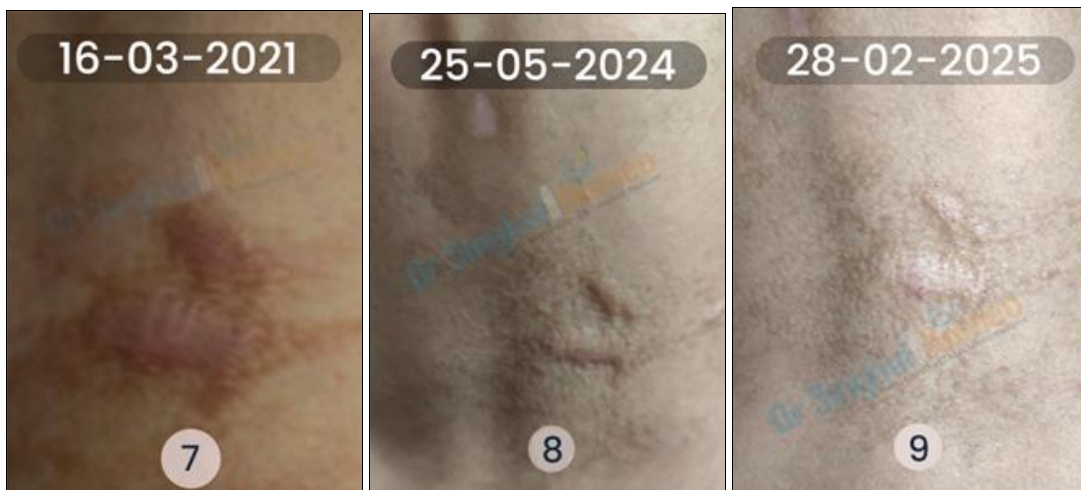The case includes a 4 year and 11-month-old male child who fell into a tub of hot water suffering second degree burns around the lower abdomen, right waist, inner thigh, groin, and penis. The masses later developed into hypertrophic burn scars, that is keloid, over a time period of approximately 3 months, between 25th April 2020 and 24th July 2020. The boy underwent allopathic treatment as a first line of intervention between April 25th, 2020, and March 5th, 2021. The patient's parents also put him to Homeopathic treatment from another clinic in Chennai, Tamil Nadu, between August 1st, 2020, and March 13th, 2021.



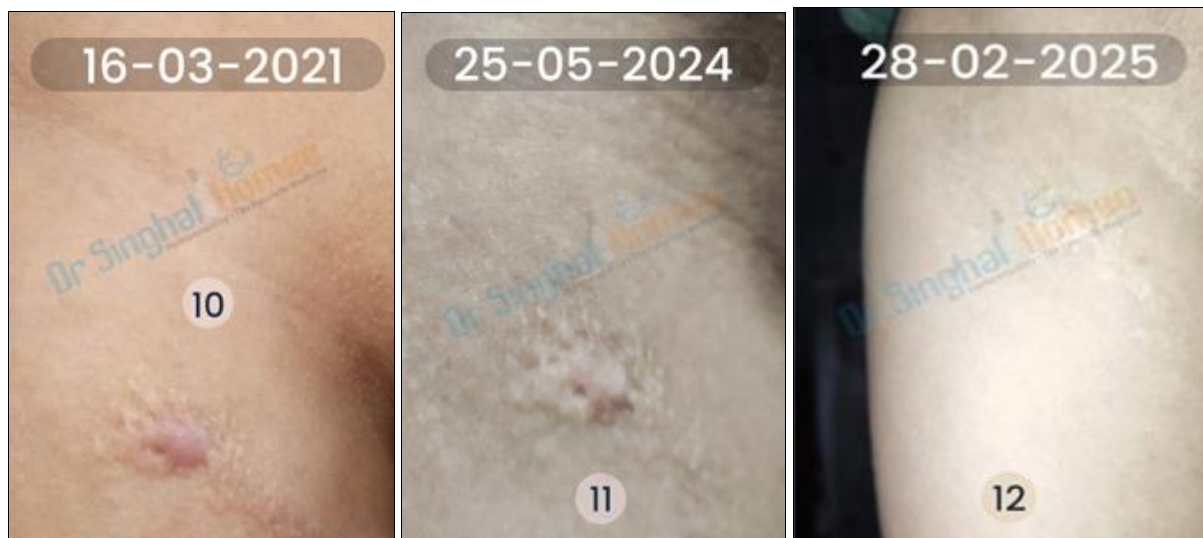
1. Large keloid mass above penile area, 2. Regressing keloid above penile, 3. Keloid above penile area getting normalised



4. Large keloid mass on the right waist, 5. Regressing keloid mass on the right waist, 6. Keloid mass on the right waist getting normalised



7. Keloid mass on the right side of the lower back, 8. Regressing keloid mass on the right side of the lower back, 9. Keloid mass on the right side of the lower back getting normalised



10. Keloid mass on the inner side of the right thigh, **11.** Regressing keloid mass on the inner side of the right thigh, **12.** Keloid mass on the inner side of the right thigh getting normalised

The allopathic treatment included management of the patient's burn wounds by dressing with Silver Sulfadiazine topical ointments. Antibiotics used included Amoxicillin trihydrate (500 mg) and Clavulanic acid (125 mg) combination and Piperacillin (4000 mg) and Tazobactam (500mg) injection, and vancomycin IV. This treatment regimen continued for five (5) days, including IV fluid infusion. Initial results were promising with good recovery and near-complete epithelization (the process of a wounded part developing a new epithelial tissue layer) of the affected skin.

For the next five (5) days, the patient was given Multivitamin syrup 2.5 ml with Ranitidine syrup 5 ml both twice a day. Concomitant coconut oil application on the epithelized skin was also done along with alternate-day dressing.

Post-Allopathic Treatment

Despite showing promising results with the initial allopathic treatments, the problem later developed into hypertrophic burn scars, that is, keloids. It found no definitive and effective treatment in the allopathic system and required an alternative approach.

Clinical Findings by the Previous Doctor

Post-injury caused by hot water burn, the patient was brought to the Armed Forces' Command Hospital on April 25th, 2020. The patient was initially diagnosed with second (2nd) degree burns and was subjected to allopathic treatment including topical dressing and oral antibiotic medications along with fluid infusions intravenously.

On a successive visit in armed forces command hospital, when the regular treatment didn't work, the patient got diagnosed with hypertrophic burn scars, that is, keloid. The patient underwent allopathic treatment including long-acting oral antibiotic medications along with Silicon Gel Sheet applications. This continued until March 5th, 2021.

The problem only aggravated and needed another, more effective and potentially, alternative treatment approach.

Clinical Findings by Dr. Vikas Singhal

The patient's first visit at our clinic was on March 22nd, 2021.

We observed HBSc (Hypertrophic burn scars) keloids on different parts of the body including the area above the penis, on the side of the right thigh, right side of the abdomen (iliac area), and on the lower back.

We observed keloid in the following terms, as per the internationally approved VSS chart:

- Height: 5-8 mm
- With contracture (permanent shortening of scar producing deformity or distortion)
- Vascularity to reddish purple
- Hyperpigmentation

Physical generals of the patient

On first instance

- Itching on skin ++
- Appetite ++
- Thirst - Normal
- Stool - Habitually constipated
- Anemia ++
- Pallor ++
- Sleep - Normal
- Position sleep during sidewise
- Dreams - None
- Urine - Normal
- Perspiration - Normal

Mental generals of the patient

On first instance

- Weeping - tearful mood
- Weeping trifles at
- Despair of recovery +++
- Melancholy +++
- Timidity ++
- Nervousness ++
- Anxiety +
- Reticent +++ (due to long-lasting grief of burn ailments)

Table 1: Vancouver Scar Scale score progression

Sign/Symptoms	Score at Entry (22-03-21)	2nd Visit (24-07-21)	3rd Visit (26-11-21)	4th Visit (01-10-22)
Pigmentation	Hyperpigmentation (3)	Hyperpigmentation (3)	Hyperpigmentation (3)	Hyperpigmentation (1)
Height	> 5 mm (3)	> 5 mm (3)	> 5 mm (3)	2-5 mm (2)
Pliability	Contracture (5)	Ropes (4)	Firm (3)	Yielding (2)
Vascularity	Purple (3)	Purple (3)	Purple (3)	Red (2)
Itchy Sensation	Severe (3)	Severe (3)	Occasional itching (2)	Occasional itching (2)
Patient's Total VSS Score	17	16	14	9
Treatment Schedule	<i>Causticum</i> 1 M - OD For the first 3 days followed by <i>Sachharum lactis</i> 0/X for 60 days	<i>Causticum</i> 1 M - OD For the first 3 days followed by <i>Sachharum lactis</i> 0/X for 60 days	<i>Causticum</i> 1 M - OD For the first 3 days followed by <i>Sachharum lactis</i> 0/X for 60 days	<i>Causticum</i> 1 M - OD For the first 3 days followed by <i>Sachharum lactis</i> 0/X for 60 days

Sign/Symptoms	5th Visit (03-02-23)	6th Visit (05-06-23)	7th Visit (04-02-24)	8th Visit (04-01-25)
Pigmentation	Hypopigmentation (1)	Hypopigmentation (1)	Normal (0)	Normal (0)
Height	< 2 mm (1)	< 2 mm (1)	Flat (0)	Flat (0)
Pliability	Yielding (2)	Supple (1)	Supple (1)	Normal (0)
Vascularity	Pink (1)	Pink (1)	Normal (0)	Normal (0)
Itchy Sensation	Occasional itching (2)	Sometimes itching (1)	Sometimes itching (1)	No itching (1)
Patient's Total VSS Score	7	5	2	0
Treatment Schedule	<i>Causticum</i> 1M - OD For the first 3 days followed by <i>Sachharum lactis</i> 0/X for 60 days	<i>Causticum</i> 10M - OD For the first 3 days followed by <i>Sachharum lactis</i> 0/X for 60 days	<i>Causticum</i> 50M - OD For the first 3 days followed by <i>Sachharum lactis</i> 0/X for 60 days	<i>Causticum</i> CM - OD For the first 3 days followed by <i>Sachharum lactis</i> 0/X for 60 days <i>Thiosinaminum</i> 6X 250mg chewable tablets - 2 tablets daily in the morning

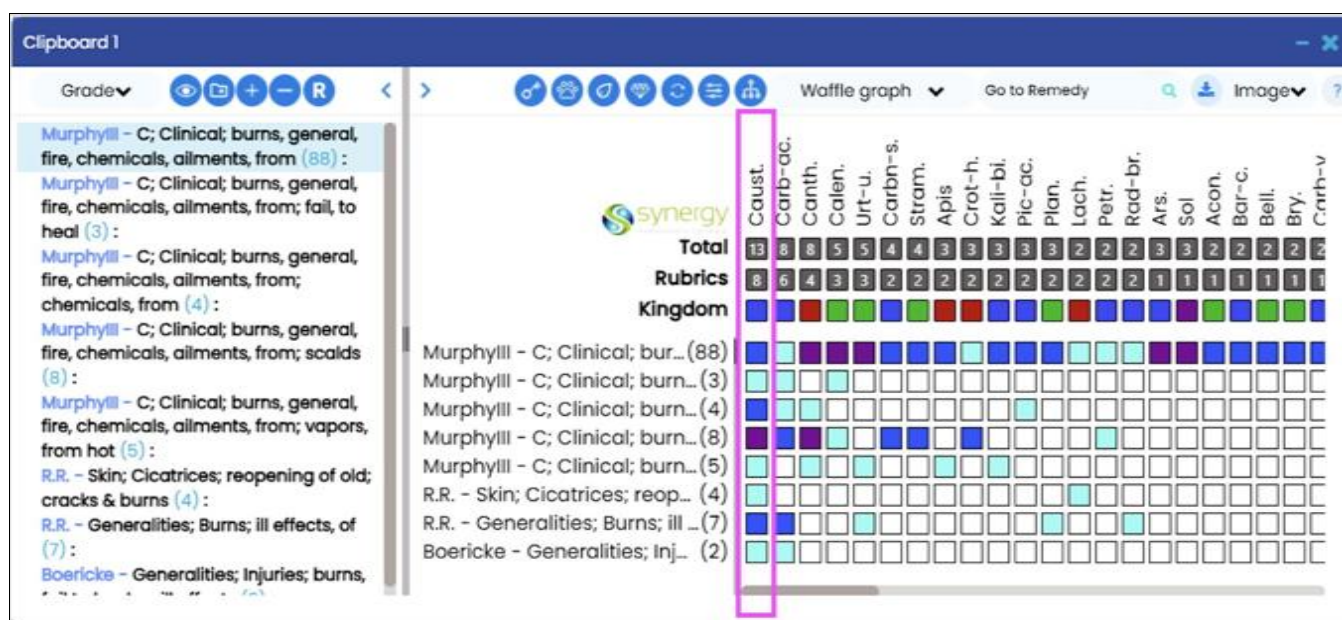
*OD: Once daily, VSS: Vancouver Scar Scale

Homeopathic Therapeutic Intervention

- As Per Individualized Case Taking & Classical individualized Homeopathy
- Case Analysis and Repertorisation for hypertrophic burn scar - keloids, was done using the Synergy Homeopathic Software, in which the Repertorisation

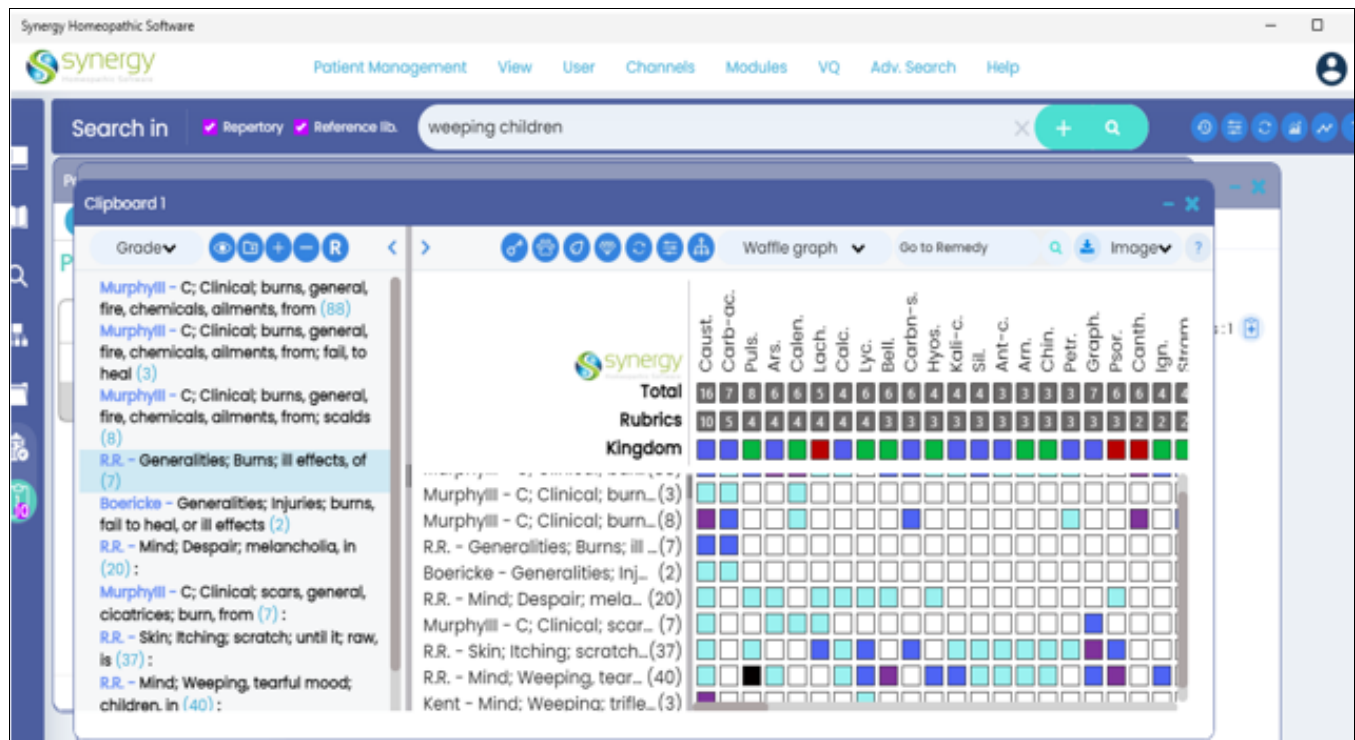
Chart indicated the Similimum Medicine as *CAUSTICUM*.

- Below are the Repertorisation charts 1 and 2, showing the remedy of choice for the case:

Chart-1Repertorisation Chart: Indicating the Similimum Medicine as *CAUSTICUM*

Courtesy - Synergy Homeopathic Software

Chart-2



Repertorisation Chart: Indicating the Similimum Medicine as CAUSTICUM
Courtesy - Synergy Homeopathic Software

The following rubrics were selected for Repertorisation

- Generalities - Burn - ill effects, of
- Generalities - Burn- general - fire chemical Ailments from
- Generalities - Burn - general fire chemical hot vapours
- Skin - Cicatrices - reopening of old cracks & burns
- Skin - Itching - scratch until it, raw, is
- Mind - Weeping - tearful mood, children, in
- Mind - Despair, Melancholia in children
- Mind - weeping trifles at

Camille McClellan: *Causticum*, as noted by renowned homeopath Camille McClellan, is a complex remedy derived from a chemical reaction between slaked lime (calcium sulfate) and potassium hydroxide. This reaction produces a caustic, alkaline compound that, in its raw form, can cause skin burns, irritation, and tissue corrosion symptoms that closely resemble hypertrophic burn scars and keloids. According to the homeopathic principle - the 'law of similars', a substance capable of producing such effects

in its crude form is well-suited to treat similar manifestations in a diseased state. This symptomatic correspondence, combined with *Causticum's* historical use in chronic wounds and deep burns, makes it a fitting remedy for managing stubborn post-burn scarring and keloid formations.

For chronic longstanding cases like keloids, patience is key. During the whole course of treatment, the doctor kept on encouraging the patient's parents to continue the medicines and keep track of the progress, as the recovery in such cases can be extensively slow yet complete. The patient's parents were also very cooperative and kept taking the treatment patiently and followed the instructions given by the doctor alongside the medications, which ultimately resulted in the complete recovery of the patient.

A detailed case history was elicited. No ointments or external applications were prescribed at any stage. Based on constitutional totality, *Causticum* was prescribed initially. Subsequently, on 04-12-2024, *Thiosinaminum* 6X 250 mg tablets were given to target the skin discoloration issue.

Table 2: Follow-up & Outcomes

Prescription Date/ Duration	Present Symptoms	Intervention	Results
22-03-2021 - 22-05-2021	Hypertrophic burn scars, with large keloid masses around waist, back, lower abdomen and above the penis and the right thigh	<i>Causticum</i> 1 M - OD For the first 3 days followed by <i>Sachharum lactis</i> 0/X for 60 days	First visit and prescription, followup done in successive prescription
23-05-2021 to 23-07-2021	Large keloid masses around waist, back, lower abdomen and above the penis and the right thigh	<i>Causticum</i> 1 M - OD For the first 3 days followed by <i>Sachharum lactis</i> 0/X for 60 days	Patient getting better, medicine repeated
24-07-2021 to 24-09-2021	Keloid masses around waist, back, lower abdomen and above the penis and the right thigh	<i>Causticum</i> 1 M - OD For the first 3 days followed by <i>Sachharum lactis</i> 0/X for 60 days	Patient getting better, medicine repeated
25-09-2021 to 25-11-2021	Keloid masses around waist, back, lower abdomen and above the penis and the right thigh	<i>Causticum</i> 1 M - OD For the first 3 days followed by <i>Sachharum lactis</i> 0/X for 60 days	Patient getting better, medicine repeated

26-11-2021 to 26-01-2022	Keloid masses around waist, back, lower abdomen and above the penis and the right thigh	<i>Causticum</i> 1 M - OD For the first 3 days followed by <i>Sachharum lactis</i> 0/X for 60 days	Patient getting better, medicine repeated
27-01-2022 to 27-03-2022	Keloid masses around waist, back, lower abdomen and above the penis and the right thigh	<i>Causticum</i> 1 M - OD For the first 3 days followed by <i>Sachharum lactis</i> 0/X for 60 days	Patient getting better, medicine repeated
28-03-2022 to 28-05-2022	Keloid masses around waist, back, lower abdomen and above the penis and the right thigh	<i>Causticum</i> 1 M - OD For the first 3 days followed by <i>Sachharum lactis</i> 0/X for 60 days	Patient getting better, medicine repeated
29-05-2022 to 29-07-2022	Keloid masses around waist, back, lower abdomen and above the penis and the right thigh	<i>Causticum</i> 1 M - OD For the first 3 days followed by <i>Sachharum lactis</i> 0/X for 60 days	Patient getting better, medicine repeated
30-07-2022 to 30-09-2022	Masses of keloid scar, smaller than before, however, still present on the same body parts	<i>Causticum</i> 1 M - OD For the first 3 days followed by <i>Sachharum lactis</i> 0/X for 60 days	Patient getting better, medicine repeated
01-10-2022 to 01-12-2022	Smaller keloid masses around waist, back, lower abdomen and above the penis and the right thigh	<i>Causticum</i> 1 M - OD For the first 3 days followed by <i>Sachharum lactis</i> 0/X for 60 days	Patient getting better, medicine repeated
02-12-2022 to 02-02-2023	Smaller keloid masses around waist, back, lower abdomen and above the penis and the right thigh	<i>Causticum</i> 1 M - OD For the first 3 days followed by <i>Sachharum lactis</i> 0/X for 60 days	Patient getting better, medicine repeated
03-02-2023 to 03-04-2023	Smaller keloid masses around waist, back, lower abdomen and above the penis and the right thigh	<i>Causticum</i> 1 M - OD For the first 3 days followed by <i>Sachharum lactis</i> 0/X for 60 days	Patient getting better, medicine repeated
04-04-2023 to 04-06-2023	Smaller keloid masses around waist, back, lower abdomen and above the penis and the right thigh	<i>Causticum</i> 1 M - OD For the first 3 days followed by <i>Sachharum lactis</i> 0/X for 60 days	Patient getting better, medicine repeated
05-06-2023 to 04-08-2023	Smaller keloid masses around waist, back, lower abdomen and above the penis and the right thigh	<i>Causticum</i> 10 M - OD For the first 3 days followed by <i>Sachharum lactis</i> 0/X for 60 days	Patient getting better, medicine changed in potency. Now, higher potency (10M) of <i>Causticum</i> started
05-08-2023 to 04-10-2023	Slightly flattened keloid masses, on the same areas of the body	<i>Causticum</i> 10 M - OD For the first 3 days followed by <i>Sachharum lactis</i> 0/X for 60 days	Patient getting better, medicine repeated
05-10-2023 to 04-12-2023	Flat keloid masses around waist, back, lower abdomen and above the penis and the right thigh	<i>Causticum</i> 10 M - OD For the first 3 days followed by <i>Sachharum lactis</i> 0/X for 60 days	Patient getting much better, medicine repeated
05-12-2023 to 04-02-2024	Flat keloid masses around waist, back, lower abdomen and above the penis and the right thigh	<i>Causticum</i> 10 M - OD For the first 3 days followed by <i>Sachharum lactis</i> 0/X for 60 days	Patient is standstill, medicine repeated
04-02-2024 to 03-04-2024	Flat keloid masses around waist, back, lower abdomen and above the penis and the right thigh	<i>Causticum</i> 50 M - OD For the first 3 days followed by <i>Sachharum lactis</i> 0/X for 60 days	Patient is standstill, therefore, higher potency (50M) of <i>Causticum</i> was given
04-04-2024 to 03-06-2024	Less prominent keloid masses around waist, back, lower abdomen and above the penis and the right thigh	<i>Causticum</i> 50 M - OD For the first 3 days followed by <i>Sachharum lactis</i> 0/X for 60 days	Patient seems to be better than earlier, therefore <i>Causticum</i> 50M was repeated
04-06-2024 to 03-08-2024	Less prominent keloid masses around waist, back, lower abdomen and above the penis and the right thigh	<i>Causticum</i> 50 M - OD For the first 3 days followed by <i>Sachharum lactis</i> 0/X for 60 days	Patient's condition is totally standstill. Therefore, the medicine was repeated
04-08-2024 to 03-10-2024	Less prominent keloid masses around waist, back, lower abdomen and above the penis and the right thigh	<i>Causticum</i> CM -OD For the first 3 days followed by <i>Sachharum lactis</i> 0/X for 60 days	Patient is standstill. Therefore, the medicine potency is changed from 50M to CM.
04-10-2024 to 03-12-2024 18/10/2024 (Intercurrent Remedy - Dose 1)	Seemingly completely flattened keloid masses	<i>Causticum</i> CM -OD For the first 3 days followed by <i>Sachharum lactis</i> 0/X for 60 days <i>Bacillinum</i> 10M - OD	Patient getting better, medicine repeated
04-12-2024 to 03-01-2025	Patient seems to be better but, the keloids are not regressing in size	<i>Causticum</i> CM -OD For the first 3 days followed by <i>Sachharum lactis</i> 0/X for 60 days <i>Thiosinaminum</i> 6X 250 mg chewable tablets - 2 tablets daily in the morning	Patient seems to be better but, the keloids are not regressing in size
04-01-2025 to 03-02-2025	Minor keloid masses visible in the affected areas, with nearly completely vanished scars from the thigh and some parts of the back	<i>Causticum</i> CM -OD For the first 3 days followed by <i>Sachharum lactis</i> 0/X for 60 days <i>Thiosinaminum</i> 6X 250 mg chewable tablets - 2 tablets daily in the morning	Slight change of skin color, indicating normalization, medicine repeated
04-02-2025 to 03-03-2025	Reduced keloid masses with improved skin color	<i>Thiosinaminum</i> 6X 250 mg chewable tablets - 2 tablets daily in the morning <i>Bacillinum</i> 10M - OD	Promising results with visible changes in the skin color of the affected area, medicine repeated

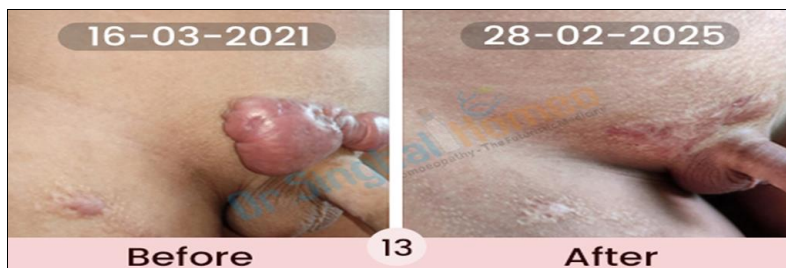01/03/2025 (Intercurrent Remedy - Dose 2)			
04-03-2025 to 03-04-2025	Negligible keloidal masses present	<i>Thiosinaminum</i> 6X 250 mg chewable tablets - 2 tablets daily in the morning	Skin color close to normal
04-04-2025 to 14-05-2025	Only slight scar tissues remaining with no progression	<i>Thiosinaminum</i> 6X 250 mg chewable tablets - 2 tablets daily in the morning	Skin color close to normal with total removal of the keloid scars

Supplements given

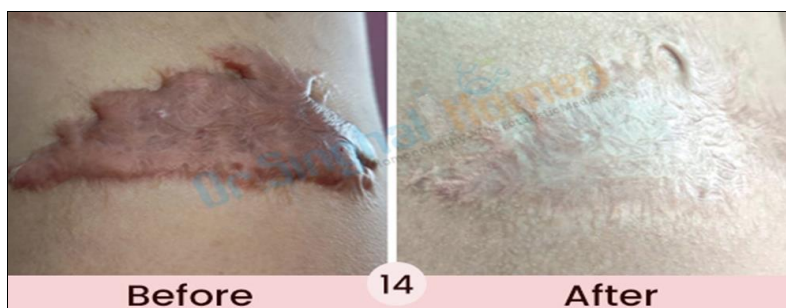
- Vitamin D granules (60k IU) - QW (once a week), throughout the course of the treatment
- Blackstrap Molasses (Organic) - Daily
- Iron supplement - Started in August 2024, targeted to restore haemoglobin deficiency and improve skin coloration. By January 2025, the objective was achieved with normalization of the skin color.

Dietary Restrictions: Fried foods, junk foods, and food items containing artificial additives, like artificial colours, flavours, and preservatives.

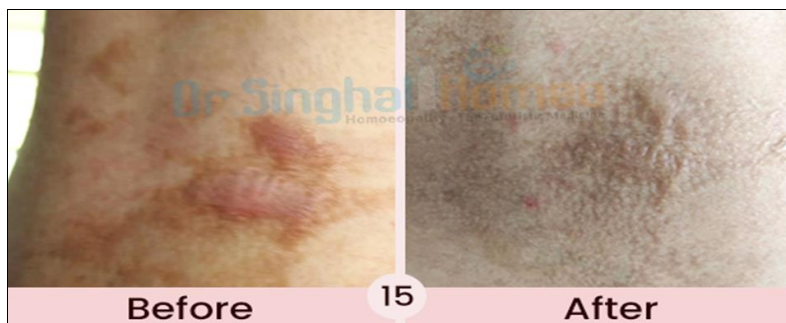
Even after the latest review, dated 14-05-2025, the patient is now fully cured and No Further Medicine for Hypertrophied scars and keloid is required.



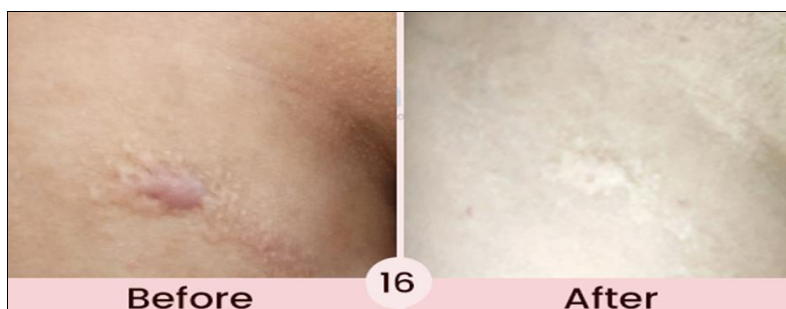Before & after images of keloids on the penile area



Before & after images of keloids on the right waist area

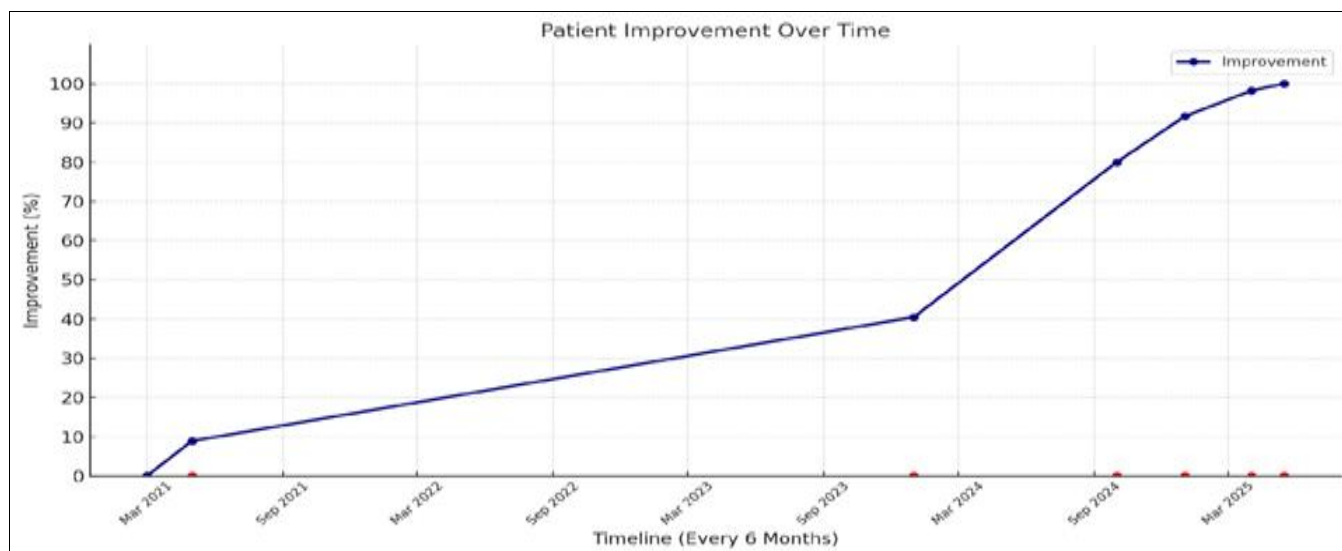


Before & after images of keloids on the right lower back area



Before & after images of keloids on the inner part of the right thigh

The following graph shows the % improvement in the condition of the patient as documented on each successive consultation



Observation Timeline

Improvement Timeline

Progressive homeopathic medicinal intervention by Dr. Vikas Singhal, with successively increasing potencies of *Causticum* followed by the intercurrent remedy - *Bacillinum*, showed visible and promising results in the patient's improvement. Further intervention with *Thiosinaminum* 6X potency improved the skin coloration within just 5 months of initiating the medicine.

- **Inflammation:** Redness significantly decreased.
- **Skin Texture:** Skin began regaining original tone and elasticity.
- **Hemoglobin Levels:** Improved with iron supplementation.
- **Ointments:** None used throughout the course.
- **Aggravation:** No aggravation reported at any stage.

Results

The patient was followed up every 2 months and the VSS score was filled after observation of the scar and measurement of its height. The score reduced from 5 mm - 8 mm (as on different body parts) to 0.00 mm and showed 100% improvement in Tables 1.0 & 1.1. Follow-up schedule is shown in Table 2 as per the VSS score. This result shows the usefulness of the homeopathic medicine *Causticum* in HSc and Keloid. Irritation, redness, and height of the scars are reduced as shown in the before-after images 13-16 after the prescription of *Causticum* compared to the pretreatment stage (images 1-12).

Discussion & Conclusion

This appears to be a well-documented case of hypertrophic burn scars and keloids, showcasing complete remission of pediatric keloids using only classical individualized individualized homeopathic treatment with *CAUSTICUM* as the Similimum Medicine. The treatment model adopted may offer a replicable and safe option for keloid cases and other similar chronic dermatological conditions.

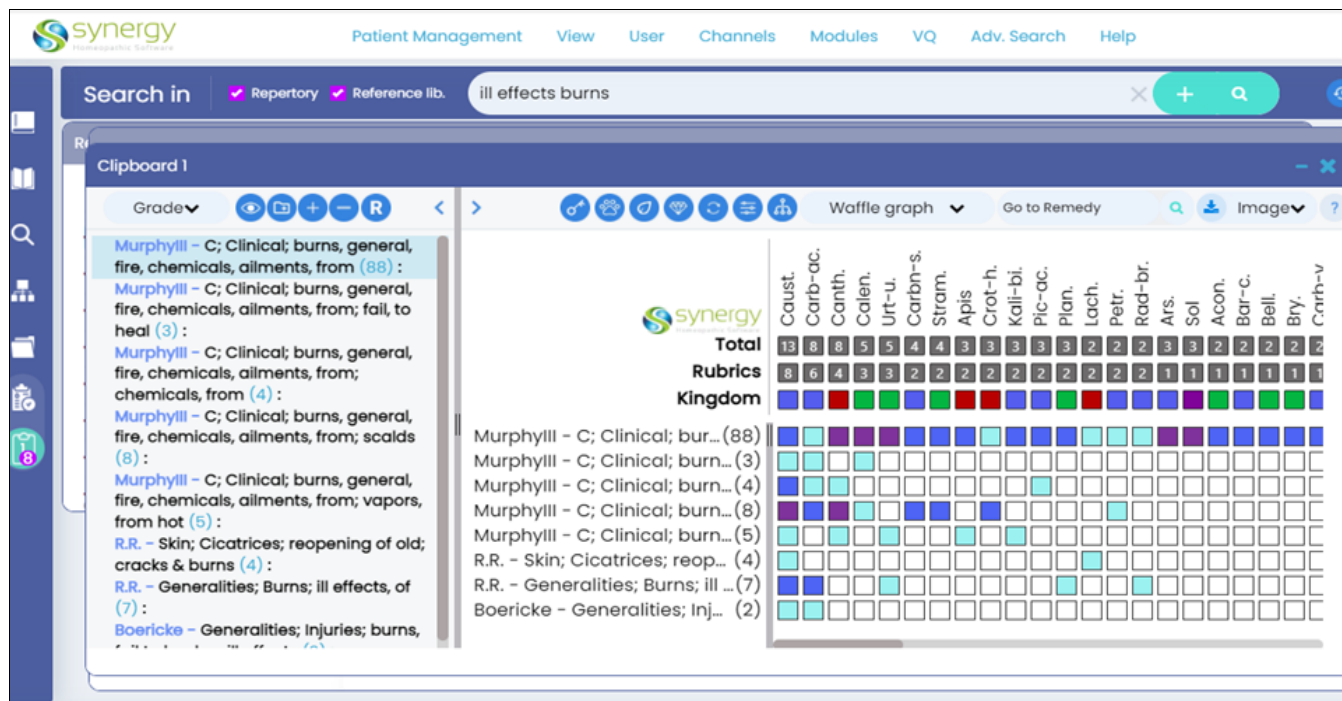
Causticum is a remedy of choice for hypertrophic burn scars and keloids where the characteristic symptoms include contracture of scar tissue, burning or raw sensations, tightness and stiffness of the skin, itching aggravated by

heat or perspiration, and slow wound healing. According to the homeopathic principle of "similia similibus curentur," *Causticum* prepared from caustic alkaline substances known to cause burns and skin irritation in their crude form acts curatively when such symptoms appear in a pathological state, making it a fitting similimum in chronic post-burn scarring and keloidal tissue changes.

In traditional homeopathic materia medica, medicines such as *Graphites*, *Silicea*, *Carbolic acidum*, and *Nitric acidum* are commonly referenced for managing chronic scar tissue. However, this case brings attention to *Causticum* as a particularly effective and often underutilized remedy in post-burn hypertrophic scarring. Derived from chemically reactive alkaline compounds that cause skin corrosion in their raw form, *Causticum* symptomatically mirrors the pathophysiology of keloids and HSc. Its affinity for tissues undergoing fibrotic change, coupled with characteristic burning, contracture, and itching, makes it a highly relevant remedy in such chronic dermal conditions.

In this report, *Causticum* was prescribed based on the totality of symptoms, including scar hardness, pigmentation, itching, and associated systemic issues such as constipation and emotional sensitivity, melancholy. The patient's symptoms ranging from scar pliability and vascularity to overall well-being showed progressive and sustained improvement. Alongside scar resolution, general health parameters like appetite, sleep, and bowel function also improved, reinforcing the holistic scope of homeopathic treatment.

While conventional approaches like silicone gel sheaths remain standard for managing HSc, in this case, no such measures, including topical ointments, were prescribed. Given the caustic origin and skin-reactive properties of *Causticum*, its homeopathic application is consistent with the similia principle. Nonetheless, spontaneous scar resolution over time cannot be fully excluded in this case. As the literature points out, the trajectory of scar maturation is highly variable, with some cases resolving naturally months after initial formation. However, the synchronous resolution of both local scar symptoms and constitutional complaints adds weight to the therapeutic effect of *Causticum*.



Repertoization chart: Indicating the Similimum Medicine as CAUSTICUM
 Courtesy of Synergy Homeopathic Software.

Adjunct nutritional support enhanced the constitutional response. The absence of topical application preparations (ointments, lotions, oil, etc.) avoided suppression and allowed internal healing.

The outcome suggests that classical individualized homeopathy, when integrated with strategic nutritional management, may offer a curative approach in otherwise so-called refractory conditions, like the present case.

Acknowledgments

The patient's parents gave their consent for publishing this case without using identifying details, such as a photograph, real name, or address (the consent & assent form attached to the email to the IJRH). The patient also gave his assent for the same.

We thank the patient's parents for their trust, enthusiasm, resilience, and continuous support by complying with the treatment.

- **Financial Support and Sponsorship:** None.
- **Conflicts of Interest:** The author declares no conflict of interest.

Biography

Dr. Vikas Singhal is a classical homeopath with over two decades of experience, treating patients from 70+ countries. He is Director, Homeo Saga Pvt. Ltd. He is also Director at Dr. Singhal Homeo Clinic. He is a supporter and donor member of UNICEF. Also working and making research in the field of chronic and although otherwise called as incurable diseases and creating scientific publications. His expertise in managing chronic viral and autoimmune disorders, including HPV-related and syphilitic infections, reflects the power of homeopathy as a holistic, natural system of healing. He is one of the best Homeopathic Physicians to treat acute & chronic, recurring, autoimmune, and resistant diseases in the Tricity and India. He is offering treatment for rheumatoid arthritis, Ulcerative Colitis, Vitiligo, Ankylosing spondylitis, Psoriasis, Osteomyelitis,

and various rare diseases considered incurable in other systems of medicines to Indian Patients and patients from different parts of the world. Dr. Singhal is known for his individualized, evidence-based approach to treatment. His commitment to evidence-based, classical homeopathic practice has earned him respect and recognition which also earned him several honors and awards for his selfless service to human being, he is the recipient of prestigious Bharatshri Award (2025). Dr. Singhal is a Life Member of leading professional bodies like the Indian Institute of Homeopathic Physicians (IIHP), Akhil Bhartiya Chikitsak Association (ABCA), Liga Medicorum Homoeopathica Internationalis (LMHI), and the Australian Homeopathic Association (International Allied Member Practitioner). He is also an Honorary Physician at Tiny Tots Preparatory School, Chandigarh. Dr Singhal is a well-known speaker at various national and international seminars and conferences. His Youtube channel is very popular named as Homeo Doctor

(<https://youtube.com/@homeodoctor?si=gAG2li49yCKrOr0k>).

References

1. Alecu A, Alecu M, Mărcus G. Effect of the homoeopathic remedies *Arnica montana* and *Staphysagria* on the time of healing of surgical wounds. *Cultura Homeopatica*. 2007;20:19-21.
2. Atiyeh BS. Nonsurgical management of hypertrophic scars: Evidence-based therapies, standard practices, and emerging methods. *Aesthetic Plast Surg*. 2007;31:468-492.
3. Bloemen MC, van der Veer WM, Ulrich MM, van Zuijlen PP, Niessen FB, Middelkoop E. Prevention and curative management of hypertrophic scar formation. *Burns*. 2009;35:463-475.
4. Bombaro KM, Engrav LH, Carrougier GJ, Wiechman SA, Faucher L, Costa BA, *et al*. What is the prevalence of hypertrophic scarring following burns? *Burns*.

- 2003;29:299-302.
5. Boericke W. Pocket manual of homoeopathic materia medica and repertory. Reprint ed. New Delhi: B Jain Publishers; 1998.
 6. Meenakshi J, Jayaraman V, Ramakrishnan KM, Babu M. Keloid and hypertrophic scar: A review. *Indian J Plast Surg.* 2005;38:175-179.
 7. Draaijers LJ, Tempelman FR, Botman YA, Tuinebreijer WE, Middelkoop E, Kreis RW, *et al.* The patient and observer scar assessment scale: A reliable and feasible tool for scar evaluation. *Plast Reconstr Surg.* 2004;113:1960-1965.
 8. Foubister DM. Homoeopathy and scar tissue: Observations on the influence of certain potentized substances on scar tissue. *Br Homoeopath J.* 1975;64:60-64.
 9. Leaman AM, Gorman D. Cantharis in the early treatment of minor burns. *Arch Emerg Med.* 1989;6:259-261.
 10. Van den Kerckhove E, Stappaerts K, Boeckx W, Van den Hof B, Monstrey S, Van der Kelen A, *et al.* Silicones in the rehabilitation of burns: A review and overview. *Burns.* 2001;27:205-214.
 11. Choudhuri NM. *Materia medica.* Kolkata: Hahnemann Publishing Co; year not specified.
 12. Boericke W. Pocket manual of homoeopathic materia medica and repertory. New Delhi: B Jain Publishers; year not specified.
 13. Allen HC. Keynotes and characteristics with comparisons of some leading remedies of the materia medica with bowel nosodes. 8th ed. New Delhi: B Jain Publishers; year not specified.
 14. Uniyal P. *Materia medica for students.* New Delhi: B Jain Publishers; year not specified.
 15. Kinra R. *Materia medica for students.* New Delhi: B Jain Publishers; year not specified.
 16. Davidson S, Ralston SH, Penman ID, Strachan MWJ, Hobson RP. *Davidson's principles and practice of medicine.* 24th ed. Edinburgh: Elsevier; year not specified.
 17. Bailey H, Love M. *Hamilton Bailey's physical signs.* 5th ed. London: H K Lewis; year not specified.

How to Cite This Article

Singhal V. Completely cured case of keloid (hypertrophic burn scar): Homeopathic treatment of a 9-year-old boy. *International Journal of Homoeopathic Sciences.* 2025;9(4):1490-1499.

Creative Commons (CC) License

This is an open access journal, and articles are distributed under the terms of the Creative Commons Attribution-Non Commercial-Share Alike 4.0 International (CC BY-NC-SA 4.0) License, which allows others to remix, tweak, and build upon the work non-commercially, as long as appropriate credit is given and the new creations are licensed under the identical terms.