International Journal of Homoeopathic Sciences

E-ISSN: 2616-4493
P-ISSN: 2616-4485
Impact Factor (RJIF): 5.96
www.homoeopathicjournal.com
IJHS 2025; 9(4): 1640-1642
Received: 16-09-2025
Accepted: 18-10-2025

Dr. Mukund Sahu
MD Scholar, Department of Homoeopathic Pharmacy, Government Homoeopathic Medical College & Hospital, Bhopal, Madhya Pradesh, India

Dr. Monali Choukikar
MD Scholar, Department of Homoeopathic Pharmacy, Government Homoeopathic Medical College & Hospital, Bhopal, Madhya Pradesh, India

Dr. Chetna Pandey
HOD, Department of Homoeopathic Pharmacy, Government Homoeopathic Medical College & Hospital, Bhopal, Madhya Pradesh, India

Corresponding Author:
Dr. Mukund Sahu
MD Scholar, Department of Homoeopathic Pharmacy, Government Homoeopathic Medical College & Hospital, Bhopal, Madhya Pradesh, India

Therapeutic role of natrum muriaticum in perioral dermatitis: A detailed case study

Mukund Sahu, Monali Choukikar and Chetna Pandey

DOI: https://www.doi.org/10.33545/26164485.2025.v9.i4.Y.2127

Abstract
Perioral Dermatitis (PD) is a chronic, inflammatory facial illness characterized by multiple erythematous papules, burning, and esthetic discomfort. Topical antibiotics and anti-inflammatory medications are most commonly used in conventional treatment, although relapse rates remain high.
This case study describes on the successful homeopathic treatment of perioral dermatitis with Natrum muriaticum, which was chosen based on customized and individualised totality. Over the course of one and half month with proper follow up, the patient showed significant improvement with no recurrence. This instance highlights the potential benefits of customized homeopathy in dermatological therapy.

Keywords: Perioral dermatitis, homoeopathy, natrum muriaticum, constitutional treatment, similimum

Introduction
In the course of ordinary dermatological practice, a wide range of this kind of lesions are in countered. An inflammatory dermatosis that usually affects the perioral and perinasal regions is called perioral dermatitis (POD). Erythematous papules, dryness, and burning sensations are its hallmarks. Topical corticosteroid abuse, cosmetics, UV radiation, hormones, and psychological stress are some of the triggers.
It is light-sensitive seborrheic, chronic papulopustular facial dermatitis, granulomatous perioral dermatitis, lupus-like perioral dermatitis, stewardess disease are synonyms for a chronic papulopustular facial dermatitis. It mostly occurs in young women. The clinical and histologic features of the lesions resemble those of rosacea.
Homeopathy offers an individualized therapeutic approach, prescribing remedies based on physical, emotional, and general characteristics of the patient. Natrum muriaticum, a frequently used constitutional remedy, has shown relevance in chronic skin diseases, especially when psychological factors play a role.
This article presents a detailed case demonstrating the effectiveness of Natrum muriaticum in treating perioral dermatitis.

Etiology
Although the precise etiology is uncertain, PD is closely linked to a number of conditions that compromise the skin's protective layer:
- **Topical steroid:** The most frequent trigger is topical steroids. Even if steroid creams were first given for another condition, long-term or sporadic use of them on the face frequently results in PD. Stopping steroid use may cause the rash to flare up.
- **Skincare and cosmetics:** Occlusive ointments, moisturizers, thick face creams, and some sunscreens, especially physical ones.
- **Dental products:** Sodium Lauryl Sulfate (SLS) and fluorinated toothpaste.
- **Additional factors:** Stress, UV light, extreme heat, hormonal changes (including oral contraceptives), and specific skin microbes, chewing gum, dental fillings.
- In recent years, anti COVID19 face masks have also been linked to PD.

Key symptoms
- **Rash:** Clusters of tiny, red or pink, often scaly or flaky bumps (papules) or pus-filled bumps (pustules).

- **Location:** Most commonly circles the mouth, often sparing a small, clear border of skin immediately next to the lips (the vermilion border). It can also spread to the nasolabial folds, nose, and eyes.
- **Sensation:** The rash may be accompanied by a feeling of burning, stinging, or mild itching.

Homeopathic remedy	Indicating symptoms (Keynotes)
Graphites	Eruptions are dry, scaly, and may have a sticky, glue-like discharge/oozing. Often found in skin folds or around the lips/chin. Intense itching, which may worsen from warmth.
Rhus toxicodendron (Rhus-tox)	Intense itching and burning sensation. The eruptions are often vesicular (small fluid-filled blisters) or pustular, looking red and swollen. Restlessness and improvement from moving about.
Sulphur	Dry, red, intensely itchy skin, which is often scratched until raw or bleeding. Itching is typically worse from warmth, scratching, and at night. The skin may look unhealthy or dirty.
Natrum muriaticum (Nat-mur)	Recommended when the condition seems linked to sun exposure, grief, or emotional distress. The eruptions are often dry, cracked, and may appear along the hairline or around the mouth/lips.
Hepar sulphuris (Hepar-s)	Indicated for painful, infected, or highly sensitive eruptions, especially when pustules are prominent. Extreme sensitivity to touch, cold, and air.

Case profile

A 48 years old lady(homemaker) came to our OPD at government homoeopathic medical college and hospital Bhopal, with the complaints of severe tiny, erythematous, pustule-papules eruptions with itching and burning around the mouth and lips, since 10-15 days ago. Aggravate in evening and from touch.

Her skin is sensitive to touch. she has taken conventional treatment many times before without any relief, so he consulted me for cure.

Past history

No history of any other systemic illness is present.
Took topical ointment for this current suffering.
Family history-Nothing significant found in family history

Physical general

Appetite: Normal
Desire: Salt, sour things
Aversion: Milk
Thirst: Much quantity water
Tongue: Dryness present, marked
Stool: Nothing specific
Urine: Nothing specific
Thermal: Chilly patient

Mental generals

Patient is sad and does not want to speak anybody, depressed about her diseases especially of chronic origin. patient have grief due to long term suffering and got angry in every triffels, especially while giving her sympathy which aggravate her.
She seems sad with her life and want to be alone to cry.

Repertorization

Synthesis repertory by Dr. Frederik Schroyens.

Reportorial totality

1. Mind - anger - trifles, at
2. Mind - company-aversion to-desire for solitude
3. Mind - consolation - agg. - sympathy agg.
4. Mind - irritability - trifles, from
5. Mind - sadness - chronic diseases, in
6. Mind - weeping - alone, when
7. Face - eruptions - burning
8. Face - eruptions - mouth-around
9. Skin - eruptions - corticosteoids, after use of
10. Skin - eruptions - itching-touch agg.
11. Generals - food and drink - milk - aversion
12. Generals - food and drink - sour food, acids, desire - salt; and

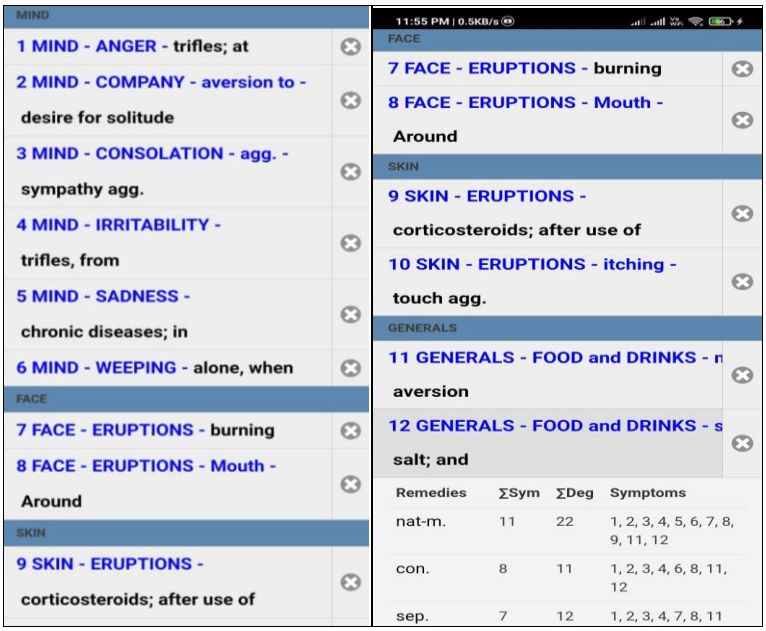

Reportorial analysis
Natrum mur. 11/22
Conium 8/11
Sepia 7/12
Prescription - 15/10/25
Natrum mur - 200/BD/3days
Rubram met - 200/BD/10days

1st follow up: 10/11/25
Mild improvement in complaints, inflammation is reduced.
Natrum mur - 30/BD/5days
SL BD/10 days

2nd follow up: 26/11/25
Eruptions are gone; no itching, burning and scaring.
SL BD/15 days
Advised for applying coconut oil.

Discussion
Despite standard treatment, perioral dermatitis is frequently chronic and recurrent. The issue is frequently made worse by psychological stress and topical steroid abuse. A comprehensive analysis in this instance showed a significant emotional and constitutional association with Natrum muriaticum. According to earlier homeopathic literature, this remedy is beneficial for people with dry skin, sun sensitivity, and emotional introversion.
Conclusion: Using customized and advance homeopathic principles, this case study illustrates Natrum muriaticum's possible therapeutic function in treating perioral dermatitis. The patient experienced long-term stability and total remission, indicating that homeopathy may be a useful supplemental treatment for persistent inflammatory skin disorders.

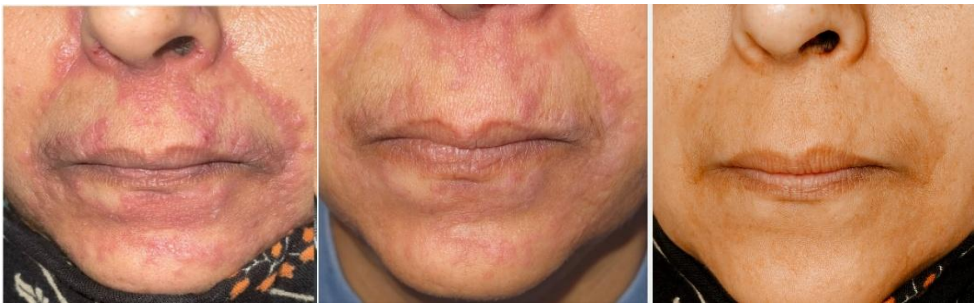

15/10/25 10/11/25 26/11/25

Financial support and sponsorship: Nil.
Conflicts of interest: There are no conflicts of interest.

Creative Commons (CC) License
This is an open access journal, and articles are distributed under the terms of the Creative Commons Attribution-NonCommercial-ShareAlike 4.0 International (CC BY-NC-SA 4.0) License, which allows others to remix, tweak, and build upon the work non-commercially, as long as appropriate credit is given and the new creations are licensed under the identical terms.

References
1. Lipozenčić J, Wolf R. Perioral dermatitis. Clin Dermatol.; 2014.
2. Nguyen V, Eichenfield LF. Periorificial dermatitis in children and adults. J Am Acad Dermatol.; 2006.
3. Boericke W. Pocket manual of homeopathic materia medica. 9th ed. New Delhi: B Jain Publishers; 2019.
4. Hahnemann S. Organon of medicine. 6th ed. New Delhi: B Jain Publishers; 2011.
5. Hengge UR, Ruzicka T, Schwartz RA, Cork MJ. Adverse effects of topical glucocorticosteroids. J Am Acad Dermatol.; 2006.
6. Kosari P, Feldman SR. Fluocinonide-induced perioral dermatitis in a patient with psoriasis: case report. Dermatol Online J.; 2009.
7. Satyawan I, Oranje AP, van Joost T. Perioral dermatitis in a child due to rosin in chewing gum. Contact Dermatitis.; 1990.
8. Veraldi S, Mattioli MA, Nazzaro G. Anti-COVID-19 face masks and perioral dermatitis. J Clin Aesthet Dermatol.; 2023 May.
9. Tempark T, Shwayder TA. Perioral dermatitis: a review of the condition with special attention to treatment options. Am J Clin Dermatol.; 2014.
10. van Haselen RA. Homeopathy in dermatology: an overview. Homeopathy.; 2017.

How to Cite This Article
Sahu M, Choukikar M, Pandey C. Therapeutic role of natrum muriaticum in perioral dermatitis: A detailed case study. International Journal of Homoeopathic Sciences. 2025;9(4):1640-1642.