



International Journal of Homoeopathic Sciences

E-ISSN: 2616-4493
P-ISSN: 2616-4485
Impact Factor (RJIF): 5.96
www.homoeopathicjournal.com
IJHS 2025; 9(4): 1796-1802
Received: 10-11-2025
Accepted: 15-12-2025

Dr. Deepa Warpudkar Rajenimbalkar
1) MD, Ph.D. (Ex-student
from Dr. MPK Homoeopathic
Medical College, Homoeopathy
University, Jaipur, Rajasthan,
India
2) Working Lifetron
Healthcare Homeopathy
Clinic, Bangalore, Karnataka,
India

Dr. Gurukiran N
1) BHMS from Government
Homoeopathic College,
Bangalore, Karnataka, India
2) Practioner at Homoeo Hani
Clinic, Bangalore, Karnataka,
India

Corresponding Author:
Dr Deepa Warpudkar
Rajenimbalkar
1) MD, Ph.D. (Ex-student
from Dr. MPK Homoeopathic
Medical College, Homoeopathy
University, Jaipur, Rajasthan,
India
2) Working Lifetron
Healthcare Homeopathy
Clinic, Bangalore, Karnataka,
India

Homoeopathic management in the psoriasis cases: A case series

Deepa Warpudkar Rajenimbalkar and Gurukiran N

DOI: <https://www.doi.org/10.33545/26164485.2025.v9.i4.AA.2153>

Abstract

It is a chronic inflammatory skin disorder clinically characterised by erythematous, sharply demarcated papules and rounded plaques covered by silvery white scales. It has been seen in both the sexes and at any age. A clinical study of 10 well diagnosed cases of psoriasis were registered for the treatment. Clinical diagnosis followed by constitutional treatment showed good results.

Keywords: Psoriasis, constitutional treatment, rounded plaques

Introduction

Psoriasis considered to be inherited as an autosomal dominant character with irregular penetrance. According to World Health Organization, the reported prevalence of this disease ranges between 0.09 and 11.43 percent. This makes it a serious health problem with at least 100 million people affected across the globe.

It is found in more than one member of the family in 10-30% of cases. It is seen that the time taken for transfer of epidermal cells from basal cell layer to outer surface of skin is drastically reduced from the normal 1 month to 3-5 days. This results in formation of immature epidermal cells which are shed as scales.

The skin lesions are variably pruritic, traumatized areas often develop lesions of Psoriasis 'Koebner phenomenon'.

Types

Psoriasis manifests as well defined erythematous scaly plaques which become silvery on attempt to scrape. This is known as

1. Plaque type
2. Pustular psoriasis
3. Flexural psoriasis
4. Psoriasis arthropathica
5. Guttate psoriasis

Aetiology

It's fairly common in tropics, it's more prevalent in temperate climate. Attacks are more common in winter than summer; the eruption has a natural tendency to clear up in summer. The exact aetiology is still unknown.

It is a heredo-familial disease brought on by stress, anxiety, mental trauma, fever, physical injury, digestive upsets, etc. on a genetic constitution. Transmission is by single, irregularly dominant gene. Streptococcal infection, presence of diabetes and purines in the diet are the other precipitating factors.

Pathology

Psoriasis appears to be largely a disorder of keratinization. The basic defect is rapid replacement of the epidermis in psoriatic lesion 3-4 days instead of 28 days in normal skin. It has been discovered that apparently normal skin of both the psoriatic and their relations show these changes in miniature- 'latent psoriasis'.

Clinical features

Typical distribution is extensor. The areas are commonly affected are scalp, back of elbows, front of knees and legs and lower part of back of the trunk.

Psoriasis exhibits itself as dry, well-defined macules, papules and plaques of erythema with layer of silvery scales. The typical lesions are coin shaped. When psoriatic lesions are scratched with a point of dissecting forceps, a candle-grease sign (tache de bouge). The complete removal of a scale produces pin-point bleeding (Auspitz sign). The scalp is involved in almost all the cases. It shows thick, scaly papules distributed all over. The lesions are dry, and there is no matting of hair. Psoriasis of scalp never causes loss of hair and baldness.

Nail shows three types of lesions

- Pitting
- Separation of distal portion of nail from nailbed and walls
- Thickening of nail, accompanied by collection of hyperkeratotic debris under the nail.

Occasionally psoriasis starts on palms and soles, it may be confined to these areas (psoriasis inversus)

Materials & methods

- 10 well diagnosed cases of psoriasis were registered for the treatment at Homoeo Hani Clinic and Research centre. From 2012 to 2017.
- Clinical diagnosis followed by constitutional treatment showed good results.
- Patients were asked to visit monthly once.

Treatment

- Constitutional approach to the psoriasis cases showed very good results.
- The general health is maintained and exciting causes studied and eliminated, as far as possible.
- A moderate, warm climate, frequent sunbaths before the onset of winter and visit to sulphur springs useful in bringing down the relapse rate.

In 2018, a study involving 70 patients was done to find out if homeopathy helped to treat psoriasis. The study published by the International Journal of Homeopathic Sciences found that homeopathy can be used for psoriasis treatment. Another study published by the Complementary Medicine Research in June 2023, also showed that homeopathic medicines were more effective than placebos when it came to treatment of psoriasis. For that study, researchers did a six-month randomized trial at the National Institute of Homoeopathy in India, involving 51 people with psoriasis.

Diet

- Constitutional approach to the psoriasis cases showed very good results.
- The general health is maintained and exciting causes studied and eliminated, as far as possible.
- A moderate, warm climate, frequent sunbaths before the onset of winter and visit to sulphur springs useful in bringing down the relapse rate.

Diet: Reduce fats, Animal proteins

Best foods if you have psoriasis include:

Fish, lean protein or plant-based proteins such as tofu or tempeh.

- Fruits and vegetables.
- Legumes (beans and lentils)
- Nuts and seeds.
- Olive oil.
- Small amounts of low-fat dairy.
- Whole grains.

The homeopathic remedies do not intend to suppress this inflammation. In fact, they intend to correct the cause that has resulted in this indiscriminate cell division and also the inflammation. Once these two things are set right, the symptoms disappear on their own.

Case 1: (Fig 1 and Fig 2)

A 75 years old male was presented with the skin eruptions psoriatic since 3 years, the patient had taken allopathic medicines with some topical ointments without any improvement. After stopping all other treatment for few months,

- The patient opted for homoeopathic treatment, 15-1-13.
- After case-taking considering the patient totality
- Rx
- Sulphur 200 od, Sac Lac bd/1mon
- After 1 month
- 18-2-13
- There was a drastic improvement.
- There was some itching and burning sensation
- Rx
- Sulphur 200 od, Sac lac bd/1mon
- 17-3-13
- Pt gets better, skin eruptions has reduced, no itching and burning sensation
- Rx
- Sac lac bd/1mon.

Case 2: (Fig 3 and Fig 4)

- A male aged 42 years was presented with the psoriatic eruptions over the thorax region of the body since 18 years, He underwent number of therapies, which also includes homoeopathy.
- After undergoing therapies, the eruptions started to spread all over, with itching and scaling.
- After case-taking on 20-2-15,
- Rx
- Sepia 200 od, Sac lac bd/1mon
- 24-3-15
- Patient got better, there was a decrease in the skin eruptions,
- Itching was present
- After considering his totality
- Rx
- Sulphur 200 od, Sac lac bd/1mon
- 25-4-15
- Pt gets better, skin eruptions was reduced further,
- Itching was also reduced
- Rx
- Sulphur 1m od, sac lac bd/1mon
- 26-5-15
- The skin eruptions over the thorax has reduced, but some spots were present over the lateral part of the thorax, with some itching.

- Rx
- Sulphur 1m od, Sac lac bd/1mon
- 30-6-15
- The skin eruptions has reduced drastically without any itching.
- Rx
- Sac lac bd/1mon

Case 3: (Fig 5 and Fig 6)

- A female aged 25 years was presented with the psoriatic eruptions over the arms since 5 years,
- Itching with scaling present, the patient was applying some ointments without any changes in the lesions, after few months, she stopped all ointments for a while the she opted for homoeopathic treatment.
- After case-taking, on 23-11-16 considering the totality
- Rx
- Petroleum 200 od, sac lac bd.1mon
- 30-12-16,
- Pt had improvement with the eruptions,
- Rx
- Petroleum 200 od, sac lac bd/1mon
- 2-2-17
- Pt got much better, the eruptions has reduced, without scaling, transient itching was present
- Rx
- Petroleum 200 od, sac lac bd/1mon
- 4-3-17
- The skin eruptions over the arms has reduced drastically,
- Rx
- Sac lac bd/1mon

Case 4: (Fig 7 and Fig 8)

- A male aged 24 years was presented with the skin eruptions psoriatic on the soles and sides of the soles since 4 years.
- The patient had itching with scaling.
- After case-taking on 5-1-17 considering the totality
- Rx
- Nux vom 200 od, sac lac bd/1mon
- 6-2-17
- There was slight improvement, eruptions had reduced minimally.
- Rx
- Nux vom 1m od, sac lac bd/1mon
- 7-3-17
- Patient got better, eruptions started to reduce with itching.
- Rx
- Nux vom 1m od, sac lac bd/1mon
- 8-3-17
- Patient got better, skin eruptions and scaling has reduced drastically,
- Rx
- Nux vom 1m od, sac lac bd/1mon
- 5-5-17
- There was furthermore improvement
- Rx
- Sac lac bd/1mon
- 7-6-17

- There was some spots which has re-appeared with some itching
- Rx
- Nux vom 1m od

Case 5: (Fig 9 and Fig 10)

- A male aged 36 years was presented with skin eruptions over the flexural part (elbow) since 2 months, started with right elbow
- Itching was present,
- After case-taking, on 26-7-12
- Rx
- Lyco 200 od, sac lac bd/1mon
- 22-8-12
- Pt gets better, skin eruptions over the elbow has reduced
- Rx
- Lyco 200 od, sac lac bd.1mon
- 19-9-12
- Pt gets better, skin eruptions has reduced to 90%
- Rx
- Lyco 200 od, sac lac bd/1mon
- 20-10-12
- Skin eruptions around the elbow has disappeared without itching
- Rx
- Sac lac bd/1mon

Case 6: (Fig 11 and Fig 12)

- A male aged 48 years was presented with psoriatic eruptions all over the body since 10 years,
- Itching and scaling was present, <- winter
- After case-taking on 13-8-14 according to totality
- Rx
- Kali ars 200 od, sac lac bd/1mon
- 17-9-14
- There was some improvement in the skin eruptions, itching was present,
- Rx
- Kali ars 200 od, sac lac bd/1mon
- 15-10-14
- Skin eruptions started to reduce, scaling was present, with itching
- Rx
- Kali ars 200 od, sac lac bd/1mon
- 19-11-14
- Skin eruptions present with dryness and itching
- Rx
- Psorinum 1m od
- Sac lac bd/1mon
- 21-12-14
- Skin eruptions has reduced with itching
- Rx
- Kali ars 200 od
- Sac lac bd/1mon
- 19-1-15
- Skin eruptions has reduced drastically, with transient itching
- Rx
- Kali ars 200 od, sac lac bd/1mon
- 20-2-15

- Skin eruptions was completely better
- Rx
- Sac lac bd/1mon
- 8-11-15
- There were some mild skin eruptions, itching over the body,
- Rx
- Kali ars 200 2 doses, sac lac bd/1mon
- 12-12-15
- Skin eruptions has reduced,
- Rx
- Kali ars 200 od, sac lac bd.1mon
- 20-1-16
- The skin eruptions over the body got better,
- Rx
- Sac lac bd/1mon.

Case 7: (Fig 13 and Fig 14)

- A male aged 30 years was presented with the palmar psoriasis since 2 years,
- Itching and scaling was present. Started with both the palms.
- According to the case, 20-1-16
- Rx
- Petroleum 200 od, sac lac bd/1mon
- 19-2-16
- Patient got better, skin eruptions has reduced, mild itching and irritation was present
- Rx
- Petroleum 200 od, sac lac bd/1mon
- 22-3-16
- The dryness of the palms with eruptions disappeared completely
- Rx
- Sac lac bd/1mon
- 8-11-18
- There was some eruptions seen on the borders of the palms with itching and dryness
- Rx
- Petroleum 200 od, sac lac bd/1mon
- 19-12-18
- The patient had improvement; the lesions started with reduce. Itching was also reduced
- Rx
- Petroleum 200 od, sac lac bd.1mon
- 22-1-19
- Rx
- The eruptions on the palms has reduced completely
- Rx
- Sac lac bd.1mon

Case 8: (Fig 15 and Fig 16)

- A male aged 18 years was presented with skin eruptions psoriatic in the last 15 years,

- The patient had undergone other therapies without any improvement and the patient had stopped all forms of the treatment in the past 2 years. Then the patient opted for homoeopathic treatment.
- According to the case 26-8-15 homoeopathic treatment was started.
- Rx
- Silicea 200 od. Sac lac bd/1mon
- 27-9-15
- Patient gets better, skin eruptions started to reduce
- Rx
- Silicea 200 od, sac lac bd/1mon
- 25-10-15
- The skin eruptions over the body has reduced, from above downwards, itching was also reduced
- Rx
- Silicea 200 od, sac lac bd/1mon
- 29-11-15
- The skin eruptions has reduced drastically without any itching of scaling.
- Rx
- Sac lac bd/1mon
- 28-12-15
- Patient got completely better, without any eruptions anywhere in the body
- Rx
- Sac lac bd/1mon.

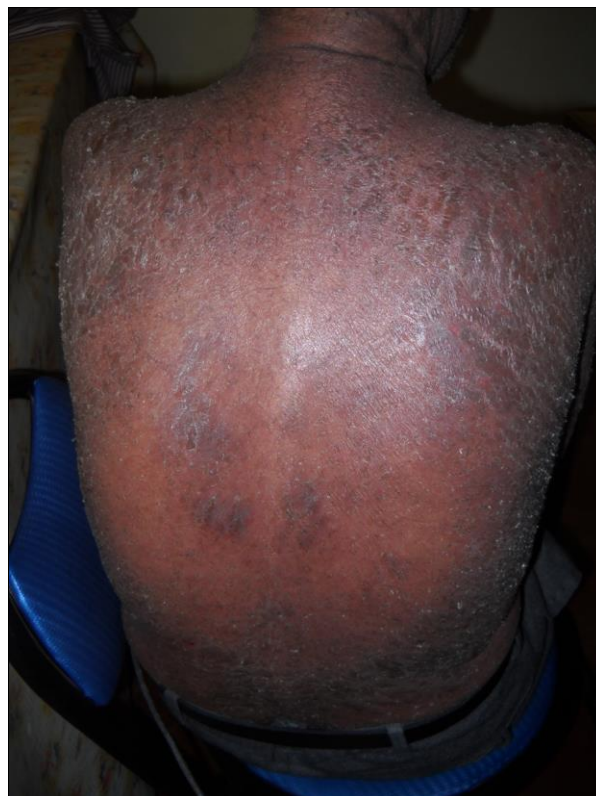

Fig 1: Before homoeopathic treatment, plaque psoriasis

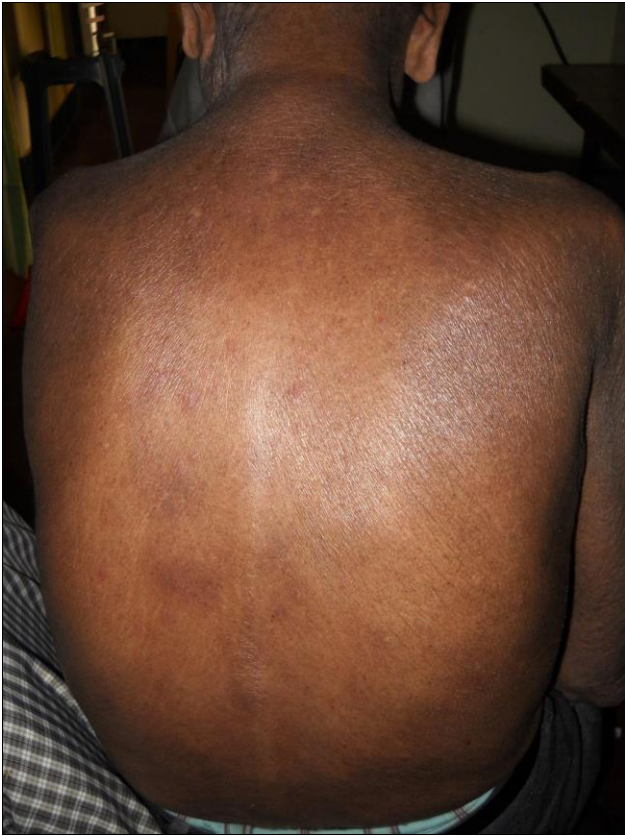

Fig 2: After homoeopathic treatment

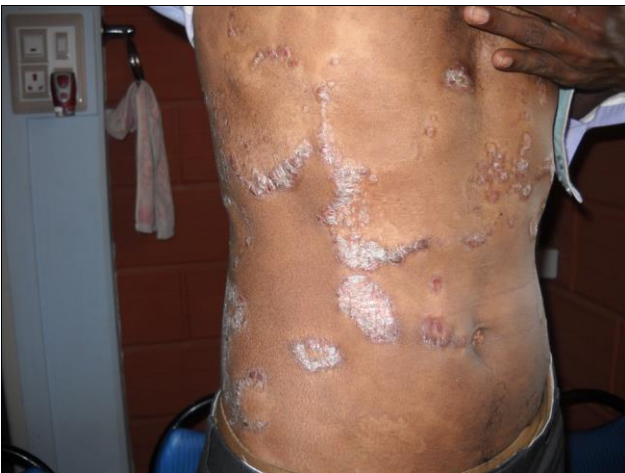

Fig 3: Before homoeopathic treatment plaque psoriasis

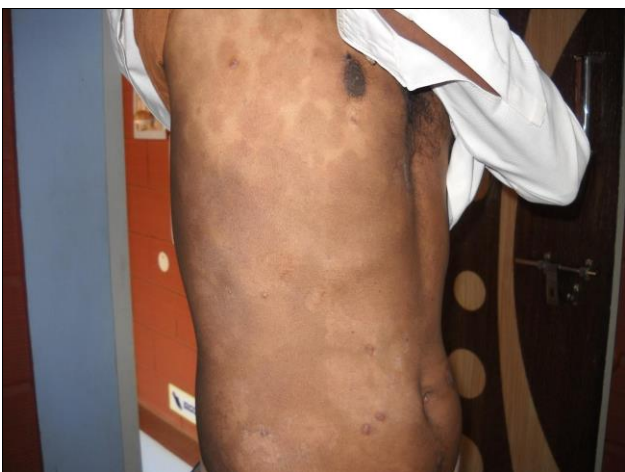

Fig 4: After homoeopathic treatment



Fig 5: Before treatment, guttate psoriasis

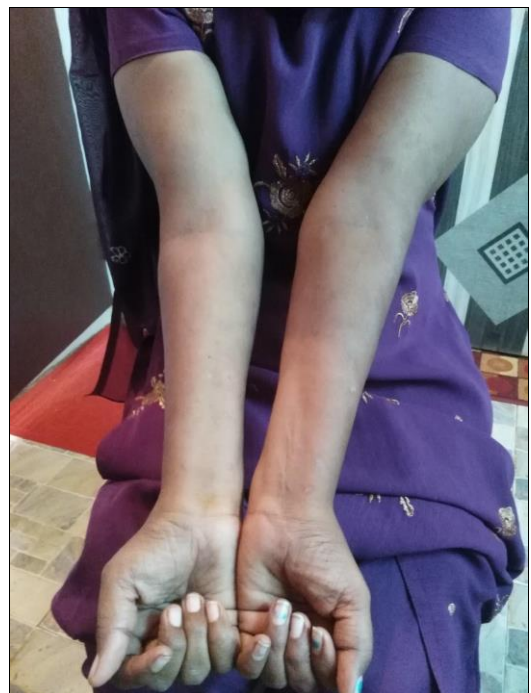

Fig 6: After homoeopathic treatment

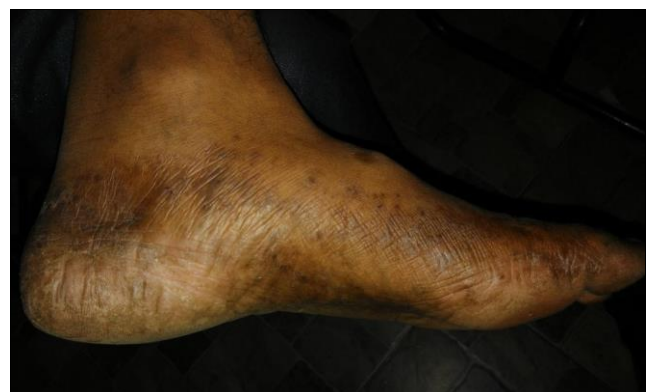

Fig 7: Before homoeopathic treatment plantar psoriasis

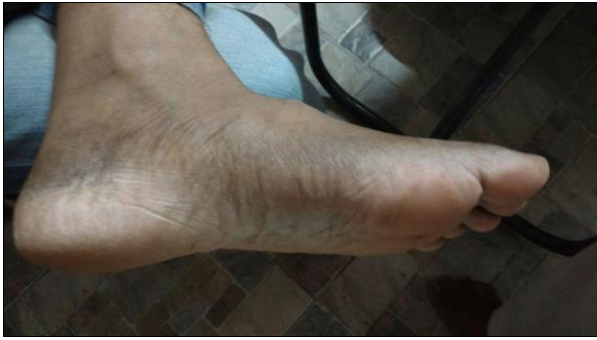

Fig 8: After homoeopathic treatment

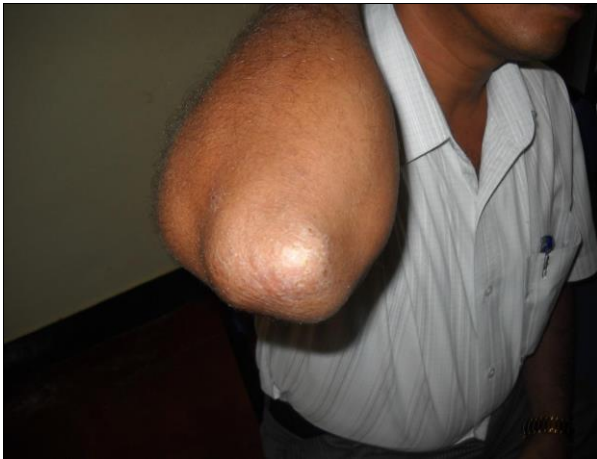

Fig 9: Before homoeopathic treatment flexural psoriasis

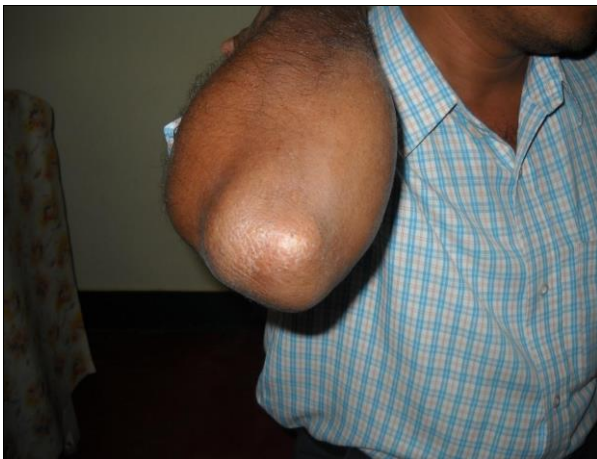

Fig 10: After homoeopathic treatment

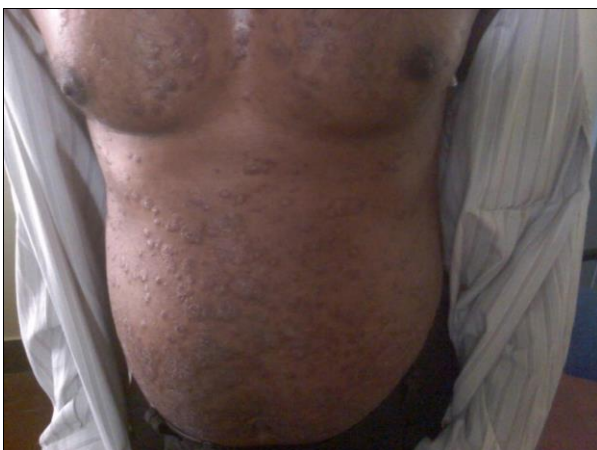


Fig 11: Before homoeopathic treatment plaque psoriasis

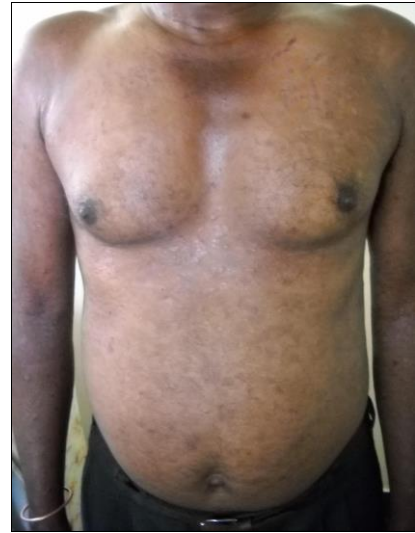

Fig 12: After homoeopathic treatment



Fig 13: Before homoeopathic treatment palmar psoriasis

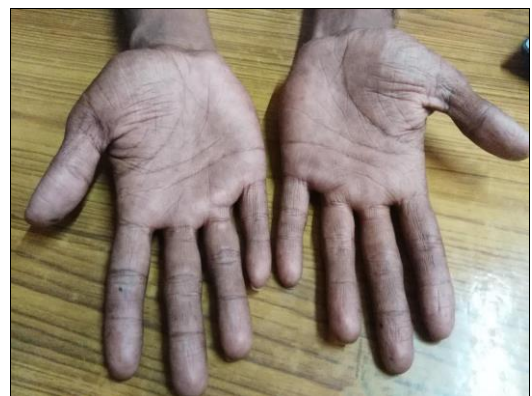

Fig 14: After homoeopathic treatment

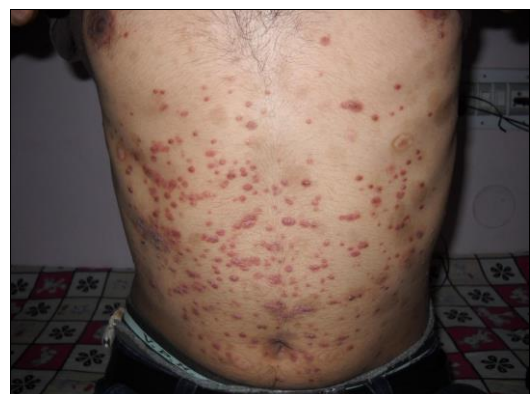

Fig 15: Before homoeopathic treatment guttate psoriasis

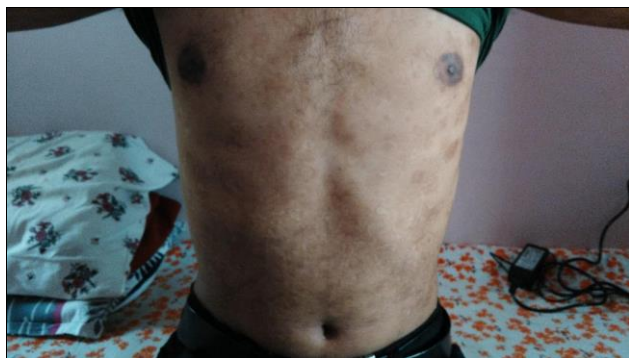

Fig 16: After homoeopathic treatment

Conclusion

- Constitutional remedies are the top to help the psoriasis patients to get rid of it.
- Note: No external applications advised during the course of the treatment.
- Davidson's principle practice of medicine.
- Case details:

References

1. Gupta R, Manchanda RK. Textbook of dermatology for homoeopaths. New Delhi: B. Jain Publishers Pvt. Ltd.; Year not specified.
2. Davidson S. Davidson's principles and practice of medicine. Latest ed. Edinburgh: Elsevier; Year not specified.
3. Hahnemann S. The chronic diseases: their peculiar nature and their homoeopathic cure. Low price ed. New Delhi: B. Jain Publishers Pvt. Ltd.; 2002. p. 46, 61-62.
4. Kent JT. Repertory of the homoeopathic materia medica. Enriched Indian ed., reprinted from 6th American ed. New Delhi: B. Jain Publishers (P) Ltd.; 2000. p. 75, 403, 485, 487, 503, 548, 575, 609, 626, 636, 1370, 1407.
5. Shah J. Homopath Classic-Homeopathic software. Version 8.0 Premium. Mumbai; 2005.
6. Boericke W. New manual of homoeopathic materia medica and repertory. Augmented ed., based on 9th ed. New Delhi: B. Jain Publishers (P) Ltd.; 2000. p. 332.

How to Cite This Article

Rajenimbalkar DW, Gurukiran N. Homoeopathic management in the psoriasis cases: A case series. International Journal of Homoeopathic Sciences. 2025;9(4):1796-1802.

Creative Commons (CC) License

This is an open access journal, and articles are distributed under the terms of the Creative Commons Attribution-Non Commercial-Share Alike 4.0 International (CC BY-NC-SA 4.0) License, which allows others to remix, tweak, and build upon the work non-commercially, as long as appropriate credit is given and the new creations are licensed under the identical terms.