



International Journal of Homoeopathic Sciences

E-ISSN: 2616-4493
P-ISSN: 2616-4485
Impact Factor (RJIF): 5.96
www.homoeopathicjournal.com
IJHS 2026; 10(1): 36-40
Received: 08-11-2025
Accepted: 11-12-2025

Dr. Anjum Fathima Warsi
PG Scholar, M.D.
(Homoeopathy) Part II,
Department of Homoeopathic
Materia Medica, Government
Homoeopathic Medical College
and Hospital, Bangalore,
Karnataka, India

Individualized Homoeopathic Treatment of Filiform Wart: A case report

Anjum Fathima Warsi

DOI: <https://www.doi.org/10.33545/26164485.2026.v10.i1.A.2163>

Abstract

Warts are benign skin growths caused by human papillomavirus (HPV) infection, resulting in localized thickening of the epidermis. Filiform warts are slender, thread-like projections and commonly occur on the face, where they can be cosmetically distressing. This report describes an 8-year-old girl presenting with a solitary filiform wart on the chin. Individualized Homoeopathic treatment was selected based on symptom similarity, and the patient was monitored over a one-year period. Complete resolution of the wart was achieved without the use of topical therapies, along with notable improvement in associated complaints. The outcome indicates that Individualized Homoeopathic medicines may be effective in the treatment of filiform warts.

Keywords: Warts, filiform wart, homoeopathy, case report

Introduction

Warts are non-cancerous skin growths resulting from infection with certain strains of human papillomavirus (HPV). They present as a single or multiple grouped growths, sometimes affecting large skin areas. Various forms are identified, including common, genital, filiform, flat, palmoplantar warts (*myrmecia*), focal epithelial hyperplasia, epidermodysplasia verruciformis, and plantar cysts.

Filiform warts exhibit thin, elongated, spiky projections and typically occur on the face, especially near the eyes, mouth, and nose. Their visible, brush-like appearance often leads to cosmetic concern. Warts are widespread and transmissible, spreading through direct skin contact or contaminated personal items. Although often symptom-free, they may occasionally cause itching, pressure, tightness, or pain, particularly when located on the soles.

Warts are common worldwide, affecting approximately 10% of the population and occurring at all ages. Prevalence is highest among school-aged children (10-20%), peaking between 12 and 16 years, while rates in adults are lower (3-5%). They are more frequent in immunocompromised individuals and certain occupational groups, such as meat handlers, with a similar distribution between males and females.

Among the numerous HPV subtypes, strains 6, 11, 16, 18, 31, and 35 have oncogenic potential, with malignant transformation primarily observed in genital warts and immunosuppressed patients. Most warts are benign and self-limiting, often resolving spontaneously without scarring, though they may cause cosmetic or psychological distress when located on exposed areas.

Diagnosis is usually clinical, with biopsy or viral identification reserved for atypical cases. Modern treatments such as salicylic acid and cryotherapy are effective but may be associated with recurrence or adverse effects.¹ Few studies show favorable outcomes for treating warts with homeopathy.²⁻⁴ This case report presents a possible alternative approach in treating warts.

Case Details

Patient named Ms. AF, aged 8 years, presented to the OPD of Government Homoeopathic Medical College and Hospital, Bangalore, on 24 Oct 2024, with the complaints of a single eruption on chin since 7 months, which was black in color, cracked, cauliflower like, spiky in appearance, soft and fleshy in texture and gradually increasing in size.

- **Negative History:** No history of pain, burning, itching, fever, discharge.

Corresponding Author:
Dr. Anjum Fathima Warsi
PG Scholar, M.D.
(Homoeopathy) Part II,
Department of Homoeopathic
Materia Medica, Government
Homoeopathic Medical College
and Hospital, Bangalore,
Karnataka, India

- **Past history:** Patient had Typhoid 6 months ago, taken allopathic treatment. No allergic or surgical history

Family history

- **Father:** Apparently healthy
- **Mother:** Diabetes mellitus
- **Maternal grandmother:** Alive, DM, Hypothyroidism, warts on neck and face
- **Siblings:** 1 elder brother and 1 elder sister, both are apparently healthy
- **Maternal Aunt:** Multiple warts on neck

Personal history

- **Diet:** Mixed
- **Appetite:** Good
- **Thirst:** Thirstless
- **Desires:** Sweets
- **Aversion:** Nothing specific
- **Bowel habits:** Regular, once/day, no discomfort
- **Bladder habit:** 4-5 times/ day, once/night, non-offensive, no discomfort.
- **Sleep:** good, refreshing
- **Dreams:** Nothing specific
- **Perspiration:** On exertion, non-offensive
- **Thermals:** cold agg
- **Addictions:** Nil
- **Life Space Investigation:** Patient was born and brought up in Bangalore. Has good relation with siblings. She is pampered well as she is the youngest one at home. Currently studying in 4th std. Studies well, enjoys playing with friends.
- **Intellect and understanding:** Good
- **Memory:** Good

General Physical Examination

- **Orientation:** well oriented with time, place and person
- **Built and nourishment:** moderately built and poorly nourished.
- **Weight:** 24kg, Height - 3'6, BMI - 20 Kg/m²
- No signs of pallor, cyanosis, Clubbing, icterus and lymphadenopathy
- Mouth, Eyes, Nose, throat, nails: NAD

Vital signs

- **Temp:** afebrile
- **Pulse:** 90 bpm
- **Spo2:** 99% @ r. a
- **RR:** 16 cpm

Systemic examination

- **Respiratory system:** Bilateral normal vesicular breath sounds heard.
- **CVS:** S1, S2 Heard, no murmurs
- **GIT:** Bowel sounds heard, no tenderness in abdomen

- **CNS:** Reflexes normal, gait normal
- **Locomotor system:** No deformities.
- **Skin:** Inspection: single eruption on chin - black in colour, cracked, cauliflower like, no redness around, no swelling.
- Palpation: soft, spongy texture, no tenderness.

Investigations done: nil

Diagnosis: Filiform wart (ICD 11 - 1E80.Y)⁵

Analysis of symptoms: (Table 1)

Table 1: Analysis of symptoms

Common Symptoms	Uncommon Symptoms
Wart	<ul style="list-style-type: none"> • Wart on chin • Thirstless • Desire sweet • Cold agg

Evaluation of Symptoms: (Table 2)

Table 2: Evaluation of symptoms

Mental generals	Physical generals	Characteristic particulars
-	Desire sweets ++ Cold agg++ Thirstless +	Wart on chin ++

Totality of Symptoms:

- Wart on chin
- Thirstless
- Desire sweets
- Cold agg

Selection of Repertory: Synthesis Repertory

Repertorial totality/ Selection of Rubrics: (Fig. 1)

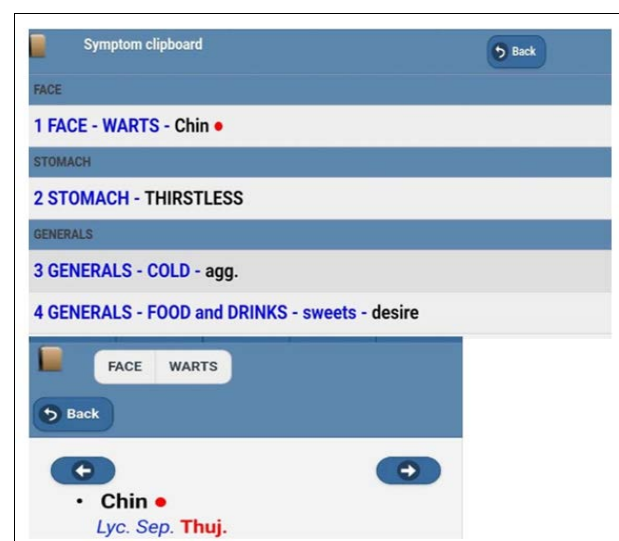


Fig 1: Selection of rubrics

Remedies	ΣSym	ΣDeg	Symptoms
lyc.	4	10	1, 2, 3, 4
sep.	4	9	1, 2, 3, 4
thuj.	4	7	1, 2, 3, 4
chin.	3	9	2, 3, 4
sabad.	3	8	2, 3, 4
graph.	3	7	2, 3, 4
kali-c.	3	7	2, 3, 4
puls.	3	7	2, 3, 4

Fig 2: Repertorial Result

Prescription

Thuja occidentalis 200, one dose followed by Placebo/BD/1 month on 24/10/2024

Reason for selecting Thuja

- It is a well-known remedy used in treating warts.
- No clear indication for any other remedy.

- Rubric:** Face - warts - chin, Thuja is mentioned in 1st grade (3 marks).

The follow up of the case is listed in Table 3

Table 3: Follow up of the case

Sl. No.	Date	Symptoms	Analysis	Prescription
1	02/01/2025	Wart - no change; generally doing well; no new complaints	Though there is no change in the chief complaint (wart), the patient is generally doing well with no new complaints. Hence, waiting is advised.	Placebo, BD, for 2 months
2	07/03/2025	Wart remains the same; dryness and itching of both palms (new complaint); itching near roots of fingers; cracks in soles with bleeding	It has been about 4.5 months since the first prescription. The wart persists and new complaints have developed. As sufficient time has elapsed after <i>Thuja</i> 200 (single dose) without significant improvement, change of remedy is indicated.	<i>Lycopodium</i> 200C, one dose, followed by Placebo, BD, for 1 month
3	28/04/2025	Wart partially fell off; dryness and itching of palms and soles better; cracks in soles better with no bleeding	Improvement in both chief and associated complaints indicates action of the homoeopathic similimum.	Placebo, BD, for 1 month
4	01/06/2025	Wart 90% fallen off; dryness and itching of palms 90% better; cracks in soles 90% better; generally doing well	Excellent improvement observed.	Placebo, BD, for 1 month
5	12/08/2025	Wart completely fallen off; dryness and itching of palms completely relieved; cracks in soles completely healed; generally doing well	This demonstrates the curative action of homoeopathic similimum. A single dose of <i>Lycopodium</i> 200 achieved complete cure, whereas <i>Thuja</i> , though an antisycotic remedy, failed as it was not the similimum. This emphasizes the principles of similars and minimum dose.	Placebo, BD, for 1 month
6	28/11/2025	Wart site fully clear; no recurrence or new warts; no relapse of dryness; no new complaints; sleep and appetite good	Sustain	

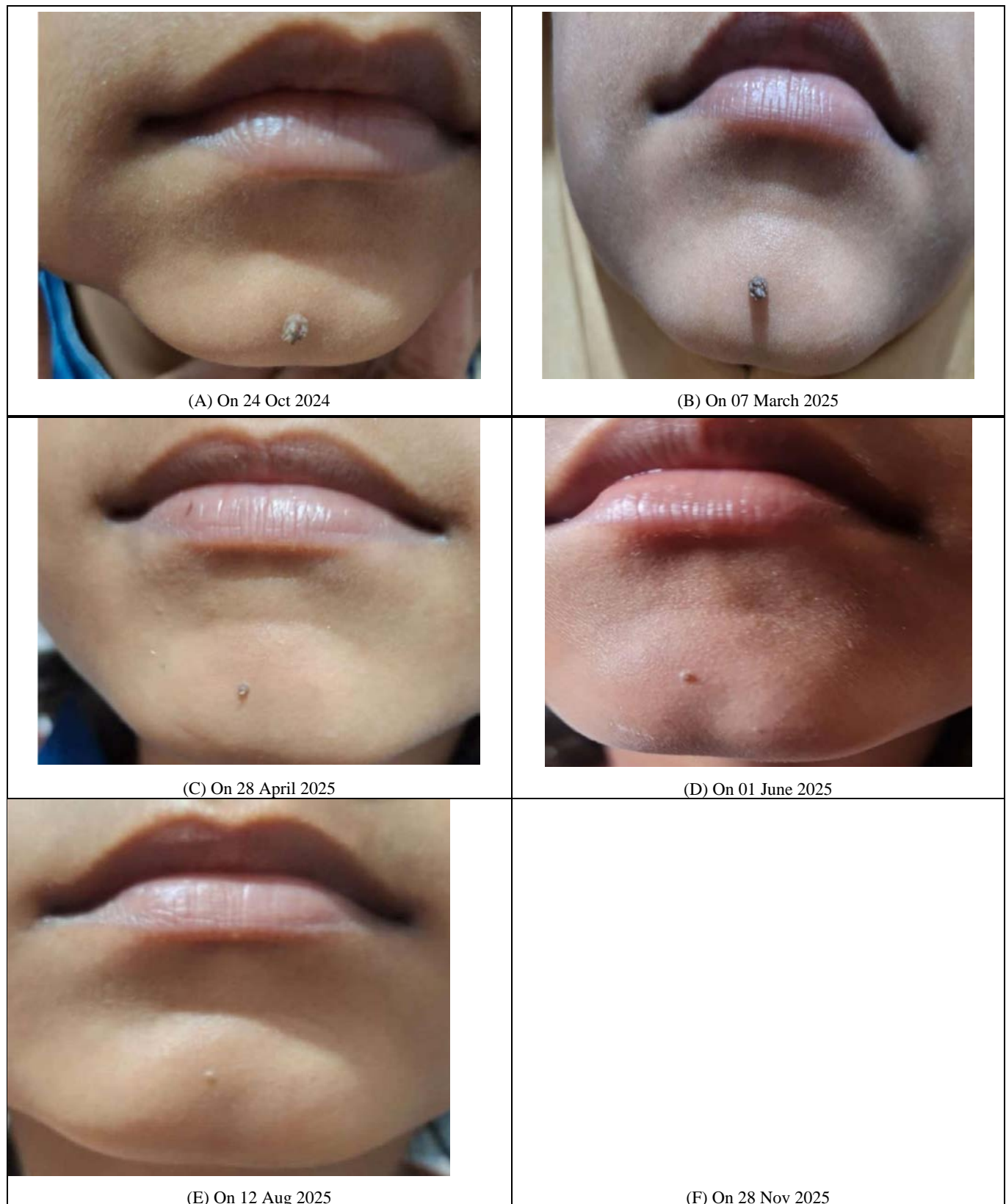

Fig 3: Images showing wart on chin during the treatment period.

Discussion

Warts are benign skin eruptions caused by Human Papilloma Virus (HPV), which can occur in different parts of the body. They are infectious and can spread to others. Most of them disappear by itself, but some remain for many years and increase in size and number and may also recur. The visible symptoms of warts can lead to stigma and further exacerbate the social and emotional challenges

experienced by the affected individuals. It is important to note that warts affects each individual differently. Therefore, it is essential to adopt an individualized treatment plan that takes into consideration the patient's unique mental and physical symptoms, medical history, and overall health.

Previous case reports have indicated that homeopathy may be beneficial in treating warts.²⁻⁴ This case report suggests

that homeopathy can be a safe and effective treatment option for individuals with warts.

Conclusion

In this case, Homoeopathy has demonstrated encouraging outcomes in treating warts. With the single dose of Homoeopathic remedy which was similimum to this case, wart disappeared speedily within few months without leaving any scar and episodes of recurrence. In addition to managing the presenting symptom of the patient, it also improved the overall quality of life of the patient by curing new symptoms of dryness and cracks in palms and soles which had occurred during the treatment period. However, further research is needed to fully understand the mechanisms of the treatment and to determine its effectiveness in larger populations. It is important to continue exploring alternative therapies like Homoeopathy as they may provide valuable options for those suffering from warts and other skin conditions.

Financial support and sponsorship: None

Conflicts of interest: None declared.

References

1. Institute for Quality and Efficiency in Health Care (IQWiG). Overview: warts. Cologne (Germany): IQWiG; 2006-. Updated 2023 Jan 11. <https://www.ncbi.nlm.nih.gov/books/NBK279586/>
2. Shraddhamayananda S. Healing of skin warts with ultradiluted homeopathic medicines—a study in 200 cases. Clin Res Dermatol Open Access. 2017;4(5):1-4.
3. Oza PM. Homeopathic management of warts. Indian Journal of Drugs in Dermatology. 2016;2(1):45-47.
4. Biswas B, Roy PS, Mandal S, Roy P. Four cases of warts treated by individualized homoeopathic medicine: a clinical case study. Journal of Integrated Standardized Homoeopathy. 2022;5(1):10-14.
5. World Health Organization. ICD-11 for mortality and morbidity statistics (ICD-11 MMS), 2025 release. Geneva: World Health Organization; 2025. <https://icd.who.int/browse/2025-01/mms/en>
6. Synthesis App. Mobile application software. Version 2.1. ZEUS SOFT sprl; based on *Repertorium Homoeopathicum Syntheticum*.

How to Cite This Article

Warsi AF. Individualized Homoeopathic Treatment of Filiform Wart: A Case Report. International Journal of Homoeopathic Sciences. 2026;10(1):36-40.

Creative Commons (CC) License

This is an open access journal, and articles are distributed under the terms of the Creative Commons Attribution-NonCommercial-ShareAlike 4.0 International (CC BY-NC-SA 4.0) License, which allows others to remix, tweak, and build upon the work non-commercially, as long as appropriate credit is given and the new creations are licensed under the identical terms.