International Journal of Homoeopathic Sciences

E-ISSN: 2616-4493
P-ISSN: 2616-4485
Impact Factor (RJIF): 5.96
www.homoeopathicjournal.com
IJHS 2026; 10(1): 231-233
Received: 16-10-2025
Accepted: 20-11-2025

Dr. Jyoti Kamble
MD Scholar, Government Homoeopathic Medical College & Hospital, Bhopal, Madhya Pradesh, India

Dr. Roshni Kumre
MD Scholars, Government Homoeopathic Medical College & Hospital, Bhopal, Madhya Pradesh, India

Dr. Shivam Gupta
MD Scholars, Government Homoeopathic Medical College & Hospital, Bhopal, Madhya Pradesh, India

Dr. Hemant Kumar Soni
Professor of Department of Homoeopathic Pharmacy, Government Homoeopathic Medical College & Hospital, Bhopal, Madhya Pradesh, India

Corresponding Author:
Dr. Jyoti Kamble
MD Scholar, Government Homoeopathic Medical College & Hospital, Bhopal, Madhya Pradesh, India

A case study on leucoderma treated with constitutional homoeopathy

Dr. Jyoti Kamble, Dr. Roshni Kumre, Dr. Shivam Gupta and Dr. Hemant Kumar Soni

DOI: https://www.doi.org/10.33545/26164485.2026.v10.i1.D.2191

Abstract
Leucoderma is a chronic depigmentary skin disorder characterized by the appearance of well-defined white patches due to the loss of melanocytes. Its not only affects the physical appearance of the patient but also has a profound psychological impact, especially in young adults. Patient presented with a white patch on the right side of the forehead present for the past six months. There was no associated pain or itching, but the patient was mentally distressed. The case was managed with constitutional homoeopathic medicine based on totality of symptoms. Lycopodium clavatum was selected as the similimum. Marked repigmentation and arrest of further spread were observed during follow-up. This case highlights the role of individualized homoeopathic treatment in managing localized leucoderma effectively.

Keywords: Leucoderma, lycopodium clavatum, homoeopathy

Introduction
Leucoderma, commonly referred to as vitiligo, is an acquired disorder of pigmentation resulting from the destruction or functional impairment of melanocytes. It is clinically characterized by milky white patches with well-defined margins. The disease may affect any part of the body, but lesions on exposed areas such as the face cause significant psychological and social distress.
The etiology of leucoderma is multifactorial and includes autoimmune mechanisms, genetic susceptibility, oxidative stress, endocrine disturbances, and neural factors. Conventional treatment includes topical corticosteroids, immunomodulators, and phototherapy, but these modalities often yield inconsistent results and may cause adverse effects with long-term use.
Homoeopathy adopts a holistic approach, treating the individual as a whole rather than the disease alone. Constitutional remedies aim to correct the internal imbalance responsible for the manifestation of the disease. Lycopodium clavatum is a well-known homoeopathic remedy indicated in right-sided complaints, digestive disturbances, and low self-confidence, and is frequently prescribed in chronic skin diseases including leucoderma.

Case Report
A 26 year old male patient comes with the complain of white patch located on right side of forhead (leukoderma). He has taken conventional treatment before without any relief so he consulted me for cure.

Past History
No history of any other systemic illness Family history
Nothing significant found in family history

Physical General
Appetite - Good Desire - sweet Aversion - salt
Thirst - For cold water Tongue - dry
Stool - Nothing specific Urine - nothing specific Thermal - hot patient

Mental Generals
When I asked about his working profession he said he is very soft for his higher authorities

and becomes harsh for the people who is inferior to him. sometimes he loss self confidence. He fears to meet new people and likes to be in power. He is sensitive also. He smiles when he is helpless. Aversion to undertaking anything new and aversion to undertake any new role with his own work.

Reportorization

1. Mind - Confidence - want of self-confidence
2. Mind - Fear - people; of
3. Mind - Fear-unknown; of the
4. Mind - Hard for inferiors and kind for superior
5. Stomach - Flatulent Food agg.
6. Skin - Discoloration - white spots
7. Generals - food and drinks - salt aversion
8. Generals- food and drinks- sweet aversion

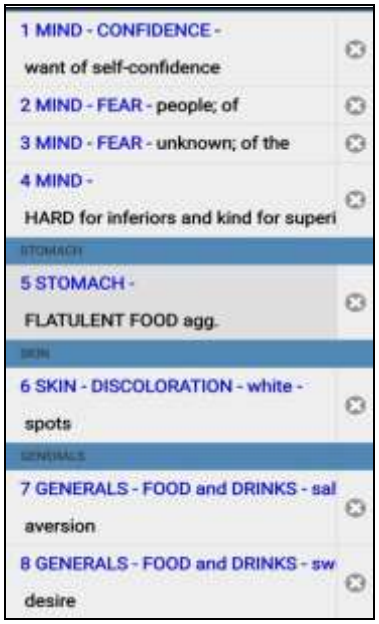

Repertorial Analysis
Lycopodium sepia silicea

Prescription 14/08/2025

Lycopodium 200, BD, 6 doses for 3 days
Sac lac BD for 7days

1st Follow up: 17/09/2025
Patch size reduced
Lycopodium 200, OD, 3 days
SL 30, BD, 7 Days

2nd Follow up: 10/10/2025
PL 200, BD, 15 Days

14/08/2025

17/09/2025

10/10/2025

Discussion
A 26 years old male patient comes with the complain of white patches located on right side of forehead. After complete case taking and individualisation and understanding the patient and formed a totality by synthesis

repertory LYCOPODIUM 200 was prescribed by reference to the materia medica.

Conclusion
This case study gives the reliable proof that homoeopathic medicine can treat depigmentation based on individualisation of patient

Conflict of Interest
There are no conflicts of interest related to this study.

References
1. James WD, Berger TG, Elston DM. Andrews' Diseases of the Skin: Clinical Dermatology. 12th ed. Philadelphia: Elsevier; c2016. p. 89-92.
2. Boericke W. Pocket Manual of Homoeopathic Materia Medica and Repertory. New Delhi: B. Jain Publishers; Reprint; c2018. p. 386-388.
3. Picardo M, Bastonini E. A new view of vitiligo: looking at normal-appearing skin. Journal of Investigative Dermatology. Explains melanocyte dysfunction and disease mechanisms 2015;135(7):1713-1715.
4. Taïeb A, Picardo M. Vitiligo. New England Journal of Medicine. Discusses multifactorial etiology including oxidative stress and neural factors. 2009;360(2):160-169.

How to Cite This Article
Kamble J, Kumre R, Gupta S, Soni HK. A case study on leucoderma treated with constitutional homoeopathy. International Journal of Homoeopathic Sciences. 2026;10(1):231-233.

Creative Commons (CC) License
This is an open-access journal, and articles are distributed under the terms of the Creative Commons Attribution-Non Commercial-Share Alike 4.0 International (CC BY-NC-SA 4.0) License, which allows others to remix, tweak, and build upon the work non-commercially, as long as appropriate credit is given and the new creations are licensed under the identical terms.