



International Journal of Homoeopathic Sciences



E-ISSN: 2616-4493

P-ISSN: 2616-4485

Impact Factor (RJIF): 5.96

www.homoeopathicjournal.com

IJHS 2026; 10(1): 346-349

Received: 09-11-2025

Accepted: 13-12-2025

Dr. Chinmayi Haldankar

Assistant Professor,
Homoeopathic Materia
Medica, at Smt. CMP
Homeopathic Medical College,
Mumbai, India

Corresponding Author:

Dr. Chinmayi Haldankar

Assistant Professor,
Homoeopathic Materia
Medica, at Smt. CMP
Homeopathic Medical College,
Mumbai, India

From constitution to cure: A homoeopathic approach to psoriasis

Chinmayi Haldankar

DOI: <https://www.doi.org/10.33545/26164485.2026.v10.i1.F.2207>

Abstract

Psoriasis is an auto-immune skin condition with multiple remissions and relapses. The main symptoms of psoriasis includes dryness, itching, cracks with occasional bleeding. This paper aims to report a case of palmoplantar psoriasis, where there was cracks, dryness, itching marked more on the soles which was treated constitutional for a period of two years; with no reoccurrence till date.

Keywords: Homeopathy, palmoplantar psoriasis, constitutional treatment, natrum mur

Introduction

Psoriasis is a common papulo-squamous disorder affecting 2% of the population and is characterized by well-demarcated, red scaly plaques. The skin becomes inflamed and hyper proliferates to about 10 times the normal rate. It affects males and females equally and can affect all races. The age of onset occurs in two peaks. Early onset (age 16-22) is commoner and is often associated with a positive family history. Late-onset disease peaks at age 55-60 years ^[1].

There are two key pathophysiological aspects to the abnormalities in psoriatic plaques. Firstly, the keratinocytes hyper proliferate with a grossly increased mitotic index and an abnormal pattern of differentiation involving the retention of nuclei in the stratum corneum. Secondly, there is a large inflammatory cell infiltrate comprising polymorphs, T cells and other inflammatory cells. It is uncertain which of these characteristics is primary ^[2].

The individual lesions are well demarcated and range from a few millimeters to several centimeters in diameter. The lesions are red with dry, silvery-white scaling, which may be obvious only after scraping the surface ^[2]. The Auspitz sign is pinpoint bleeding when a psoriatic scale is forcibly removed. The Woronoff ring is concentric blanching of the erythematous skin at or near the periphery of a healing psoriatic plaque. With the conventional line, the treatment includes topical, systemic or a combination of both ^[3].

As per Homeopathy philosophy, skin diseases are the manifestation of the derangement of the internal organs. If the treatment of the skin are done by external or topical ointment, suppression caused by this practice leads to damage of vital internal organs ^[4].

Clinical case presentation

A 48-years old male presented on 14/05/2022 with complaints of dryness +++ , itching +++ & occ. bleeding+ over B/L soles since a year. There was also itching+ on B/L palms. The complaints are aggravated by scratching & gradually increasing. (Complaints initially started first on soles and recently over palms).

Physical generals: Thermally- Hot patient ++

Mental symptoms

Born & brought up in Bihar, now in Mumbai. Works here in sales department in a company. Lives here with his wife and 2 children. The patient specifically mentioned that the dryness & itching over soles started after the death of his father (a year ago). The patient has a guilt that he could not attend his father's funeral which was Bihar as his daughter was not well. Says this incident constantly runs in his mind. Sometimes, he has dreams of his father. He cries when he is alone, thinking about it. Doesn't like to share his problem with anyone.

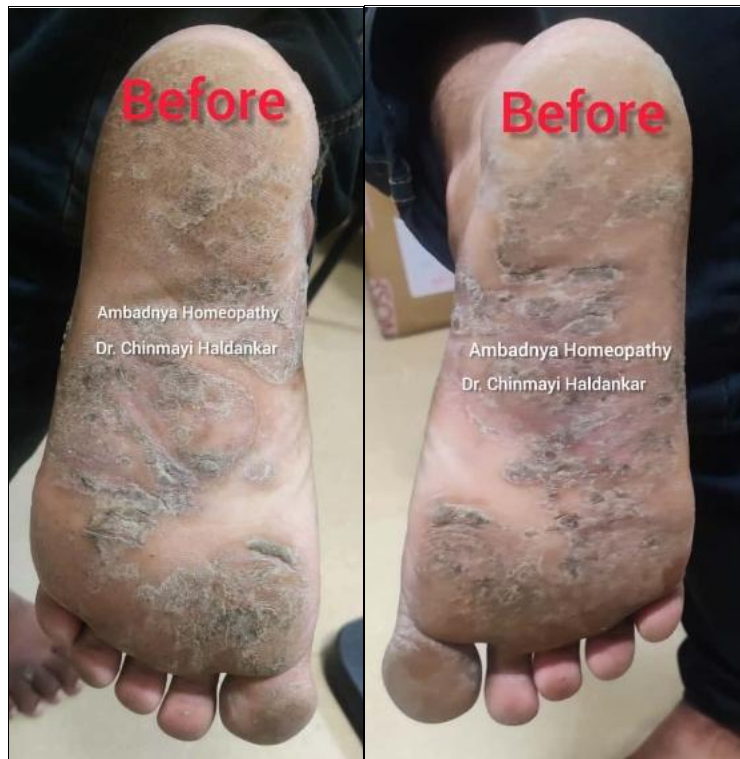

Fig 1: Left sole - before

Fig 2: Right sole - before

Clinical diagnosis: Palmoplantar psoriasis (ICD-10, L40.3)

Homoeopathic classification of symptoms: Dynamic Chronic Miasmatic Disease with Fully Developed symptoms.

Totality

1. A/F: Grief
2. Weeps when alone.
3. Consolation aggravation
4. Hot patient ++
5. Dryness of soles +++
6. Itching of soles +++
7. Itching on palms +

Repertorisation						
Symptoms: 5 Remedies: 99 Applied Filter						
Remedy Name	Nat-m	Sep	Calc	Sil	Ars	Graph
Totality / Symptom Covered	9 / 4	9 / 4	8 / 4	7 / 3	6 / 3	6 / 3
[Kent] [Mind]Grief: (32)	3	1	1		1	2
[Kent] [Mind]Weeping,tearful mood,etc.:Alone,when: (2)	2					
[Kent] [Mind]Consolation :Agg: (23)	3	3	1	3	2	
[Kent] [Skin]Eruptions:Dry: (61)	1	3	3	3	3	2
[Kent] [Skin]Eruptions:Vesicular:Itching: (28)		2	3	1		2

Fig 3: Repertorization sheet - homopath firefly app

Susceptibility: HIGH

1. High symptom similarity.
2. Characteristics at the level of mind and physical.
3. Immunity status of the patient is good.

4. No significant past history or family history.
5. No history of suppression.

Prescription: Natrum Muriaticum 200 (4P) X 15 days; SL 200 T.D.S. X 15 days

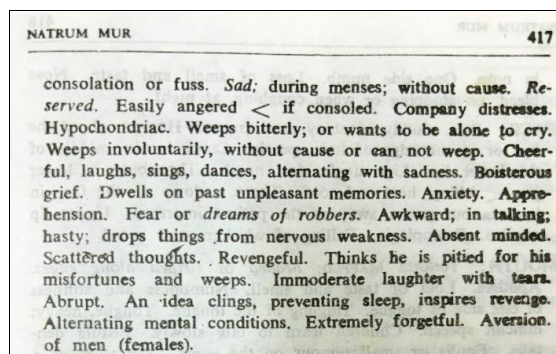


Fig 4: Dr. S.R. Phatak - Materia medica of homeopathic medicines

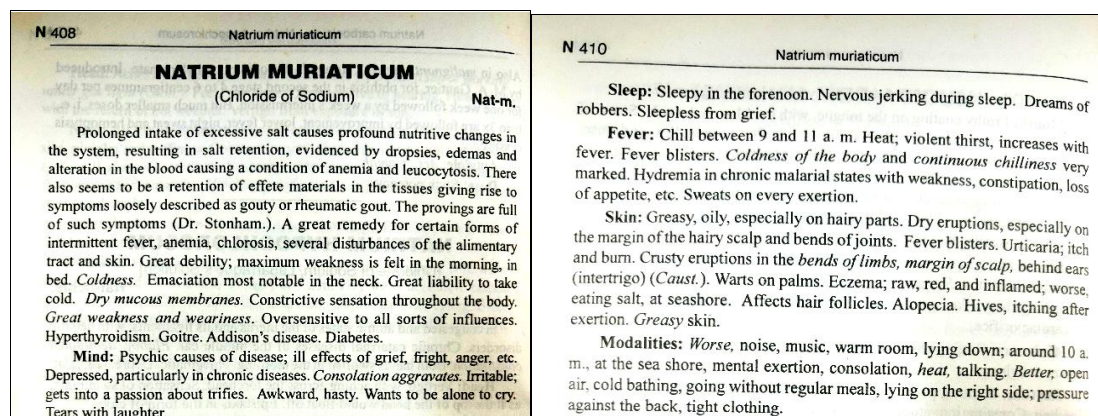


Fig 5&6: William Boericke- Boericke's new manual of homeopathic materia medica with repertory

Follow-up

Table 1: Follow-up table

Date	Symptoms	Rx
28/05/2022	Dryness – > – Itching – SQ – Bleeding occ.	Natrum mur 200 T.D.S x 30 days
01/06/2022	Dryness – > 10% – Itching – > 10% – Bleeding – o –	Natrum mur 200 T.D.S x 30 days
11/07/2022	Dryness – > 20% – Itching – > 20% – Bleeding – o –	Natrum mur 200 T.D.S x 60 days
17/10/2022	Dryness – > 40% – Itching – > 40% – Bleeding – o –	Natrum mur 200 T.D.S x 30 days
07/12/2022	Dryness – > 60% – Itching – > 60% – Bleeding – o –	Natrum mur 200 T.D.S x 60 days
Patient has initial history where the dryness aggravated in winters, but this time he was better.		
25/02/2023	Dryness – > – Itching – << – Bleeding occ.	Psorinum 1M (1P) Natrum mur 200 T.D.S X 30 days
Patient was stressed & was emotional as it was his father's death anniversary & had started recoiling all the past events.		
28/03/2023	Dryness – >> – Itching – o – Bleeding – o –	Natrum mur 200 BD x 3 months
14/07/2023	Dryness – >>> – Itching – o – Bleeding – o –	SL 200 BD x 3 months
23/11/2023	Dryness – >>> – Itching – o – Bleeding – o –	SL 200 OD x 3 months
27/02/2024:	Dryness – 0 – Itching – o – Bleeding – o –	No medicines
Now since past a year and a half the patient had no recurrence & is off medicines.		

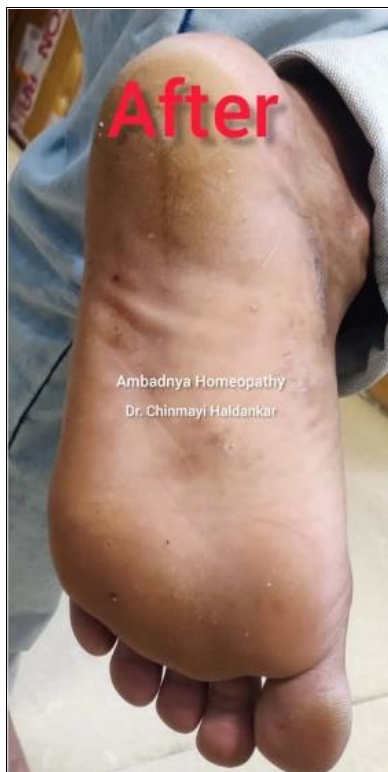

Fig 7: Left sole - after

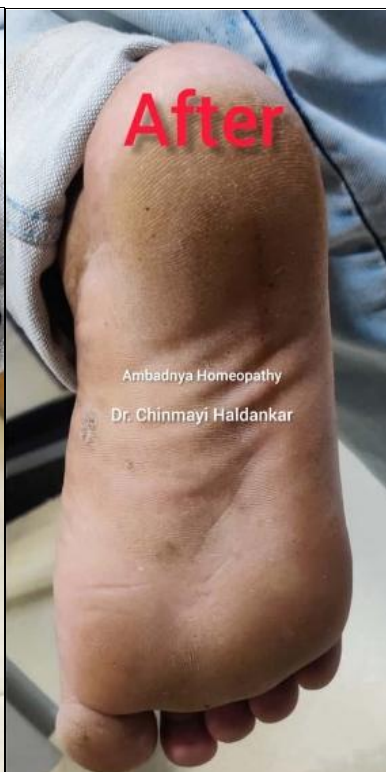

Fig 8: Right sole - after

Discussion

The patient was given a simple single remedy i.e. *Natrum muriaticum* & he responded to the treatment very well; with defined after results. In between the course of treatment *Psorinum 1 M*, an intercurrent medicine was prescribed as the complaints aggravated; as patient had started recoiling past events. But with the following follow-ups; patient responded better with no recurrence of the disease till date & he is off medicines for psoriasis.

Conclusion

The present case demonstrates a favorable clinical outcome in a patient with psoriasis managed through individualized homeopathic treatment, wherein *Natrum muriaticum* was prescribed based on the constitutional totality of symptoms. The patient showed significant improvement with complete resolution of lesions, and importantly, remained free from recurrence during a follow-up period of one and a half years. The sustained remission observed in this case suggests a possible role of constitutional homeopathic intervention in achieving long-term disease control in psoriasis. Although conclusions cannot be generalized from a single case, the findings highlight the need for further well-designed observational studies and controlled clinical trials to evaluate the effectiveness, reproducibility, and long-term outcomes of homeopathic management in chronic inflammatory skin disorders such as psoriasis.

Acknowledgments

A sincere gratitude to Dr. Monhanbhai Patel, Chairman, The Homeopathic Education Society, Vile Parle west, Mumbai. Nayan Patel sir, Vice-Chairman, The Homeopathic Education Society, Vile Parle west, Mumbai. Dr. Asmita Parikh, General Secretary, The Homeopathic Education Society, Vile Parle west, Mumbai. Dr. Sumit Goel, The Principal & Dr. Vanita R. Johari, Prof. & H.O.D. Department of Homeopathic Materia Medica, Smt. C.M.P., Homeopathic Medical College, Vile Parle (west), Mumbai.

References

1. Kumar P, Clark M, editors. Clinical medicine. 5th ed. London (UK): WB Saunders; c2002. p. 1287.
2. Haslett C, Chilvers ER, Boon NA, Colledge NR, editors; Hunter JAA, international editor. Davidson's principles and practice of medicine. 19th ed. Edinburgh: Churchill Livingstone; c2002. p. 1075.
3. Arnold HL, Odom RB, James WD, editors. Andrews' diseases of the skin: clinical dermatology. 8th ed. Philadelphia: W.B. Saunders; c1990. p. 200, 204.
4. Hahnemann S. The chronic diseases, their peculiar nature and their homeopathic cure. New Delhi.
5. Phatak SR. Materia medica of homeopathic medicines. New Delhi: IBPP; c1999. p. 417.
6. Boericke W. Boericke's new manual of homeopathic materia medica with repertory. 3rd rev and aug ed. New Delhi; c2007. Reprint of 9th ed. p. 408, 410.

How to Cite This Article

Haldankar C. From constitution to cure: a homoeopathic approach to psoriasis. International Journal of Homoeopathic Sciences. 2026; 10(1): 346-349.

Creative Commons (CC) License

This is an open-access journal, and articles are distributed under the terms of the Creative Commons Attribution-Non Commercial-Share Alike 4.0 International (CC BY-NC-SA 4.0) License, which allows others to remix, tweak, and build upon the work non-commercially, as long as appropriate credit is given and the new creations are licensed under the identical terms.