International Journal of Homoeopathic Sciences

**E-ISSN:** 2616-4493
**P-ISSN:** 2616-4485
**Impact Factor (RJIF):** 5.96
www.homoeopathicjournal.com
IJHS 2026; 10(1): 445-449
Received: 20-11-2025
Accepted: 25-12-2025

**Dr. Suman Mahawar**
MD (Hom.) Scholar, Department of Organon of Medicine and Homoeopathic Philosophy, Government Homoeopathic Medical College and Hospital, Bhopal, Madhya Pradesh, India

**Dr. Babita Shrivastava**
Professor and HOD, Department of Organon of Medicine and Homoeopathic Philosophy, Government Homoeopathic Medical College and Hospital, Bhopal, Madhya Pradesh, India

**Dr. Suresh Chandra Awasthi**
Professor, Department of Organon of Medicine and Homoeopathic Philosophy, Government Homoeopathic Medical College and Hospital, Bhopal, Madhya Pradesh, India

**Corresponding Author:**
**Dr. Suman Mahawar**
MD (Hom.) Scholar, Department of Organon of Medicine and Homoeopathic Philosophy, Government Homoeopathic Medical College and Hospital, Bhopal, Madhya Pradesh, India

# Cutaneous expression of sycosis: A homoeopathic case of filiform warts

**Dr. Suman Mahawar, Dr. Babita Shrivastava and Dr. Suresh Chandra Awasthi**

**DOI:** https://www.doi.org/10.33545/26164485.2026.v10.i1.G.2224

**Abstract**
**Background:** Warts, considered one-sided diseases, have individual, immunological, and sometimes familial bases. In homoeopathy, they fall under the sycotic miasm and are more than simple local skin manifestations. Effective management requires a holistic approach addressing the whole individual. Treatment is based on the totality of symptoms, including lesion characteristics size, shape, colour, texture, and location as well as the patient's mental, emotional, and physical state. The selected constitutional remedy aims to restore internal balance, treating both the local warts and underlying disturbances. This approach promotes resolution of warts, improves overall health, provides long-term relief, and reduces recurrence by strengthening the body's natural defence mechanisms.
**Case Presentation:** A 32-year-old male presented with multiple pedunculated warts on the neck for six months. The lesions bled on slight touch. The patient also had sensitivity to noise, offensive perspiration, and a chilly constitution.
**Homoeopathic Intervention:** A detailed homoeopathic case assessment and repertorial analysis were carried out based on the totality of symptoms. *Nitric Acid* was selected as the indicated remedy and prescribed in 200C potency with minimal repetition.
**Outcome:** Gradual improvement was noted during follow-up visits, resulting in complete disappearance of the warts without pain, scarring, or recurrence during the observation period.
**Conclusion:** This case suggests that individualized classical homoeopathic treatment may be effective in the management of pedunculated warts and highlights the importance of constitutional prescribing.

**Keywords:** Pedunculated warts; Nitric acid; Homoeopathy; Case report; Sycotic miasm

## Introduction

Warts are among the most common dermatological disorders and are caused by Human Papillomavirus (HPV) that proliferate within the epidermis. The primary source of infection is contact with infected individuals, and transmission usually occurs through direct or close contact. However, the infectivity is low, and casual contact rarely results in transmission. The virus gains entry into the skin through minor or microscopic breaks. Clinically, warts are generally asymptomatic and present in various morphological forms with an irregular verrucous surface, showing slow progressive growth. The number of lesions may range from a single wart to several hundred. Individuals with impaired cell-mediated immunity such as those receiving immunosuppressive therapy or suffering from conditions like Hodgkin's disease, malignant lymphomas, or lymphocytic leukaemia are more prone to developing multiple warts [1].

### The Different Varieties of Warts Include the Following [2]

- **Common Warts or Verruca Vulgaris:** These are characterized by firm, skin colour papules of various sizes with verucous surfaces and can occur on any parts of the body but are most commonly present on the dorsum of the hands and fingers.
- **Plain Warts or Verruca Plana:** It presents as skin colored, slightly raised flat -topped papules and are usually present on dorsum of hand and face.
- **Filiform Warts:** These are finger like projections with irregular surface and are usually seen on the neck, face and scalp.
- **Plantar warts:** These are found on any part of the sole. The lesions are occasionally painful. The warts present as skin colored well defined areas in the sole with irregular surface.

- **Genital warts:** These warts are usually transmitted through sexual contact. These are present as fungating masses of verucous tissue. They usually present on glans penis, corona, mucosal surface of prepuce and occasionally on the urinary meatus in males and the vulva and vaginal openings in the females.
- **Molluscum Contagiosum:** Large virus belonging to the pox group of viruses causes it. It gets implanted on the skin by contact with an infected individual.

**Warts and Homoeopathy**

Warts are benign epidermal proliferations caused by human papillomavirus (HPV) infection and are understood in homoeopathy as external manifestations of an underlying constitutional and miasmatic disturbance, predominantly of the sycotic miasm [3]. Homoeopathic management emphasizes an individualized, constitutional approach rather than local destruction of lesions, aiming to stimulate the patient's vital force and restore immune balance. Remedies such as Thuja occidentalis, Nitricum acidum, Causticum, and Antimonium crudum are commonly indicated based on the totality of symptoms, including physical generals, mental characteristics, and the specific morphology and location of warts. According to homoeopathic philosophy, suppression of warts by local measures may lead to deeper pathological states, whereas constitutional treatment promotes gradual regression of lesions with reduced tendency to recurrence.

**Case summary:** A case of 22 years old male patient OPD no. 6997/61 residing at Neelbad, Bhopal, Madhya Pradesh was selected from the Homoeopathic OPD at government homoeopathic medical college and hospital, Bhopal, M.P. which is taken according to standardized homoeopathic format. During the period 17/06/2025 to 28/12/2025, the patient suffering from warts on neck area. The cases were recorded by keeping the individualistic and holistic concepts in mind.

The data was collected by performing a history and physical examination of the patient, which included the following:

a) Preliminary data
b) Presenting duration of complaints, in brief chronological order.
c) Details of complaints were recorded with special reference to onset, progress, and causative factors.
d) Past medical history, if any, in chronological order to determine the miasmatic background of the patient.
e) Past medical history including mental reactions, desires and aversions, aggravation to any particular food, habits, appetite, thirst, bowel movements, and perspiration.
f) Family history to illuminate the miasmatic background of the patient for any disease or disorders running in the family inherited or acquired.

**Chief complaint:** Patient was complaining of multiple pedunculated warts on the left side of neck, present for 6 months, with bleeding on slight touch.

**Concomitants:** Nil

**Associated complaints:** Nil

**Origin, duration, and progress of the case-** The patient reported noticing small skin-colored outgrowths on the neck six months ago. Gradually, the lesions increased in size and number, becoming pedunculated. The warts occasionally bled on minor trauma (e.g., while dressing or shaving) and caused mild irritation. There was no pain, discharge, or inflammation. No prior treatment had been undertaken.

**Past medical history:** Jaundice 4 years ago.

**Family History**

- Father- Teacher - Suffers from hypertension
- Mother-Homemaker- Healthy
- Brother- doing B.Sc. - not specific illness

**Personal History**

- **Addictions:** No such
- **Occupation:** Pharmacist
- **Accommodation:** well-ventilated house
- **Diet:** Vegetarian
- **Socio-economic condition:** Medium
- **Habit and Hobbies:** Nothing significant
- **Marital status:** Unmarried
- **Relation with family members and in the field of occupation:** Good
- **Behaviour during childhood:** Normal

**Physical Generals**

- **Appearance**: Average build, well nourished.
- **Appetite:** Good, can tolerate hunger.
- **Thirst:** Normal 2.5-3 litre per day
- **Taste of mouth:** No abnormal taste of mouth
- **Desire:** Salt
- **Aversion:** not specific
- **Intolerance:** N/S
- **Salivation:** not specific
- **Stool:** Day ( once ) Night (0), Clear, Regular, No Peculiar odour
- **Urine:** Day ( 7 -8 ), night (0-1 ), clear, Normal Stream, No Peculiar odour
- **Perspiration:** whole body, Non - staining, offensive.
- **Discharge, if any:** Nothing specific
- **Sleep and Dreams:** Sound sleep, take 6-8 hours sleep, prefer to lying on the right side
- **Thermal Reaction:** chilly
- **General Modalities:** Aggravation on touch
- **General Sensation and Complaints:** No such
- **General Tendencies:** No such

**Mental Generals**

- Sensitive to noise
- Mild anxiety regarding appearance

**Vital Parameter / Physical Examination**

- Pulse: 78 beats/minute
- B.P.:120/82 mmHg
- Respiration: 16/minute
- Temperature: 98.6°F

**Local Examination of the Skin**

- Location of warts - Left side on the neck region
- Number of warts - Multiple, 10-12 warts on the left side of the neck region.
- Pattern of distribution - On exposed area, in group on right side of neck.
- Characteristics of warts - Pedunculated warts
- Shape of warts - Round

- Surface of warts - Smooth
- Pain - on touch when they bleed.
- Discharge - Bleeding seen on touch
- Itching - Occasionally present
- Other systemic examinations were normal.

**Provisional Diagnosis**

The definitive diagnosis of viral warts was based on characteristic manifestations, morphology and distribution of lesions, following the guidelines of ICD-10, code B-07.

**Confirmed Diagnosis**

Pedunculated warts (Verruca vulgaris, Filiform variety)

**First Visit - 04/12/2025**

**Miasmatic Diagnosis**

| S.No. | Symptoms | MIASM |
|---|---|---|
| 1. | Sensitive to noise | psora |
| 2. | Chilly patient | psora |
| 3. | Desire for salt | psora |
| 4. | Offensive perspiration | psora |
| 5. | Pedunculated warts on neck | sycosis |
| 6. | Warts bleed on slight touch | syphilis |

**Evaluation of Symptoms**

**Analysis and Evaluation of Symptoms according to:** J. T. KENT

| A) Mental General | Sensitive to noise |
|---|---|
| B) Physical General | • Desire for salt<br>• Thermal reaction - Chilly<br>• Offensive perspiration |
| C) Characteristic Particular | • Pedunculated warts on neck<br>• Warts bleed on slight touch |

**Totality of Symptoms**

1. Sensitive to noise.
2. Desire for salt.
3. Thermal reaction - Chilly.
4. Offensive perspiration.
5. Pedunculated warts on neck.
6. Warts bleed on slight touch.

**Conversion of Symptoms into Rubrics**

| S.No. | Symptoms | Rubrics |
|---|---|---|
| 1. | Sensitive to noise. | MIND- SENSITIVE-noise, to |
| 2. | Desire for salt | GENERALS- FOOD AND DRINKS- salt - desitre |
| 3. | Thermal reaction - Chilly. | GENERALS-HEAT-lack of vital heat |
| 4. | Offensive perspiration. | PERSPIRATION - ODOR- offensive |
| 5. | Pedunculated warts on neck. | SKIN-WARTS-pedunculated<br>NECK-WARTS |
| 6. | Warts bleed on slight touch. | SKIN-WARTS-bleeding-touch agg. |

**Repertorial Analysis**

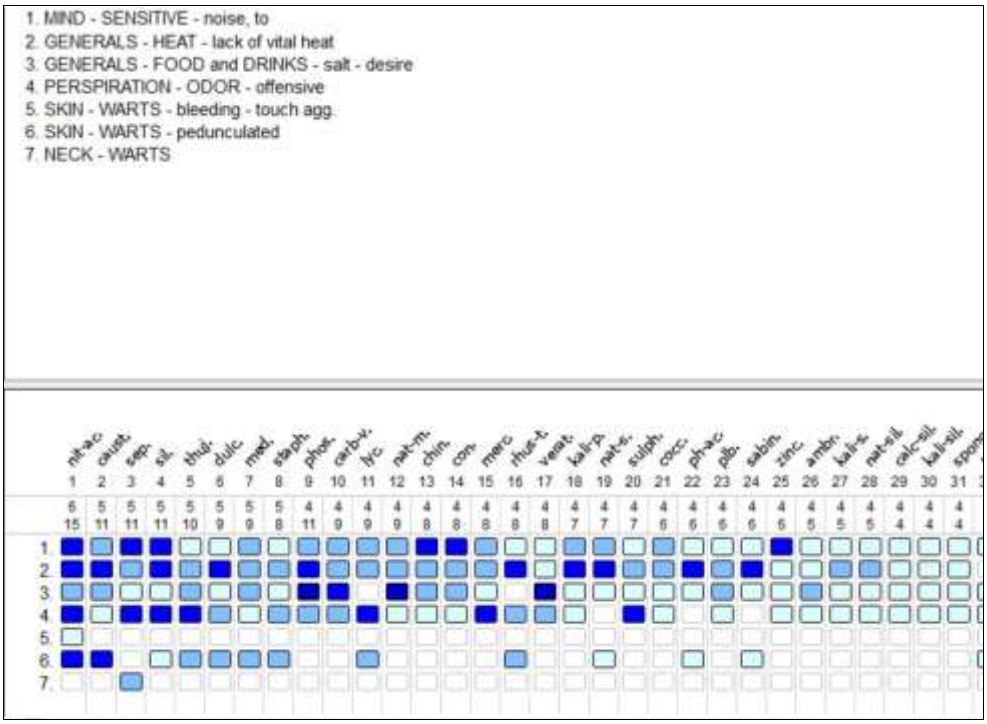

**Final Selection of Medicine (In Consultation with Materia Medica)**

After repertorization, NITRICUM ACIDUM possessed the highest grade and highest matching of the symptoms. Considering all the aspects of the case and consultation with Materia Medica "Nitric acid" was found to be the final selection for a prescription.

**Prescription**

℞

Nitric acid 200/1 drachm, once daily for 2 days

Rubrum-200/1 drachm, once daily for 7 days

**Auxiliary Treatment**

- **Hygiene and Local Care**
  Maintain cleanliness of the affected area, keep it dry, and avoid friction, trauma, or manipulation of warts to prevent bleeding, secondary infection, and spread.
- **Preventive Measures**
  Avoid sharing personal items such as towels and razors; exercise caution while shaving to prevent injury and autoinoculation.

**Follow Up**

| Date | Observation | Response | Treatment | Remarks |
|---|---|---|---|---|
| 12/12/2025 | Bleeding stopped; no increase in size or number of warts; perspiration slightly less offensive. | Positive | Rx<br>Sac lac 200<br>4 pills BD for 10 days. | improvement in local and general symptoms |
| 22/12/2025 | Warts reduced in size; drying at base of lesions; no bleeding | Marked improvement | Rx<br>SAC LAC 30<br>4 pills BD for 7 days. | Remedy action progressing; no repetition required. |
| 30/12/2025 | Few warts shriveled and detached; remaining warts very small. | Marked improvement | Rx<br>SAC LAC 200<br>4 pills BD for 7 days. | Continued regression of lesions; general well-being improved. |
| 07/01/2026 | Complete disappearance of warts; skin healed; general well-being improved. | Complete recovery | No medicine needed | Cure achieved; patient advised follow-up observation. |

**Discussion**

Warts are considered manifestations of internal miasmatic disturbance in homoeopathy, predominantly related to the sycotic miasm. In the present case, pedunculated warts on the neck with a tendency to bleed on slight touch indicated sycotic involvement with syphilitic traits. Individualization was achieved by considering characteristic mental and physical generals such as sensitivity to noise, offensive perspiration, and a chilly thermal reaction. Based on the totality of symptoms, Nitric Acid was selected as the constitutional remedy due to its strong affinity for bleeding, pedunculated warts and offensive secretions. The patient showed progressive improvement following a single dose, with gradual regression and complete disappearance of the lesions. The absence of recurrence and improvement in general health support the homoeopathic principle that treating the individual as a whole leads to lasting cure rather than local suppression.

**Conclusion**

Individualized homoeopathic treatment based on the totality of symptoms resulted in complete resolution of pedunculated warts in this case. Nitric Acid acted curatively by addressing both local manifestations and the underlying constitutional imbalance. The absence of recurrence and improvement in general health support the holistic approach

of homoeopathy. This case highlights the importance of constitutional prescribing in chronic skin disorders.

**Declaration of Patient Consent:** Patient consent form was obtained. The patient has given her consent for images and report and other clinical information to be reported in journal, patient understands, her name not to be published, and due effort was made to conceal her identity.

**Conflict of Interest:** The author has no conflict of interest related to the study to disclose.

**Financial Support:** The author received no financial support, sponsorship, or grants related to the study to disclose.

## References

1. https://homeopathy.delhi.gov.in/homeopathy/warts.
2. Boericke, W. Pocket Manual of Homoeopathic Materia Medica and Repertory. 9th ed. New Delhi: B. Jain Publishers.
3. Hahnemann, S. Organon of Medicine. 6th ed., translated by William Boericke. New Delhi: B. Jain Publishers; Aphorisms 3, 5, 7, 78- 81.

**How to Cite This Article**
Mahawar S, Shrivastava B, Awasthi SC. Cutaneous expression of sycosis: A homoeopathic case of filiform warts. International Journal of Homoeopathic Sciences. 2026; 10(1): 445-449.

**Creative Commons (CC) License**
This is an open-access journal, and articles are distributed under the terms of the Creative Commons Attribution-Non Commercial-Share Alike 4.0 International (CC BY-NC-SA 4.0) License, which allows others to remix, tweak, and build upon the work non-commercially, as long as appropriate credit is given and the new creations are licensed under the identical terms.