



# International Journal of Homoeopathic Sciences

E-ISSN: 2616-4493

P-ISSN: 2616-4485

[www.homoeopathicjournal.com](http://www.homoeopathicjournal.com)

IJHS 2020; 4(4): 143-147

Received: 06-08-2020

Accepted: 14-09-2020

**Dr. Punam Kumari**

Dr. D.P. Rastogi Central  
Research Institute for  
Homoeopathy, Noida, Uttar  
Pradesh, India

## Hemorrhagic ovarian cyst treated with constitutional Homoeopathy: A case report

**Dr. Punam Kumari**

### Abstract

Hemorrhagic ovarian cyst is an adnexal mass formed because of occurrence of bleeding into a functional ovarian cyst. A hemorrhagic ovarian cyst is the most common cause of acute pelvic pain in an afebrile, premenopausal woman presenting to the emergency room and need surgical removal with conventional treatment while Homoeopathy provides painless, safe and cost-effective treatment for Hemorrhagic Ovarian cyst.

**Keywords:** Homoeopathy, Hemorrhagic cyst, *Conium maculatum*

### Introduction

Hemorrhagic ovarian cysts (HOCs) is an adnexal mass formed because of occurrence of bleeding into a functional ovarian cyst as follicular or corpus luteum cyst. It is commonly seen in clinical practice because hemorrhage into a cyst is usually painful, triggering the patient to consult her physician <sup>[1, 2]</sup>. Most of HOCs are functional, few of them can be neoplastic but they are universally benign <sup>[3]</sup>. Hemorrhagic ovarian cysts occur almost exclusively in premenopausal women and in postmenopausal women receiving hormonal treatment. They can occur during pregnancy. Although HOCs are not common in early adolescence, they are occasionally seen in childhood <sup>[1, 4]</sup>.

**Patho-physiology:** Hemorrhagic ovarian cysts typically develop as a result of ovulation. The granulosa layer of the ovary remains avascular until the time of ovulation. After the oocyte has been expelled, the Graafian follicle develops into a corpus luteum with a highly vascular and fragile granulosa layer, which ruptures easily, forming a hemorrhagic ovarian cyst <sup>[1, 5]</sup>.

### Clinical presentation

Patients may present with pelvic mass, sudden-onset of pelvic, or lower abdominal pain which can wake the woman from her sleep or they may be asymptomatic <sup>[1, 4]</sup>.

### Diagnosis, treatment and prognosis

Hemorrhagic cysts are diagnosed by abdominal or transvaginal USG. Most hemorrhagic cysts resolve completely within two menstrual cycles (8 weeks). In the postmenopausal patient, surgical evaluation is warranted <sup>[1]</sup>.

### Complications of Hemorrhagic Cysts

- 1. Rupture of a Hemorrhagic Ovarian Cyst:** When a hemorrhagic cyst ruptures, result in massive hemoperitoneum.
- 2. Torsion of a Hemorrhagic Ovarian Cyst:** Adnexal torsion due to a hemorrhagic cyst is rarely encountered but has been occasionally reported <sup>[4]</sup>.

**Homoeopathic approach:** According to homoeopathy, whatever may be the name of the disease we select our similimum on the basis of totality of the symptoms that is outwardly reflected picture of the internal essence of the disease, that is of the affection of the vital force <sup>[7, 9]</sup>.

### Case presentation

A 26yrs old, Hindu, housewife came to the OPD of our institute on 10/02/2020. She was suffering from constant cramping pain in lower abdominal that aggravated during menses for 1 year.

**Corresponding Author:**

**Dr. Punam Kumari**

Dr. D.P. Rastogi Central  
Research Institute for  
Homoeopathy, Noida, Uttar  
Pradesh, India

She was having late and scanty menses. She was also having complaints of vertigo especially in morning when she woke from sleep with sensation of everything is moving in a circle while turning, reeling sensation while standing and severe constipation.

**Mental generals:** Anger at trifles, brooding nature, irritability of mind especially during menses, wants to be alone.

**Physical general**

Appetite was good, thirst was normal, had no specific desires and aversions, clean and moist tongue, Her stool was hard, passed with difficulty with ineffectual urge, urine was clear, moderate perspiration, sound sleep.

**Menstrual and obstetric history:** menses was late, scanty and painful. LMP- 27/01/2020

She has a 2 yrs. old daughter, no history of abortion or miscarriage.

**Particulars:** Pain in pubic region indicating pain in ovaries, cramping pain in lower abdomen, vertigo in morning after waking, reeling sensation while standing with sensation as if everything turning in circle, cyst in ovary.

**Past history:** NP

**Family history:** NP

**Evaluation of symptoms**

- Anger at trifles
- Brooding nature
- irritability especially during menses

- Wants to be alone
- Ineffectual urging and straining while passing stools.
- Hard stools.
- Menses late and scanty.
- Pain in pubic region indicating pain in ovaries during menses.
- Cramping pain in lower abdomen aggravated during menses.
- Vertigo in morning after waking, reeling sensation while standing, sensation as if everything is turning in circle.
- Cyst in ovary.

**Miasmatic analysis** [6, 7, 8].

**Psoric Miasm**

- Anger at trifles.
- Irritability especially during menses.
- Ineffectual urging and straining while passing stools.
- Hard stools.
- Menses late and scanty.
- Cramping pain in lower abdomen aggravated during menses.
- Vertigo.

**Sycotic miasm**

- Brooding nature.
- Cyst in ovary.

Predominant miasms was psoro-sycotic.

**Repertorization** [10].

Repertorization was done by using RADAR 10 Software for windows; Schroyens F; Synthesis, shown in table 1

**Table 1:** Show the analysis contains radar remedies and Symptoms

me (201) untitled This analysis contains 497 remedies and 13 symptoms. Intensity is considered		Sum of symptoms (sort:deg)																
		01.	02.	03.	04.	05.	06.	07.	08.	09.	10.	11.	12.	13.	14.	15.	16.	17.
		12	10	10	10	10	9	9	9	9	8	8	8	8	8	7	7	7
		21	20	18	17	17	19	15	14	11	16	16	16	14	9	14	12	12
		con.	nat-r.	lyc.	bell.	plat.	nux-v.	sep.	calc.	acon.	bry.	lach.	phos.	sulph.	kola	graph.	cocc.	rhus-l.
01.	MIND - ANGER - trifles; at	█																
02.	MIND - BROODING	█																
03.	MIND - IRRITABILITY - menses - during	█																
04.	MIND - COMPANY - aversion to	█																
05.	RECTUM - CONSTIPATION - ineffectual urging and straining	█	█	█	█	█	█	█	█	█	█	█	█	█	█	█	█	█
06.	STOOL - HARD	█	█	█	█	█	█	█	█	█	█	█	█	█	█	█	█	█
07.	FEMALE GENITALIA/SEX - MENSES - late, too - scanty	█																
08.	FEMALE GENITALIA/SEX - PAIN - Ovaries - menses - during	█																
09.	FEMALE GENITALIA/SEX - TUMORS - Ovaries - cysts	█																
10.	ABDOMEN - PAIN - cramping, griping - Hypogastrium - menses - during	█																
11.	VERTIGO - MORNING - rising - on	█																
12.	VERTIGO - REELING - standing	█																
13.	VERTIGO - TURNING; as if - everything were turning in a circle; as if	█																

**Prescription:** *Conium maculatum* 1M/2 Doses/OD on 10/02/2020 followed by Sac Lac for seven days.

and the characteristic symptoms of the drug.

**Basis of Prescription**

The medicine was prescribed on the basis of Repertorization

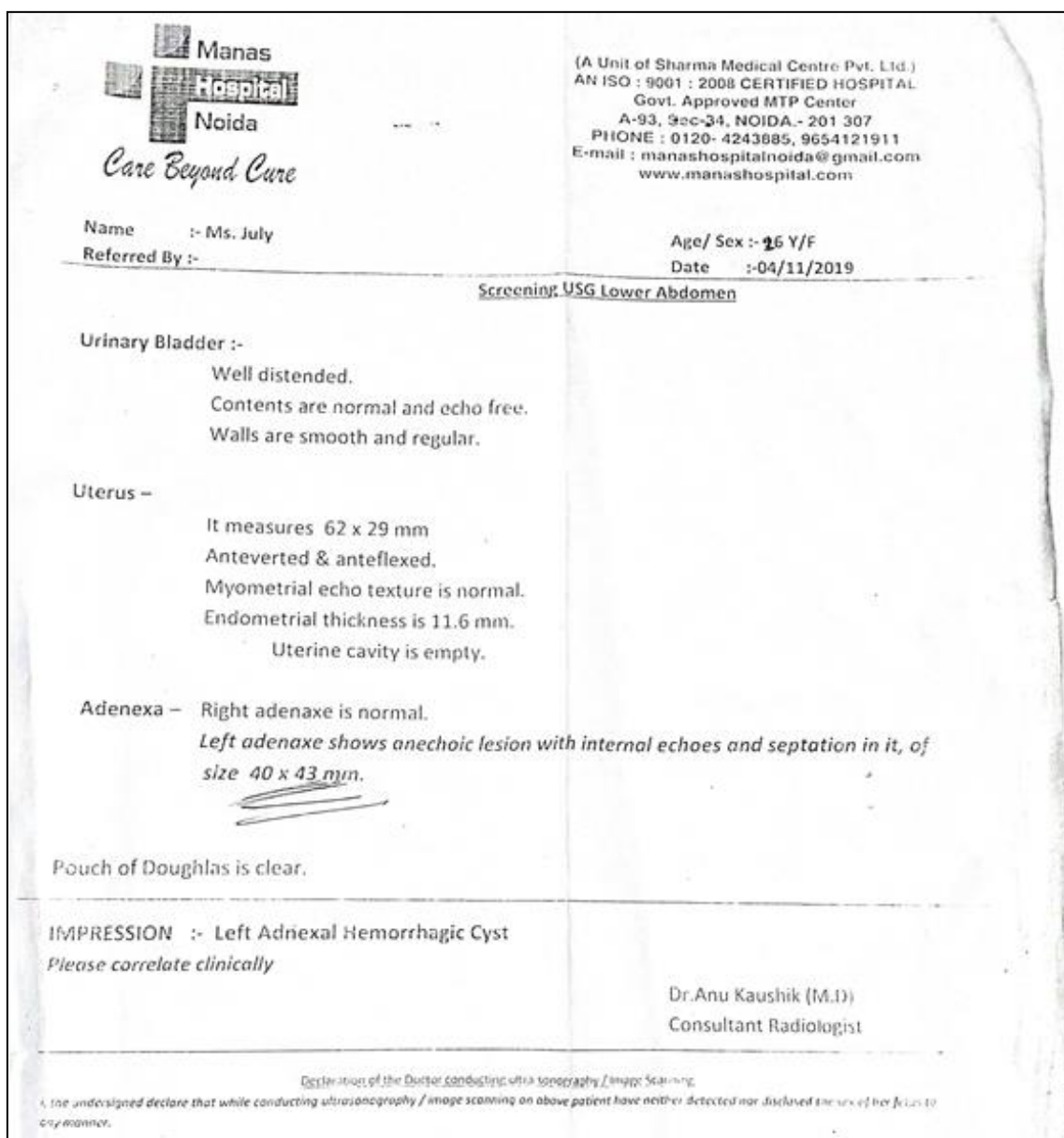
**Follow- ups:** done at regular interval. Follow- up chart shown in table 2

**Table 2:** follow-ups



Date	Symptoms	Prescription
18/02/20	Pain in lower abdomen was same, vertigo better, constipation -better	Sac Lac/TDS/7 Days
03/03/20	Pain in lower abdomen was same, other symptoms were slightly better	<i>Conium maculatum</i> 1M /1 Dose followed by Sac Lac/TDS for 7 days
13/03/20	pain in lower abdomen was better LMP- 07/03/20, menstrual pain was better than before with moderate flow, vertigo and constipation were better than before, mental generals were same	Sac Lac/TDS/7 DAYS
20/03/20	Pain in lower abdomen was much better, vertigo was absent, constipation was much better	Sac Lac/ TDS/15 Days

USG of whole abdomen done on 13/03/20 shown no evidence of any cystic or solid mass lesion on either side

while the previous report shown left adenexal anechoic lesion of size 40x43 mm done on 04/11/19.



**Fig 1:** USG report before treatment

 <b>Manas Hospital</b> Noida <i>Care Beyond Cure</i>	(A Unit of Sharma Medical Centre Pvt. Ltd.) AN ISO : 9001 : 2008 CERTIFIED HOSPITAL Govt. Approved MTP Center A-93, Sec-34, NOIDA.- 201 307 PHONE : 0120- 4243885, 9654121911 E-mail : manashospitalnoida@gmail.com www.manashospital.com
Name:- Ms.Juli	Age/ Sex :- 26 Y/F
Referred By :-	Date:- 13/03/2020
<u>Screening USG Lower Abdomen</u>	
Urinary Bladder :-	Well distended. Contents are normal and echo free. Walls are smooth and regular.
Uterus -	It measures 61 x 33 mm Anteverted & anteflexed. Myometrial echo texture is normal. Endometrial thickness 5mm Uterine cavity is empty.
Adenexa -	Both adenaxa are normal.
Ovaries -	Normal in size , shape and position. No evidence of any cystic / solid mass lesion on either side.
Pouch of Douglas is clear.	
<b>IMPRESSION :- Normal Study</b> <i>Please correlate clinically</i>	
Dr. Anu Kaushik (M.D) Consultant Radiologist 	
<small>Declaration of the Doctor conducting ultra sonography / Image Scanning</small> <small>I, the undersigned declare that while conducting ultrasonography / image scanning on above patient have neither detected nor disclosed the sex of her fetus to any manner.</small>	

**Fig 2:** USG report: After treatment

### Discussion

Hemorrhagic ovarian cyst is a kind of disease which needs surgical intervention on emergency basis. Homoeopathy treats patient as a whole and helps in such cases to avoid surgery if prescribed after proper case taking and on basis of totality of symptoms. Even Most of the hemorrhagic ovarian cysts are self-limiting disease, usually resolve within two weeks but in this case, there was no spontaneous resolution has observed as patient was suffering from 1 year even after the conventional treatment and she was advised for surgery and patient was responded well with constitutional Homoeopathic medicine, *Conium maculatum*.

A very few articles have published on this topic, though Homoeopathy offers a wide range of constitutional medicines for pain free resolution of Hemorrhagic ovarian cyst, therefore it needs to treat more and more cases of HOCs with constitutional Homoeopathy to validate the effect of Homoeopathic treatment in coming future.

### Conclusions

Hemorrhagic ovarian cysts are essentially “surgical” lesions, and in most cases with correct sonographic diagnosis, and symptomatic Homoeopathic treatment can effectively

manage the case without need of surgery. This case again justifies the individualistic concept of homoeopathy.

**Conflicts of interest:** none

### References

1. Iqbal Subhan, Radswiki *et al.* available from <https://radiopaedia.org/articles/haemorrhagic-ovarian-cyst>
2. Hemorrhagic Ovarian cyst available from <http://edelweisspublications.com/keyword/29/1435/Hemorrhagic-ovarian-cyst>
3. Ahmad M Abbas, Mariam T Amin, Sara M Tolba, Mohamed K Ali. available from <https://www.sciencedirect.com/science/article/pii/S1110569015300157>
4. Jain A. Kiran, Sonographic spectrum of Hemorrhagic ovarian cyst available from <https://onlinelibrary.wiley.com/doi/full/10.7863/jum.2002.21.8.879>
5. Ross Elisa, Fortin Chelsea, Ovarian Cyst, available from <http://www.clevelandcliniced.com/medicalpubs/dis>

- easemanagement/womens- health/ovarian-cysts/
6. Banerjea SK. Miasmatic prescribing, 2<sup>nd</sup> extended edition. Jain Publishers P) LTD, USA Europe-India, 2006.
  7. Babu Nagendra G. Comprehensive study of Organon, 1<sup>st</sup> Edition, B. Jain Publishers P) LTD, 2009.
  8. Allen JH. the Chronic Miasm, vol-1 and 2, B. Jain Publishers P) LTD, 2003.
  9. Sarkar BK. organon of medicine, 8<sup>th</sup> Indian edition, M. Bhattacharyya & co. (P) ltd, Calcutta, 1984.
  10. Radar 10-EH. Belgium: Archibel homeopathic software, 2009.