



International Journal of Homoeopathic Sciences

E-ISSN: 2616-4493

P-ISSN: 2616-4485

www.homoeopathicjournal.com

IJHS 2021; 5(1): 79-81

Received: 07-11-2020

Accepted: 11-12-2020

Dr. Subhash Chand Yadav
Professor, PG Guide,
Department of Repertory,
Swasthya Kalyan
Homoeopathic Medical College
and Research Centre, Sitapura,
Jaipur, Rajasthan, India

Dr. Anshuman Kankoriya
M.D. (PGR), Department of
Repertory, Swasthya Kalyan
Homoeopathic Medical College
and Research Centre, Sitapura,
Jaipur, Rajasthan, India

A case report of tinea corporis treated by individualized homoeopathic medicine

Dr. Subhash Chand Yadav and Dr. Anshuman Kankoriya

Abstract

It is a superficial fungal skin infection of the body which caused by dermatophytes. It is defined by location of lesion that may be present on neck, arms, trunk & legs. It is manifested by pruritus & rashes. A 30 year male reported with complaints of rashes with pruritus. Case taking was done followed by repertorization using BBCR and sepia officinalis was given as a individualized medicine.

Keywords: Homoeopathy, tinea corporis, BBCR, RADAR

Introduction

Tinea corporis is a superficial fungal skin infection of the body caused by dermatophytes. It is defined by the location of the lesions that may be present on the trunk, neck, arms, and legs. There are some alternative names which is also caused by dermatophytes that affect the other areas of the body. These alternatives include the scalp (tinea capitis), the face (tinea faciei), hands (tinea manuum), the groin (tinea cruris) and feet (tinea pedis). It is commonly present worldwide. Excessive heat, high relative humidity and fitted clothing have correlations to more severe and frequent disease [1].

Patient may have variable symptoms. Sometime patient can be asymptomatic. Pruritus, annular plaque is the characteristic of tinea corporis. Sometime occasionally patient can experience a burning sensation in eruptions [2].

The eruption especially present on skin of neck, trunk and extremities. On physical examination, lesions are usually circular or ovoid in appearance with patches and plaques. These lesions present as a sharp margins with raised erythematous scaly edge which may contain vesicles [1].

Case study

Mr. XY, 30 year, Male, Fatty with fair color, Hindu-Brahmin, Unmarried, Vegetarian, Student (Preparation), attended the out-patient department of the Swasthya kalyan homoeopathic medical college and research centre pratap nagar, Jaipur (Rajasthan) present himself with the following complaints on 12/07/2019, complaining of an itchy skin eruption on thigh and right hand. He said that at various time different areas of the body had been involved by a similar process but that such areas had cleared up spontaneously after ointment application.

The following cutaneous lesion were found on examination

He present an eruption on extensor surface of hand, forearm & on the thigh. The lesions are essentially papular, scaly and erythematous in appearance. The larger patches of eruptions are irregular in size and shape. The small lesion are rounded. The border of the lesions are sharply demarcated and erythematous.

The patient felt itching and burning on eruptions.

Itching < after scratching, bathing after, sweat after, undressing when.

Burning < Scratching after.

> not specific.

The patient told that he is very irritable and anxious in nature.

Thermal - chilly

Regarding his past history the patient further reported that he had suffered from repeated attacks of common cold of which he was cured of after taking allopathic treatment.

The patient had strong desire for taking sour things which aggravated the rashes. He was addicted to chewing tobacco and smoking. The patient's father was also suffering from

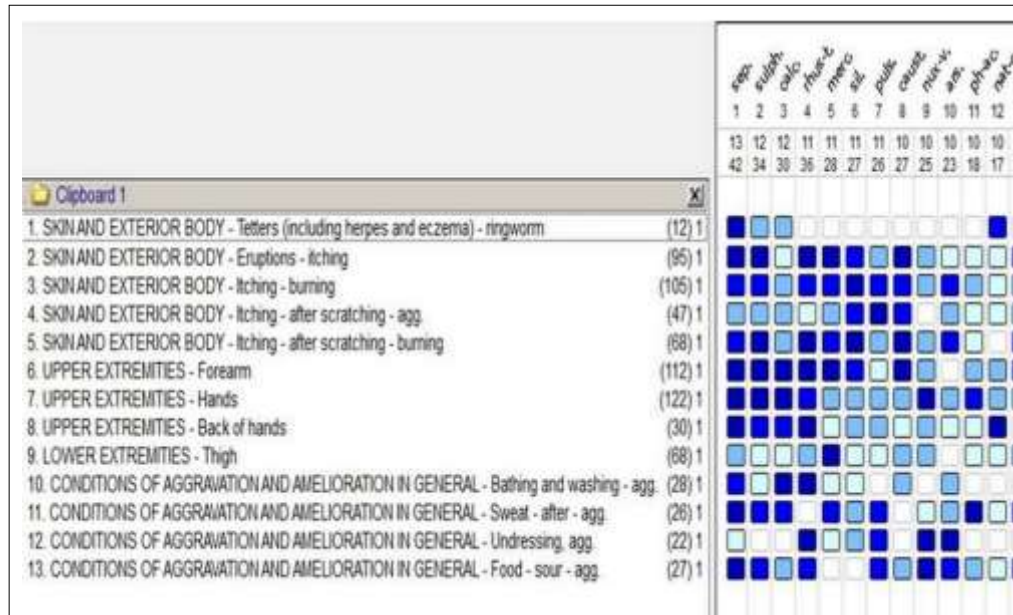
Corresponding Author:
Dr. Subhash Chand Yadav
Professor, PG Guide,
Department of Repertory,
Swasthya Kalyan
Homoeopathic Medical College
and Research Centre, Sitapura,
Jaipur, Rajasthan, India

ringworm since 2 yrs. and he was also taking allopathic treatment on that time. His mother had a history of thyroid and hypertension since 20 years.

A close study of the patient case-history showed that in comparison to physical generals and other symptoms, pathological generals were more prominent. Hence the case was analyzed, evaluated and repertorised by the BBCR/RADAR for which following rubrics were chosen:

1. Skin and exterior body- Tettors (Including herpes and eczema) – ringworm.
2. Skin and exterior body- Eruption – itching.
3. Skin and exterior body- Itching – burning.
4. Skin and exterior body- Itching – after scratching – agg.
5. Skin and exterior body- Itching – after scratching –

- burning.
6. Upper extremities- Forearm.
7. Upper extremities- Hands.
8. Upper extremities- Back of hands.
9. Lower extremities- Thigh- upper.
10. Condition of aggravation and amelioration in general- Bathing and washing- agg.
11. Condition of aggravation and amelioration in general- Sweat- after- agg.
12. Condition of aggravation and amelioration in general- Undressing, agg.
13. Condition of aggravation and amelioration in general- Food- sour- agg.



Remarks: 1. Sepia officinalis – 42/13, 2. Sulphur – 34/12, 3. Calcarea Carbonica – 30/12, 4. Rhus toxicodendron – 36/11, 5. Mercurius solubilis – 28/11

Note: Sepia officinalis covers maximum symptoms and get highest marks so indicated medicine is sepia officinalis.

Fig 1: Showing repertorisation of case from BBCR using RADAR 10.0

Treatment and Management

Sepia officinalis for the treatment of tinea corporis were given. The treatment continued approximate for 8 months. Patient advised to apply coconut oil locally on affected part. Sepia officinalis were given after repertorisation by BBCR (RADAR) and to observe after illness and the advice to avoid those particular factors which caused aggravation of the disease.

The patient felt better in itching and burning. He was

significantly improved. There are no eruption present on hand, thigh and other part of body. More than 10 months have passed away the patient has not turned up to complain about the re-appearance of any of the ailments and not reported again for of which he was previously suffered from tinea corporis eruptions.

On repertorisation by BBCR (RADAR), Sepia officinalis emerged out as the desired medicine which covered not only all the 13 rubrics, but also secured the highest marks 42/13.

Table 1: Follow-up details

S. No.	Date	Observation and Assessment	Prescription
1.	12/07/2019	Rashes with severe itching and burning since one year. Rashes present on right hand, thigh. < After scratching, bathing after, sweat after, undressing when, sour food. > N/S	Sepia officinalis 30 OD x 2 days Rubrum 30 TDS x 15 days
2.	27/07/2019	Slightly Improvement in itching. Burning after scratching is standstill.	Rubrum 30 TDS x 15 days
3.	10/08/2019	Marked improvement in itching and burning.	Rubrum 30 TDS x 15 days
4.	26/08/2019	Rashes slight decreased with improvement in itching and burning.	Rubrum 30 TDS x 15 days
5.	09/09/2019	No further improvement, complaint is stand still.	Sepia officinalis 200 OD x 1 days Rubrum 30 TDS x 15 days
6.	24/09/2019	Marked improvement in itching, burning and rashes.	Rubrum 30 TDS x 15 days

7	10/10/2019	Patient complaints overall better.	Rubrum 30 TDS x 1 Month
8.	11/11/2019	Improved	Rubrum 30 TDS x 1 Month
9.	9/12/2019	Improved	Rubrum 30 TDS x 1 Month
10.	10/01/2020	Improved	Rubrum 30 TDS x 1 Month
11.	12/02/2020	Significantly improvement.	Rubrum 30 TDS x 1 Month

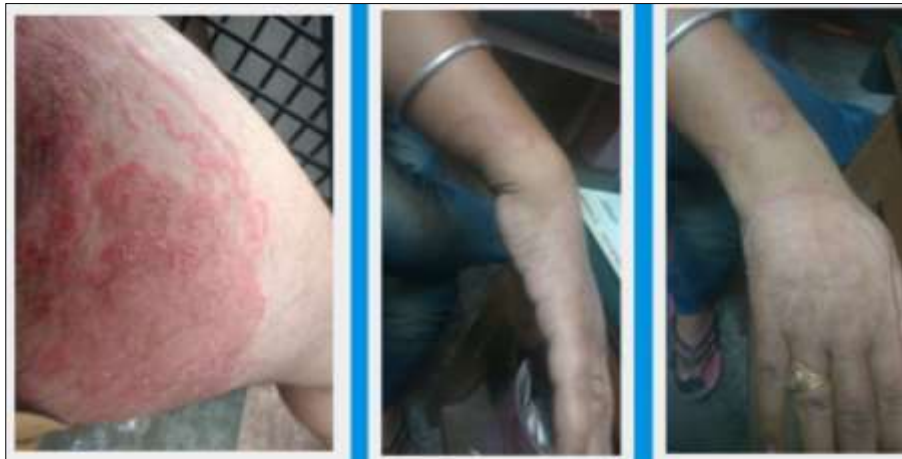

Fig 2: Before treatment

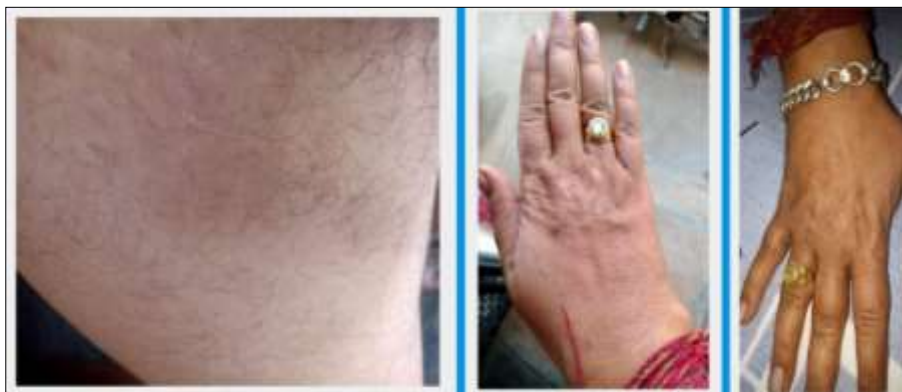

Fig 3: After treatment

Conclusion

It can have (Homoeopathy) massive and marvelous works on the quality of life (QoL) of those who are suffering from Tinea corporis, homoeopathy has proven its effectiveness in such type of cases and so this case further proves the therapeutic value and strong power of homoeopathic medicines in cases of Tinea corporis.

References

1. Yee G, Al Aboud AM. Tinea Corporis. Statpearls 2020.
2. Shukla S. Tinea Corporis Clinical Presentation. Drug & Diseases > Dermatology 2020.
3. Dr. Ramanlal Patel P. The Art of Case Taking and Practical Repertorisation in Homoeopathy, 5th Edition, Pub: Dr. J.R. Patel Hahnemann House, Kottayam Kerala 1990.
4. Dr. Samuel Hahnemann (B.K. Sarkar): Organon of Medicine, 5th & 6th Edition, 1984, 8th Indian Edition, Pub.: M. Bhattacharya & Co. (p) Ltd., Calcutta-1.
5. Michael Swash. Hutchinson's Clinical Methods, 19th Edition, P: Funded by the British Government 1990.
6. Boger CM. Boenninghausen Characteristics Materia Medica & Repertory. Reprint Edition. New Delhi: B. Jain Publishers (P) Ltd; 2003, 2004, 2006.
7. Dr. Phatak SR. MBBS: A Concise Repertory of Homoeopathic Medicines, 2nd Edition, P: B. Jain Pub, New Delhi-110 055. Adi GB. A complete review of principles and cure of homoeopathy 1992.
8. Kent JT. AM, MD: Repertory of The Homoeopathic MM, 6th American Edition, Pub: B. Jain Publishers, N.D. -110055 1990.
9. Farrington EA. MD: Comparative Materia Medica, Pub: B. Jain Publishers Pvt. Ltd., New Delhi 1986.