International Journal of Homoeopathic Sciences

E-ISSN: 2616-4493
P-ISSN: 2616-4485
www.homoeopathicjournal.com
IJHS 2021; 5(4): 55-59
Received: 28-08-2021
Accepted: 30-09-2021

Dr. Susy Charles
M.D. Hom. PhD, Associate professor, Department of Materia Medica, Dr. Padiar Memorial Homoeopathic Medical College Chottanikkara, Ernakulam, Kerala, India

Corresponding Author:
Dr. Susy Charles
M.D. Hom. PhD, Associate professor, Department of Materia Medica, Dr. Padiar Memorial Homoeopathic Medical College Chottanikkara, Ernakulam, Kerala, India

Adenomyomatosis of Gallbladder: A case study with Constitutional Homoeopathic treatment

Dr. Susy Charles

DOI: https://doi.org/10.33545/26164485.2021.v5.i4a.454

Abstract
Adenomyomatosis of Gallbladder is characterised by hypertrophy of the mucosal epithelium and the invagination of this epithelium into the interstices of a thickened muscularis, forming sinuses called Rokitansky-Aschoff sinuses. Three forms of adenomyomatosis are found in gallbladder; segmental, fundal and diffuse. Symptomatic adenomyomatosis is an indication for surgical intervention [1]. A seventeen year old girl presented with a history of recurrent attack of upper abdominal pain of two years duration.Ultrasonography of abdomen shows the features of adenomyomatosis of gallbladder. After detailed case taking, analysis, evaluation and repertorisation Pulsatilla was given. Abdominal pain was completely relieved and ultrasound scan report of abdomen after homoeopathic treatment shows normal gallbladder contour. This result shows that constitutional homoeopathic treatment is effective in the management of Adenomyomatosis of gallbladder.

Keywords: Gallbladder Adenomyomatosis, Rokitansky- Aschoff sinuses, Cholecystectomy, Pulsatilla, Constitutional homoeopathic remedy

1. Introduction
Adenomyomatosis of gallbladder is a benign condition and it is characterised by hyperplasic changes involving the gallbladder wall and overgrowth of the mucosa, thickening of the muscular wall, and formation of sinus tracts termed Rokitansky-Aschoff sinus [2, 3].

1.1. Epidemiology
Incidence of Gallbladder adenomyomatosis (GA) increases with age and usually a female predilection (M:F=1:3) [15]. Females are more predisposed to gallbladder diseases, including gallstones, adenomyomatosis and gallbladder carcinoma [4]. Aetiology of adenomyomatosis is unknown [5].

1.2. Pathology
Adenomyomatosis lesion of the Gallbladder is with no malignant potential and may involve the Gallbladder in three forms called focal (fundal), segmental and more rarely diffuse. Most common type is focal and usually involves the gallbladder fundus [2]. In fundal GA, focal thickening involving gallbladder fundus and in segmental GA, there is circumferential over growth of the gallbladder wall that leads to formation of compartments. In diffuse GA, disseminated thickening and irregularity of the mucosa and muscularis are found [6]. Rokitasky-Aschoff sinuses (RAS) are characterised by microscopic or macroscopic pseudo diverticular or pockets in the gallbladder. Histologically, they are present as out pouching of gallbladder mucosa into the gallbladder muscle layer and subserosal tissue and these results in hyperplasia and herniation of epithelial cells into the fibromuscular layer of the gall bladder wall [7].

1.3 Clinical features
The duration of symptoms of GA may vary from a few days to months. Most common presentation of GA is abdominal pain with intermittent bouts of right upper quadrant pain similar to symptomatic gallbladder disease. Nausea and vomiting, intolerance to fatty food are also reported symptoms [8]. The clinical presentation mimics, the more common conditions such as cholecystitis, choledocholelithiasis, cancer of the bile duct and pancreatic cancer.

1.4. Diagnosis
A correct diagnosis of GA is neccessary in order to avoid unnecessary cholecystectomies. Ultrasound scan is the imaging modality of choice for diagnosing adenomyomatosis [9]. Usually sonographically evident gallbladder wall thickening has its aetiology in inflammatory or neoplastic conditions, with cholecystitis. The diffuse wall thickening with intramural diverticula forming the "Rosary sign" and "Pearl necklace sign" and hourglass configuration of the gallbladder usually confirm the radiological diagnosis [10]. GA is uncommon and need to be distinguished from other similar conditions such as choledocholelithiasis, sclerosing cholangitis, carolis disease and choledochal cyst.

1.5. Treatment
Symptomatic adenomyomatosis especially abdominal pain or hepatic colic even in the absence of gallstones is an indication for cholecystectomy. Surgical intervention is the first choice of treatment for patients with GA [11, 12].

2. Methods
A case of Gallbladder Adenomyomatosis treated with homoeopathic constitutional remedy. Ultrasonograghy results showed diffuse wall thickening (8.2mm) of Gallbladder with obliteration of the lumen in some areas showing the characteristic hourglass appearance of Adenomyomatosis, which resolved after homoeopathic treatment and evaluated through abdominal USG.

2.1. Case Summary
A 17 year old girl presented with recurrent attack of upper abdominal pain of 1 year duration. Pain was aggravated by eating (++), fried food, potato, fatty food and during night (++). Pain relieved by lying on abdomen (+++) and pressure.

2.1.1. History of presenting complaint.
Complaint started 2 years back as pain in abdomen which gradually increased in intensity. Took allopathic medicines from the medical college hospital Kottayam. Ultrasonography dated 24 /5 / 2018 showed gallbladder wall grossly thickened [8.1mm] showing an hourglass appearance and diagnosed as adenomyomatosis of gall bladder. No relief from allopathic medications for 1 year. History of recurrent attack of abdominal pain and intensity of pain also increased. Ultrasound scanning on 9 /4 /2019 reveals diffused gall bladder wall thickening [8.2mm] and hourglass appearance. Features were consistent with adenomyomatosis. Patient reported to our hospital on 10 /4 /2019 with severe pain in upper abdomen immediately after eating, especially after fatty food, fried items, pulses and tubers, and pain was more during night hours.

2.1.2. Past History
History of breathing difficulty in childhood and relieved after allopathic medications.

2.1.3. Family History
Mother suffering from allergic contact dermatitis.

2.1.4. Physical Generals
Appetite was increased. Patient desires cold food, sweets, chocolates and fried food. Thirst was reduced, desires cold water. Sweat was more on face and neck. Patient desires fanning and open air and desires bathing in cold water cold climate. Thermally hot.
Menstrual history: Menarche at the age of 13. Menses regular, last for 7 days, pain in lower abdomen, and extremities during first 2 days.

2.1.5. Mental Generals:
Weeps easily, like pets

2.2. Evaluation
- Weeps easily
- Like pets
- Desire cold food
- Desires cold water
- Desire sweets
- Desire chocolates
- Desire fried food
- Desire open air
- Thermally hot
- Pain in upper abdomen
- < after eating
- < fried food
- < during night
- > lying on abdomen
- > pressure

2.3. Remedy selection
Phosphorus and Pulsatilla nigricans were the first two remedies on repertorisation. Patient was hot. So the chilly remedy was excluded. Pulsatilla was selected as the similimum on the basis of totality of symptoms (weeps easily, love for animals, desire for open air, thermally hot, desire cold food, desire cold drinks, desire sweets, desire chocolates, pain abdomen night aggravation, pain after eating aggravation). Pulsatilla 200 single dose was prescribed on 10/04/2019 and followed by placebo in the form of globules of 40 sizes, QID for one month.

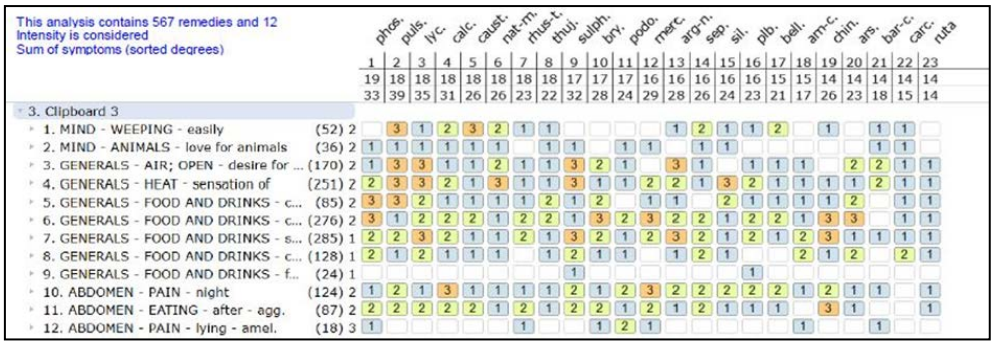

Fig 1: Repertorisation chart

Table 1: Follow-up chart

SI NO	Date	Observation	Prescription
1	11/5/2019	No history of pain for 3wks.Pain in upper abdomen++, after taking fatty food, night, < 2days.	Pulsatilla 200/1 dose
2	8/6/2019	No history of pain till 7/6/19.but history of severe pain yesterday, sleeplessness due to pain.	Pulsatilla200/1dose
3	13/7/2019	No history of pain, sleep normal, appetite normal.	Placebo
4	10/8/2019	Pain after taking milk, intensity reduced, menses delayed.	Pulsatilla200/1dose
5	14/9/2019	Frequency and intensity of pain reduced, even after fattyfood. menses appeared.	Placebo
6	12/10/2019	Regular menses, no history of pain.	Placebo
7	9/11/201	Menses delayed for 2 weeks, dysmenorrhoea	Pulsatilla 1M/1dose
8	14/12/2019	No history of pain, thirst moderate, menses normal, not painful.	placebo
9	12/1/2020	No history of pain, thirst moderate, menses normal, not painful.	Placebo
10	9/2/2020	Pain in upper abdomen after taking meat and chicken puffs.	Pulsatilla 1M/1dose
11	8/3/2020	No history of pain, menses normal.	Placebo
12	10/5/2020	No history of pain, menses normal.	Placebo
13	12/7/2020	Breathing difficulty started for 1 week	Pulsatilla 10M/1dose
14	13/9/2020	No history of dyspnoea or dysmenorrhoea or abdominal pain.	Placebo
15	8/11/2020	Menses regular, No history of dyspnoea, or dysmenorrhoea or abdominal pain.	Placebo
16	10/1/2021	Menses regular, No history of dyspnoea, dysmenorrhoea or abdominal pain.	Placebo
17	14/3/2021	No history of abdominal pain, no dyspnoea, no dysmenorrhoea.	Placebo

3. Results

There was significant improvement after the first prescription itself and pain in upper abdomen was completely relieved after ten months of treatment. No history of abdominal pain after 9/2/2020 even after taking fatty food, fried items, potato or milk. Ultrasonography report on 16/4/2021 showed normal gallbladder distension with normal contour.

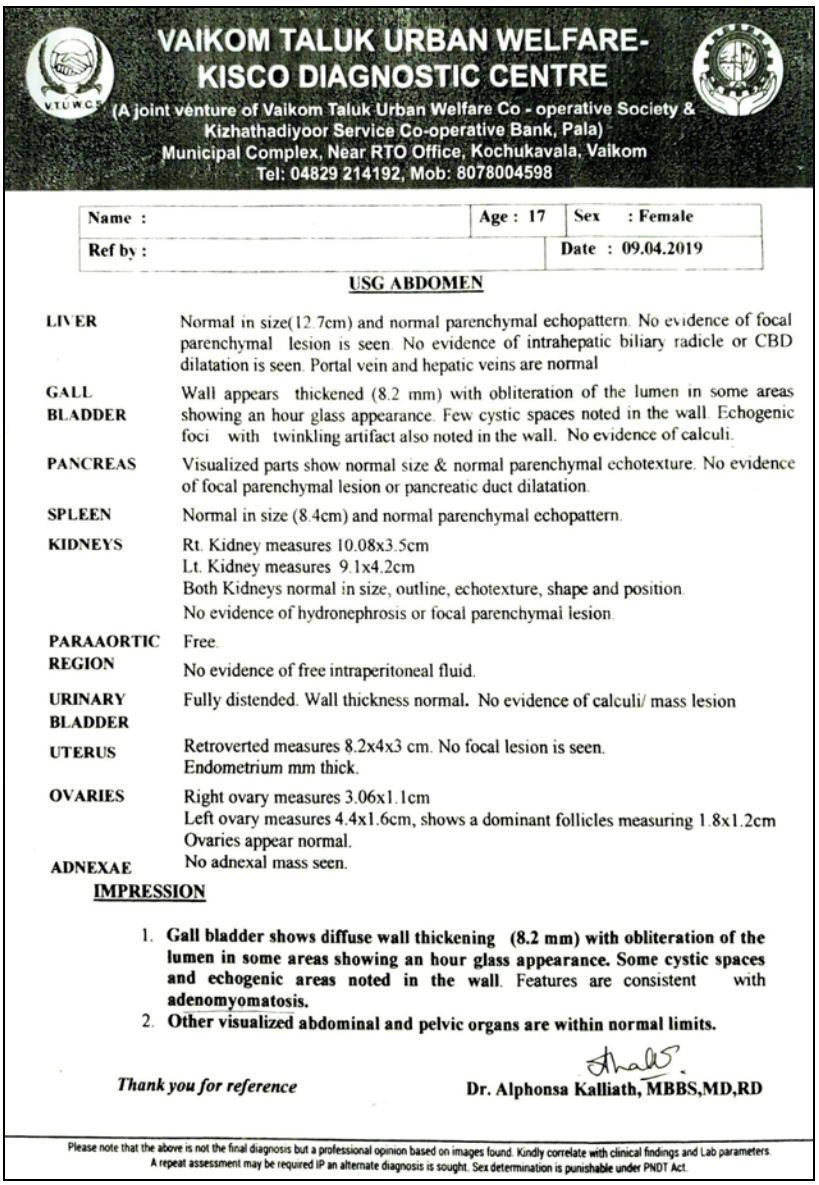

VAIKOM TALUK URBAN WELFARE-
KISCO DIAGNOSTIC CENTRE
(A joint venture of Vaikom Taluk Urban Welfare Co - operative Society & Kizhathadiyoor Service Co-operative Bank, Pala)
Municipal Complex, Near RTO Office, Kochukavala, Vaikom
Tel: 04829 214192, Mob: 8078004598

Name :	Age : 17	Sex : Female
Ref by :		Date : 09.04.2019

USG ABDOMEN

LIVER	Normal in size(12.7cm) and normal parenchymal echopattern. No evidence of focal parenchymal lesion is seen. No evidence of intrahepatic biliary radicle or CBD dilatation is seen. Portal vein and hepatic veins are normal
GALL BLADDER	Wall appears thickened (8.2 mm) with obliteration of the lumen in some areas showing an hour glass appearance. Few cystic spaces noted in the wall. Echogenic foci with twinkling artifact also noted in the wall. No evidence of calculi.
PANCREAS	Visualized parts show normal size & normal parenchymal echotexture. No evidence of focal parenchymal lesion or pancreatic duct dilatation.
SPLEEN	Normal in size (8.4cm) and normal parenchymal echopattern.
KIDNEYS	Rt. Kidney measures 10.08x3.5cm Lt. Kidney measures 9.1x4.2cm Both Kidneys normal in size, outline, echotexture, shape and position. No evidence of hydronephrosis or focal parenchymal lesion.
PARAAORTIC REGION	Free. No evidence of free intraperitoneal fluid.
URINARY BLADDER	Fully distended. Wall thickness normal. No evidence of calculi/ mass lesion
UTERUS	Retroverted measures 8.2x4x3 cm. No focal lesion is seen. Endometrium mm thick.
OVARIES	Right ovary measures 3.06x1.1cm Left ovary measures 4.4x1.6cm, shows a dominant follicles measuring 1.8x1.2cm Ovaries appear normal.
ADNEXAE	No adnexal mass seen.

IMPRESSION

1. **Gall bladder shows diffuse wall thickening (8.2 mm) with obliteration of the lumen in some areas showing an hour glass appearance. Some cystic spaces and echogenic areas noted in the wall.** Features are consistent with **adenomyomatosis.**
2. **Other visualized abdominal and pelvic organs are within normal limits.**

Thank you for reference

Dr. Alphonsa Kalliath, MBBS,MD,RD

Please note that the above is not the final diagnosis but a professional opinion based on images found. Kindly correlate with clinical findings and Lab parameters. A repeat assessment may be required IP an alternate diagnosis is sought. Sex determination is punishable under PNDT Act.

Fig 2: Ultrasound Report (2019) before starting Homoeopathic treatment

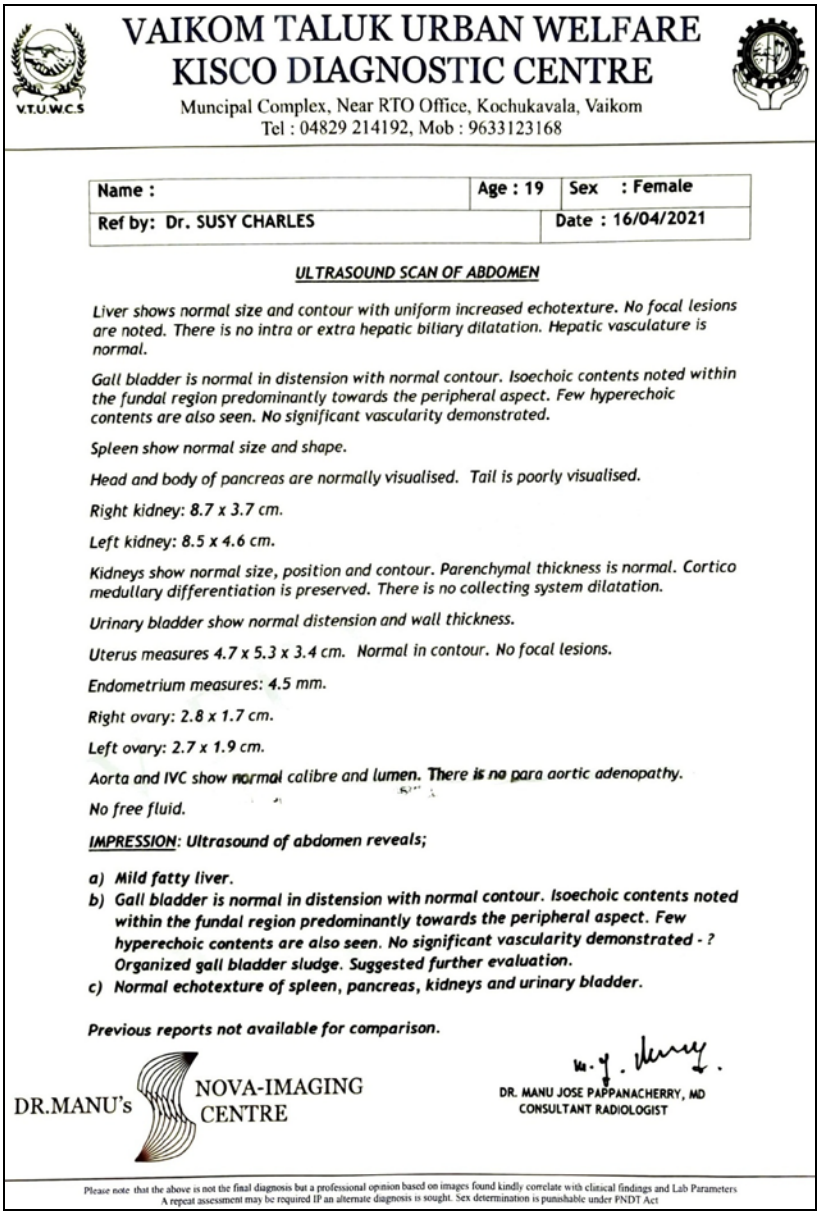

VAIKOM TALUK URBAN WELFARE
KISCO DIAGNOSTIC CENTRE
V.T.U.W.C.S
Muncipal Complex, Near RTO Office, Kochukavala, Vaikom
Tel : 04829 214192, Mob : 9633123168

Name :	Age : 19	Sex : Female
Ref by: Dr. SUSY CHARLES		Date : 16/04/2021

ULTRASOUND SCAN OF ABDOMEN

Liver shows normal size and contour with uniform increased echotexture. No focal lesions are noted. There is no intra or extra hepatic biliary dilatation. Hepatic vasculature is normal.

Gall bladder is normal in distension with normal contour. Isoechoic contents noted within the fundal region predominantly towards the peripheral aspect. Few hyperechoic contents are also seen. No significant vascularity demonstrated.

Spleen show normal size and shape.

Head and body of pancreas are normally visualised. Tail is poorly visualised.

Right kidney: 8.7 x 3.7 cm.

Left kidney: 8.5 x 4.6 cm.

Kidneys show normal size, position and contour. Parenchymal thickness is normal. Cortico medullary differentiation is preserved. There is no collecting system dilatation.

Urinary bladder show normal distension and wall thickness.

Uterus measures 4.7 x 5.3 x 3.4 cm. Normal in contour. No focal lesions.

Endometrium measures: 4.5 mm.

Right ovary: 2.8 x 1.7 cm.

Left ovary: 2.7 x 1.9 cm.

Aorta and IVC show normal calibre and lumen. There is no para aortic adenopathy.

No free fluid.

IMPRESSION: Ultrasound of abdomen reveals;

a) Mild fatty liver.
b) Gall bladder is normal in distension with normal contour. Isoechoic contents noted within the fundal region predominantly towards the peripheral aspect. Few hyperechoic contents are also seen. No significant vascularity demonstrated - ? Organized gall bladder sludge. Suggested further evaluation.
c) Normal echotexture of spleen, pancreas, kidneys and urinary bladder.

Previous reports not available for comparison.

DR.MANU's NOVA-IMAGING CENTRE

DR. MANU JOSE PAPPANACHERRY, MD
CONSULTANT RADIOLOGIST

Please note that the above is not the final diagnosis but a professional opinion based on images found kindly correlate with clinical findings and Lab Parameters
A repeat assessment may be required IF an alternate diagnosis is sought. Sex determination is punishable under PNDT Act

Fig 4: Ultrasound Report (2021) after Homoeopathic treatment

4. Discussion

Gallbladder adenomyomatosis (GA) is increasingly experienced in clinical practice due to increasing use of ultrasound imaging. Clinicians must know what are the consequences of this condition and its proper management [6]. The gallbladder wall is less than 2mm thick in healthy subjects [13]. Mucosa, lamina propria, muscularis propria, and serosa are the four layers of gallbladder wall. Thickening of the wall in GA involves of both mucosa and muscularis propria [14]. GA is a degenerative as well as proliferative disease characterised by excessive epithelial proliferation and hypertrophy of muscularis propria.GA was first reported as precancerous condition by Albridge *et al.* and Nishimura *et al.* [18]. DNA in the mucosa of GA is similar to that of normal mucosa and GA contains no oncogene [4].

Here, the case was diffuse type GA, rare form than fundal and segmental. Gallbladder showed diffuse wall thickening (8.2mm) with obliteration of the lumen showing "hourglass appearance". After constitutional treatment with Pulsatilla 200 first followed by high potencies, gallbladder became in normal distension with normal contour. The constitutional medicine Pulsatilla not only relieved the abdominal pain but also bronchial asthma (childhood complaint) and dysmenorrhoea.

According to Dr. Hahnemann the homoeopathic physician should always be guided by the totality of symptoms in each case. He should never fall into the habit of making favourite medicines for nosologically labelled disease condition. A remedy is homoeopathic not by its peculiar method of preparation but by the mode of its application according to the principle of symptom similarity between the drug disease and the natural disease [20, 21].

5. Conclusion

Here a case of gallbladder adenomyomatosis was treated with the homeopathic remedy Pulsatilla. Pulsatilla was selected as the constitutional medicine on the basis of totality of symptoms after repertorisation. Recurrent attack of abdominal pain was relieved completely and ultrasound scan after treatment showed normal gallbladder contour. The successful management of the case proves the effectiveness of homoeopathic constitutional treatment in gallbladder adenomyomatosis.

6. References

1. Golse N, *et al*. Gallbladder adenomyomatosis: Diagnosis and management. J Visc Surg 2017;154(5):345-353. https://doi.org/10.1016/j.jvscurg.2017.06.004.
2. Norman Williams S, Christopher JK, Bulstrode P, Ronan O' Connell. Bailey and Love's Short Practice to Surgery.25th edition, Hodder Arrnold 2008, 1128.
3. Vikram Dogra S. Adenomyomatosis Imaging. emedicine.medscape.com 2018.
4. Pang L, Zhang Y, Wang Y, Kong J. Pathogenesis of Gallbladder adenomyomatosis: and its relationship with early-stage gallbladder carcinoma an overview. Braz J Med Biol Res 2018;51;(6):e7411.
5. Ram MD, Midha D. Adenomyomatosis of the Gallbladder. Surgery 1975;78(2):224-229.
6. Kit- Fai Lee, Esther HY Hung, Howard HW Leung, Paul BS Lai. A narrative review of gallbladder adenomyomatosis is what we need to know. *Home/* Archives/ Annals of Translational Medicine 2020;8:23. https: //doi.org/ 10.21037/ATM-20-4897.
7. Cariati A, Celta F. Rokitansky- Aschoff sinuses of the gallbladder are associated with black pigment gallstone a scanning electron microscopy study. Ultrastructural Pathology 2002;27;(4):265-270. http://doi.org/10.1080/01913120309913.
8. Teelucksingh S, Welch T, Chan A, *et al*. Gallbladder Adenomyomatosis presenting with Abdominal Pain. Cureus 2020;12;(9):e10485. Doi:10.7759/cureus.10485.
9. Bonatti M, *et al*. Gallbladder adenomyomatosis imaging findings, tricks and pitfalls, *Insight Imaging* April 2017;8(2):243-253. http://doi.org/10.1007/s13244-017-0544-7.
10. Kim BS, Oh JY, Nam KJ, *et al*. Focal thickening at the fundus of the gallbladder: computed tomography differentiation of fundal type adenomymatosis and localized chronic cholecystitis. Gut liver 2014;(8):219-223. http;//doi.org/10.5009/gnl.2014.8.2.219.
11. Haaradome H, *et al*. The pearl necklace sign: an imaging sign of adenomyomatosis of the gallbladder at MR cholangiopancreatography. Radiology 2003;227:80-88. http://doi.org/10.1148/radio.2271011378.
12. Lin SH, Chang FY, Yang YS, Jin JS, Chen TW. Rare gallbladder adenomyomatosis presenting as a atypical cholecystitis: case report BMC Gasteronterolology. 2011;11:106
13. Mahajan A, Sripathi S. Gallbladder Adenomyomatosis Mimicking Carcinoma: A Diagnostic Dilemma. J Glob Oncol 2;(5):341-5.
14. Alexis Boscak R, Mahmoud Al-Hawary, Stephen Ramsburgh R. Adenomyomatosis of the Gallbladder. Radiographics. pubs.rsna.org 2006;26:3.
15. Ryu Y, Bell D. Adenomyomatosis of the Gallbladder Radiology Reference Article radiopedia.org 2021.
16. Kai K, Ide T, Masuda M, Kitahara K, Miyoshi A, Miyazaki K, *et al.* Clinicopatological features of advanced gallbladder cancer assosciated with adenomyomatosis. Virchows Arch 2011;459(6):573-80.
17. Hammad AY, Miura JT, Turaga KK, Johnston FM, Hohenwalter MD, Gamblin TC. A literature review of radiological findings to guide the diagnosis of gallbladder adenomyomatosis. HPB (Oxford) 2016;18(2):129-35.
18. Nishimura A, Shirai Y, Hatayekama K. Segmental adenomyomatosis of the gallbladder predisposes to cholecytolithiasissis. J Hepatobiliary Pancreat Surg 2004;11(5):342-7.
19. Schroyens F. Synthesis Treasure Edition. Radar Opus 2009.
20. Hughes R. The Principle and Practice of Homeopathy. B. Jain Publishers Private Ltd New Delhi, India 1991.
21. Hahnemann S. Organon of Medicine 5th and 6th edition. B. Jain Publishers Private Ltd. New Delhi, India 1995.