



International Journal of Homoeopathic Sciences

E-ISSN: 2616-4493

P-ISSN: 2616-4485

www.homoeopathicjournal.com

IJHS 2021; 5(4): 398-402

Received: 28-05-2021

Accepted: 05-08-2021

Monika Srivastava

Homoeopathic Medical Officer,
State Homoeopathic
Dispensary, Bhujauli Bazaar,
Kushinagar, Uttar Pradesh,
India

Chaturbhujaya Nayak

Formerly: Director General,
Central Council for Research in
Homoeopathy, Govt. of India
and President of
Homoeopathy University,
Jaipur, Rajasthan, India

Corresponding Author:

Monika Srivastava

Homoeopathic Medical Officer,
State Homoeopathic
Dispensary, Bhujauli Bazaar,
Kushinagar, Uttar Pradesh,
India

A case report of uterine fibroid treated with constitutional homoeopathic medicine

Monika Srivastava and Chaturbhujaya Nayak

DOI: <https://doi.org/10.33545/26164485.2021.v5.i4f.503>

Abstract

Uterine fibroids, also known as uterine leiomyomas, uterine myomas, myomas, fibromyomas or fibroleiomyomas, are the most common form of benign uterine tumors affecting women. A patient reported with symptoms of profuse menses with pain in lower abdomen radiating downwards for the last two years. The ultrasonography of abdomen revealed a posterior wall uterine myoma of size 1.2cm x 1.2cm. After case taking and repertorization *Sepia 30* was prescribed initially and later *Sepia 200* was prescribed. Overall improvement was noticed clinically and complete resolution of uterine myoma was seen in ultrasonography report after eight weeks of homoeopathic treatment. This case is presented here to show the effectiveness of homoeopathic medicine selected on constitutional basis in the treatment of uterine fibroid.

Keywords: Constitutional medicine, homoeopathy, *Sepia*, uterine fibroid

Introduction

Uterine fibroids are monoclonal tumors of uterine smooth muscle, originating from the myometrium. They are composed of large amount of extracellular matrix (ECM) containing collagen, fibronectin and proteoglycans [1]. The distribution of uterine fibroid is broadly as: intramural or interstitial (75%), submucous (15%) and subserous (10%) [2]. Although the presence of fibroid is almost never associated with mortality, it may cause morbidity and affect quality of life of the patients. They most often occur in women between 30-50 years of age [3]. Uterine fibroids are one of the most common indications for hysterectomy further leading to complications [4]. Uterine fibroids are a major cause of morbidity in women of reproductive age and sometimes even after menopause. Although the exact cause of uterine fibroid is still unclear, risk factors for developing uterine fibroids such as: age, early menarche, reduced fertility, frequent alcohol, caffeine consumption, family history [i.e. hereditary], obesity, consumption of red meat, hypertension, diabetes mellitus and previous pelvic inflammatory disease (P.I.D.) have been observed [5]. The rate of patients suffering from uterine fibroids or myomas has been increasing worldwide.

Available treatments for uterine fibroids include medical therapies, surgery and newer options such as uterine artery embolization (UAE). Presently people with uterine fibroids undergo total abdominal, vaginal or laparoscopic assisted hysterectomies around the world. In less developed and more populous countries like India, the numbers may be even higher [6].

This case demonstrates effectiveness of homoeopathic medicine selected on the basis of constitution of the patient in treating uterine fibroid.

Case history

A 34-year old married female, Mrs. S came on August 6, 2020 for treatment of profuse menses with pain in lower abdomen radiating downwards to groins, for last two years. She had weakness and disinclination to work. She felt exhausted on doing daily chores.

Past history: Typhoid fever in 2018.

Family history: Mother: Hypertension.

Father: Hypertension and diabetes.

Physical generals: Appetite: Normal.

Craving: Salty and sour things.

Aversion: Nothing specific.

Thirst: Normal.

Perspiration: Not much.
 Thermal: Chilly.
 Stool: Unsatisfactory.
 Urine: NAD.

Menstrual history: Menarche attained at 12 years of age. Menses regular (30 ± 2 days cycle), profuse, lasts 6 to 8 days. LMP: 01-08-2020.

Obstetric history: G₃P₂A₁L₂D₀

Patient had one abortion at one and a half months of her first pregnancy. Later, two full term normal deliveries.
 Sleep: Sound but non-refreshing, felt tired in morning and did not want to leave bed.
 Dreams: Nothing specific.

Mental symptoms: She was irritable at trifles and had a constant feeling of being sick. She would take rest for a few minutes after a little work to feel fresh. She told that she had been suffering for many years, (this was a subjective feeling of patient, she later explained that “suffering” was to do the daily chores as she mostly didn’t want to). The look on her face was of being miserable and helpless. Her eyes watered as she tried to narrate her complaints.

Physical make-up of the patient: Patient was of average height (5’1”), average built (weight 54 kg), dark complexioned.

Investigation before treatment

Ultrasonography of whole abdomen (August 6, 2020) Posterior wall uterine myoma of size 1.2cm x 1.2cm [Fig. 1(a) and 2(a)].

A detailed case taking was done to construct the totality of symptoms as per principles of Homoeopathy. After analysis of symptoms, the following characteristic symptoms were considered for repertorization.

Totality of symptoms

1. Feeling of helplessness;
2. Wearisome;
3. Weeping tendency, when telling her symptoms;
4. Delusion of being sick;
5. Feeling unfortunate;
6. Aversion to business (indolence);

7. Desire to remain in bed in morning.

Remedy selection (Repertorial method)

a) Selection of repertory: Complete Repertory was used for repertorization by Hompath Classic M.D. Software, Ver. 1.0.

b) Repertorial totality

1. Mind-Helplessness, feeling of.
2. Mind-Wearisome.
3. Mind-Weeping, tearful mood: telling of her illness, when
4. Mind-Delusions, imaginations: Sick: He is.
5. Mind-Unfortunate, feels.
6. Mind-Business: Averse to.
7. Mind-Bed: Desire to remain in: Morning.

c) Repertorization

Repertorization sheet is enclosed (Fig.3).

d) Repertorial analysis (Table 1)

Table 1: Repertorial analysis

Medicine	Marks secured	No. of rubrics covered
<i>Sepia</i>	13	7
<i>Pulsatilla</i>	10	5
<i>Lycopodium</i>	9	5
<i>Kali carb</i>	7	5
<i>Natrum mur</i>	7	4

After repertorization, the above medicines were identified for differentiation.

On repertorial analysis, it was found that *Sepia* covered all rubrics followed by *Pulsatilla*, *Lycopodium*, *Kali carb*. And *Natrum mur*.

Justification for prescription

On the basis of repertorial analysis and in consultation with Materia Medica, *Sepia* was selected as the constitutional similitum. Considering miasm, *Sepia* is predominantly an anti-sycotic medicine and patient’s disease is covered by sycotic miasm.

First prescription (August 6, 2020)

Sepia 30, single dose and *Placebo* once daily was given for 15 days.

Table 2: Follow-Up

Date	Complaints	Prescription
August 20, 2020	Pain in lower abdomen was slightly better. Feeling of freshness in morning initially for 2-3 days.	<i>Sepia</i> 200 x three doses in water at 15 minutes interval. <i>Placebo</i> once daily for one month.
September 19, 2020	Marked improvement in her mood and energy level. LMP: 30-08-2020. Menstrual bleeding was less than before. Pain in abdomen: mild.	<i>Placebo</i> once daily for 15 days.
October 2, 2020	Patient was asymptomatic.	<i>Placebo</i> once daily was given for one month

Follow-up investigation

Ultrasonography of whole abdomen (October 2, 2020) showed complete resolution of posterior wall uterine myoma [Fig. 1(b) and 2(b)].

Discussion

In this case, the patient’s general look was miserable. She was sad and lachrymose. Dr. J. H. Clarke^[7] has written that the *Sepia* patient weeps when asked about her symptoms

and there is great sadness with uterine troubles. The homoeopathic medicine *Sepia* was prescribed on the basis of individualization. The literature review in Homoeopathy reveals studies^[8-11] and case reports^[12-14] in which cases of uterine fibroids have been treated successfully with homoeopathic medicines. In a published clinical trial^[8], the medicines *Pulsatilla*, *Sulphur*, *Lycopodium*, *Phosphorus*, *Calcarea carbonica*, *Natrum muriaticum* including *Sepia* were frequently prescribed and the patients were cured. In a

prospective observational study [10], although *Sepia* was not prescribed, the patients were cured with medicines *Calcarea carbonica*, *Pulsatilla*, *Phosphorus*, *Lycopodium*, *Sulphur* and *Kali carbonica*. In a published case report [14], treatment was started with constitutional homoeopathic medicine *Sepia* with increasing potencies followed by *Natrum muriaticum* with successful result.

In Homoeopathy, prescription of medicine is based on individualizing the patient and symptom totality [15-17]. A constitutional remedy thus selected causes reversal of pathological changes (uterine fibroid) and leads to restoration of health of the patient.

Conclusion

The case reported here shows the effectiveness of constitutional homoeopathic medicine in the treatment of uterine fibroid. This case gives a message to the medical

fraternity that Homoeopathy is a reliable option in treating such cases and must be opted for before other procedures like surgery/hysterectomy. However, controlled trials are needed to further establish the efficacy of homoeopathic medicines in treating cases of uterine fibroid.

Declaration of patient consent

The authors certify that they have obtained patient consent. The patient has given her consent for the pathological reports and clinical information to be reported in the journal. The patient understands that name will not be published and due efforts will be made to conceal identity.

Financial support and sponsorship

Nil.

Conflicts of interest: None declared.

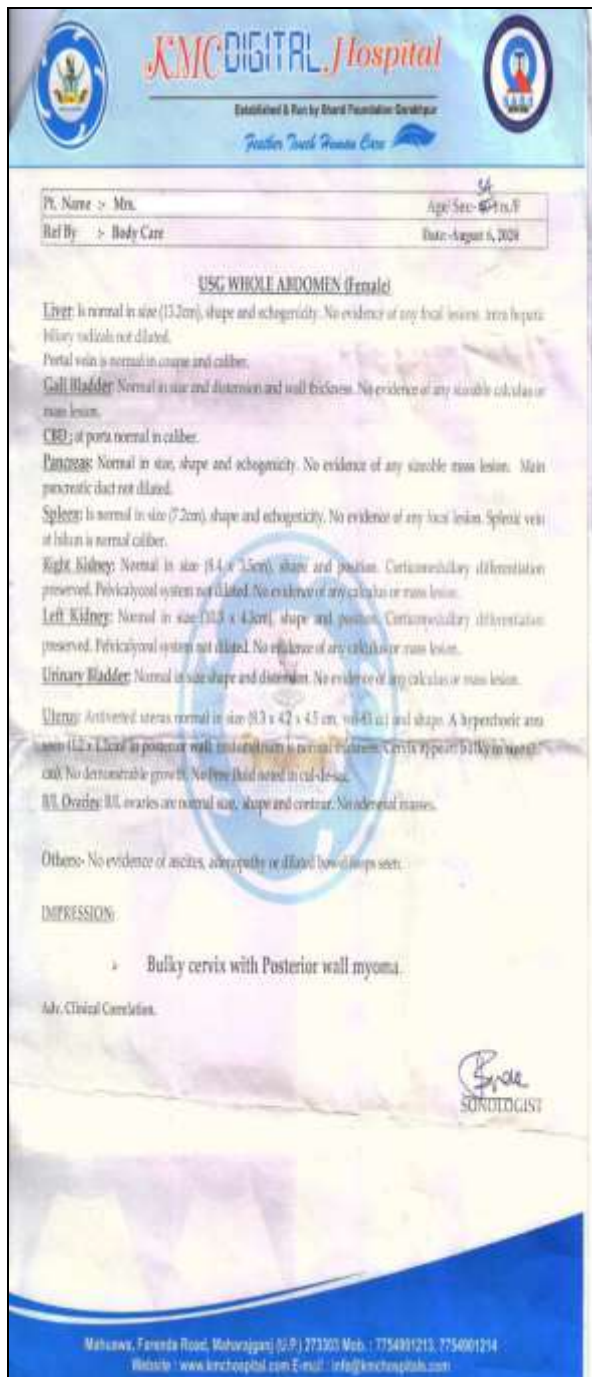

Fig 1(a): Before treatment (August 6, 2020)

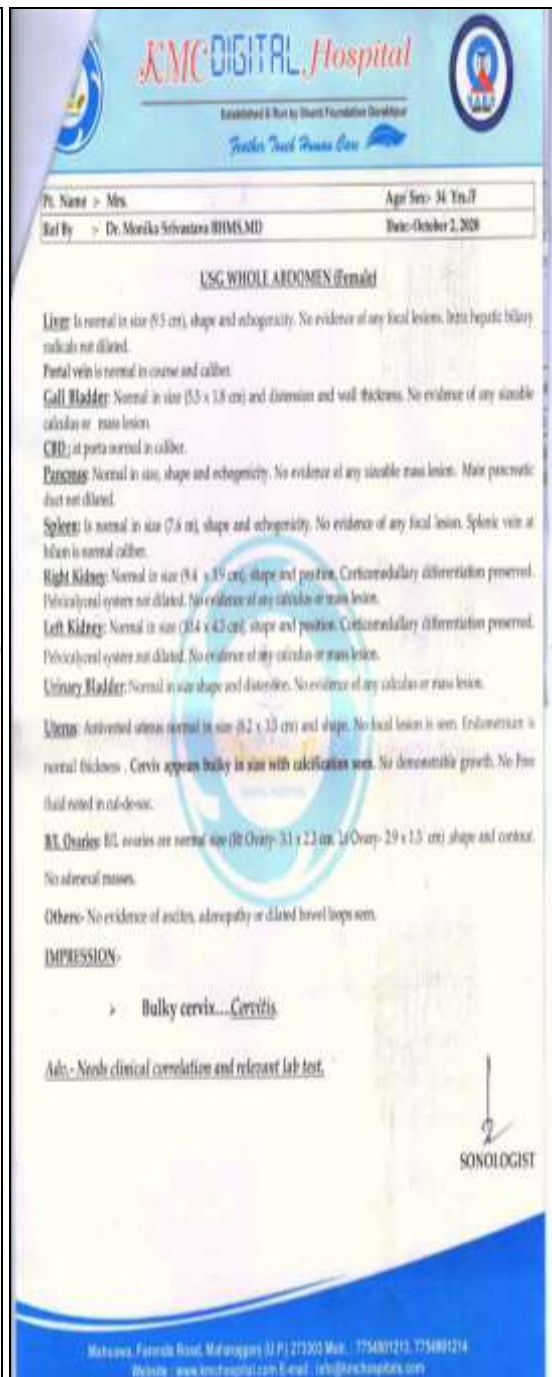


Fig 1(b): After Treatment (October 2, 2020)

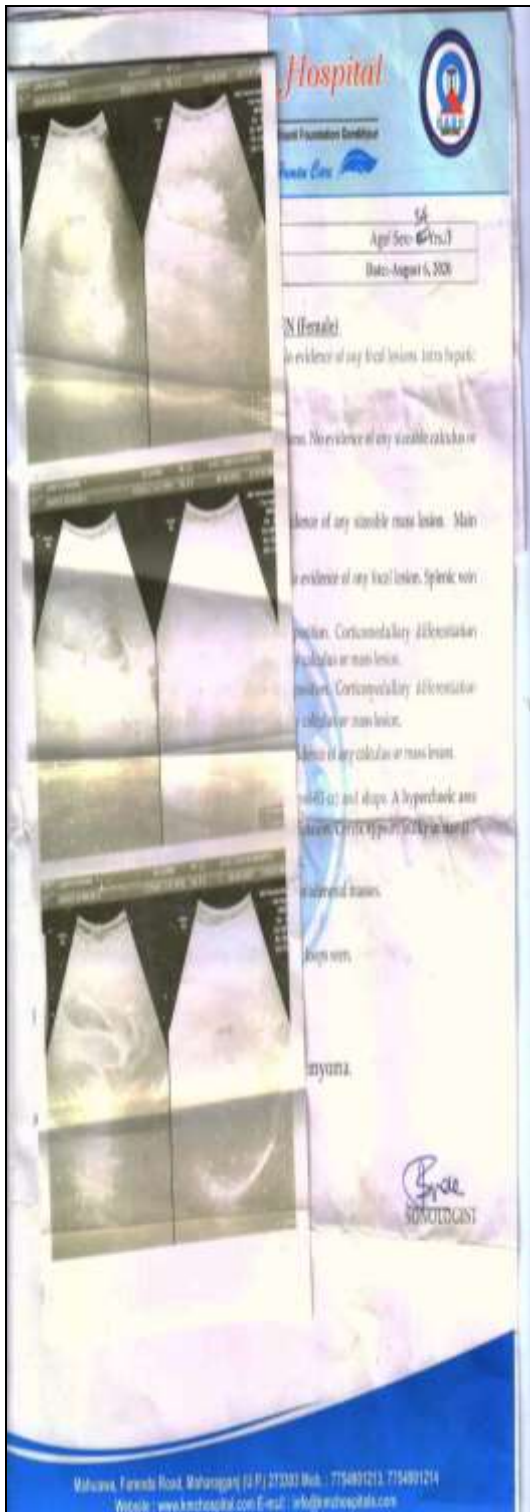


Fig 2(a): Before Treatment (August 6, 2020)

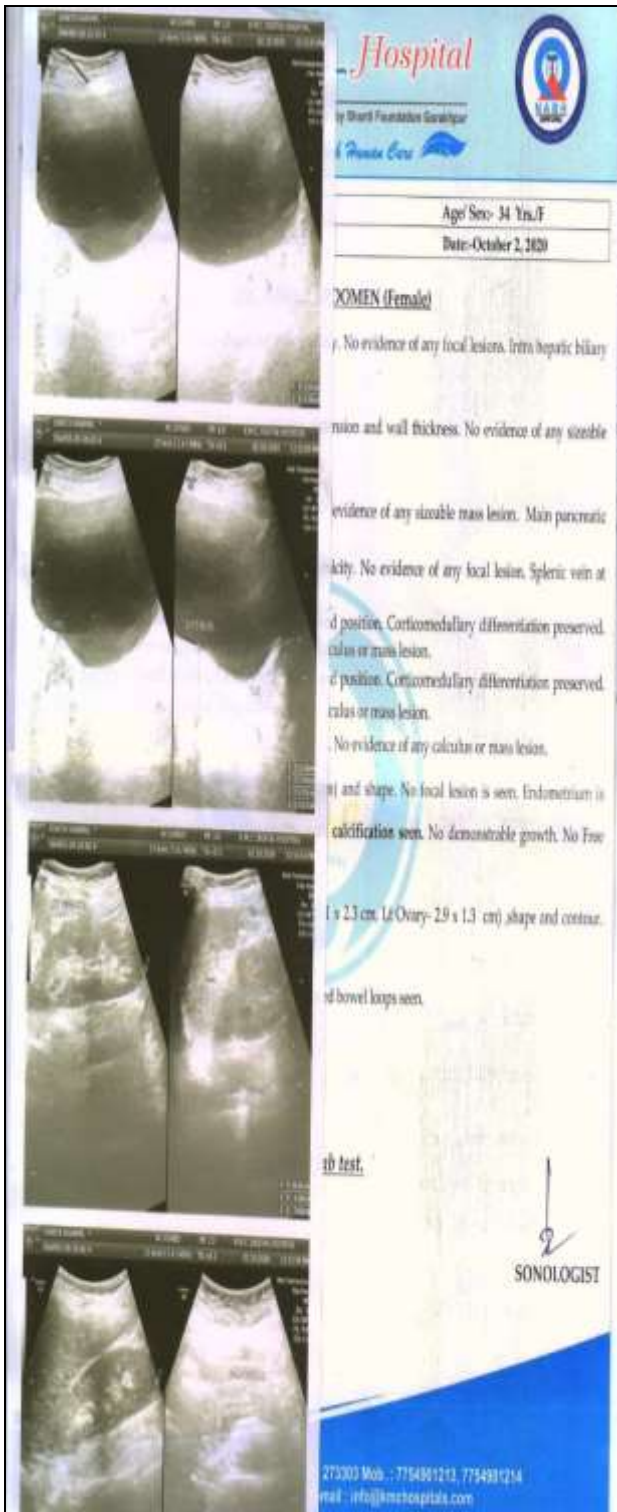


Fig 2(b): After Treatment (Oct.2, 2020)

