



International Journal of Homoeopathic Sciences

E-ISSN: 2616-4493
P-ISSN: 2616-4485
www.homoeopathicjournal.com
IJHS 2021; 5(4): 403-406
Received: 09-06-2021
Accepted: 15-07-2021

Dr. Binuraj SR
Assistant Professor,
Department of Practice of
Medicine, National
Homoeopathic Research
Institute in Mental Health
(NHRIMH), Kottayam,
Kerala, India

Dr. Ayisha EK
PG Scholar, Department of
Psychiatry, National
Homoeopathic Research
Institute in Mental Health
(NHRIMH), Kottayam,
Kerala, India

Dr. Balakrishna Shenoy M
PG Scholar, Department of
Practice of Medicine, National
Homoeopathic Research
Institute in Mental Health
(NHRIMH), Kottayam,
Kerala, India

Dr. Aswathy BA
PG Scholar, Department of
Psychiatry, National
Homoeopathic Research
Institute in Mental Health
(NHRIMH), Kottayam,
Kerala, India

Corresponding Author:
Dr. Binuraj SR
Assistant Professor,
Department of Practice of
Medicine, National
Homoeopathic Research
Institute in Mental Health
(NHRIMH), Kottayam,
Kerala, India

Efficacy of graphites 6c in treating chronic eczema: A case study

Dr. Binuraj SR, Dr. Ayisha EK, Dr. Balakrishna Shenoy M and Dr. Aswathy BA

DOI: <https://doi.org/10.33545/26164485.2021.v5.i4f.504>

Abstract

Eczema is a superficial inflammation of the skin characterized by redness, itching, oedema, oozing, crusting, scaling, vesicles and occasional lichenification^[1, 2]. Pathogenesis include hereditary and environmental factors and is mostly seen in children. Conventional treatment include skin hydration followed by topical steroids for flare-ups. In this case report, patient was treated successfully with Graphites 6c without using any topicals or adverse events through individualization.

Keywords: Eczema, atopic dermatitis, homoeopathy, graphites

Introduction

Eczema is a superficial inflammation of the skin characterized by redness, itching, edema, oozing, crusting, scaling, vesicles and occasional lichenification^[1, 2]. Eczema is synonymously used with dermatitis, but it is often used to refer to atopic dermatitis^[2].

Pathogenesis includes hereditary and environmental factors. Eczema is mostly seen in children but can be seen in adults also. Principal symptoms are dry, itchy skin eruptions which is prone to infection. The conventional treatment of eczema is skin hydration followed by topical steroids for flare-ups. The lifetime prevalence of Eczema is about 15-30% in children and 2-10% in adults^[3]. Filaggrin mutation in an individual will have a improper skin barrier due to the haphazard organization of the skin cells^[4]. In the initial phase eruptions are characterized by intensely pruritic, erythematous papules. Histopathology reveals mild epidermal hyperplasia, infiltrations of lymphocytes and macrophages along the venous plexus in the dermis and intercellular oedema of the epidermis (spongiosis). As the patient itches continuously and followed by rubbing, leads to thickening of skin. On physical examination, lichenification can be noted^[5].

The distribution of eruptions in Eczema can differ depending on the age of the person. Infants and children tend to have widely distributed, dry, scaly and erythematous patches with small excoriations and involvement mostly on their face, especially the cheeks. As the age progresses, the rash becomes more localized. The differential diagnosis of the eczema are Cutaneous fungal infection, Scabies, Psoriasis, Drug eruptions etc.^[6]

Here, we present a case of eczema that was treated with the homoeopathic medicine Graphites and was selected therapeutically.

Case report

42 year old male patient reported in general OPD of NHRIMH, Kottayam on 13/04/2021 presented as eruptions with edema and excoriation of the skin of foot and lower third of right leg since 6 weeks. Itching is there with burning pain after scratching with sticky discharge. Patient had similar eruptions 6 years back, then he took homeopathic treatment and complaint relieved. He was working in a laboratory (petroleum related) in the past 2 years. 6 weeks before complaint reappeared as small itching eruption on right foot with slight edema of the part. He took homeopathic medicines for that, but complaint aggravated. He suffered from Chicken Pox at 21years, relieved with Allopathic treatment and Hepatitis A at 11 Years, relieved with Allopathic treatment. His Grandfather had a history of eczema and no any other history of relevant major illnesses.

Generals (mental and physical)

His Appetite and thirst was good and had a craving for sweet. Thermal reaction was hot. Mental generals were Slowness, Aversion to company and Laziness.

The patient was instructed not to use any other treatment for the same condition and to moisturize with coconut oil in case of dryness.

On examination

Edema of right foot and lower third of right leg. Skin eroded

with crusting and fissuring. grayish purplish in colour with seropustular discharge. Warm and tender on touch The vital signs were normal.

Prescription

Considering the presenting totality Repertorisation is done in RADAR Opus Graphites 6c was selected for 1st prescription. Initially 3 doses was given along with placebo. Patient was instructed to take each dose on every 5 days for a month. Repertorial analysis chart is attached.

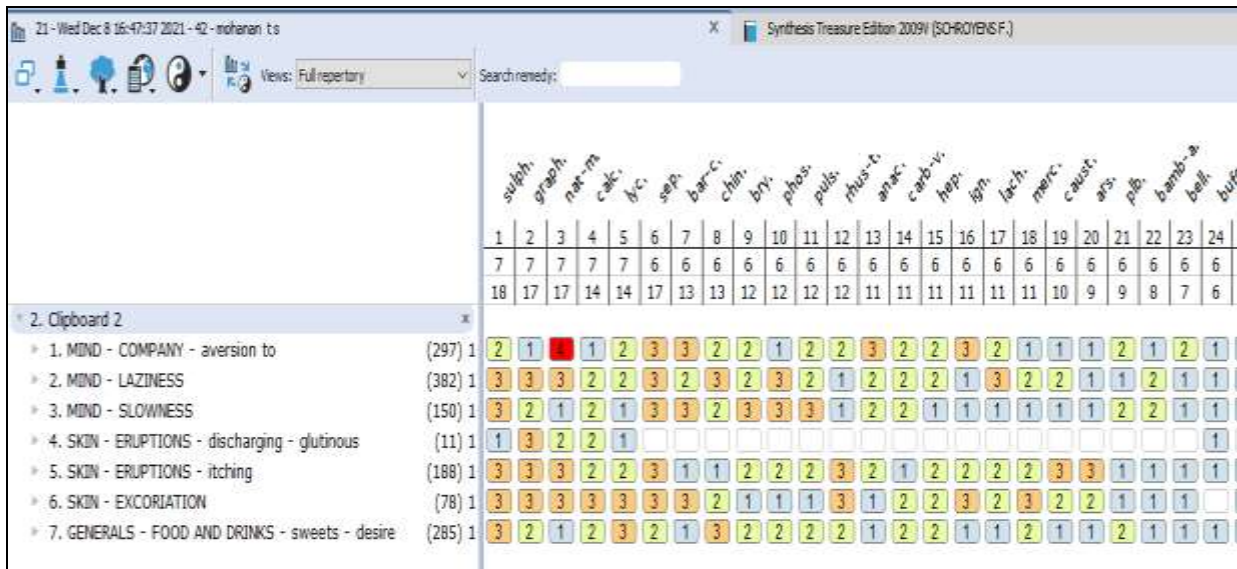


Chart 1: Repertorial analysis

Table 1: Follow up

Date & Visit	Observation	Prescription
24/4/2021 Figure 1	Itching and burning pain reduced Discharge reduced Edema reduced Pain due to dryness Thirst increased Other generals-good	1) Graphites 6C/3 dose (once in 5 days) 2) Placebo, 2 weeks
10/5/2021	Edema reduced No discharge Itching more on right leg Burning reduced Generals-good	1) Graphites 6C/6 doses (once in 5 days) 2) Placebo, 1 month
15/6/2021	Burning and itching reduced No discharge Oedema-reduced Numbness of right hand fingers since 1 week Generals-good	1) Graphites 6C/6 doses (once in 5 days) 2) Placebo, 1 month
17/7/2021 Figure 2	No eruptions, only blackish discoloration Only mild itching Generals-good	1) Graphites 6C/4 dose weekly once 2) Placebo, 1 month
17/8/2021	No eruptions Reduction in blackish discoloration Itching is absent Generals-good	1) Graphites 6C/4 dose weekly once 2) Placebo, 1 month
14/9/2021	No eruptions Blackish discoloration reduced No itching Generals-good	1) Graphites 6C/4 dose weekly once 2) Placebo, 1 month
18/10/2021 Figure 3	No eczema No itching Blackish discoloration Generals-good	1) Graphites 6C /4 dose weekly once 2) Placebo, 1 month

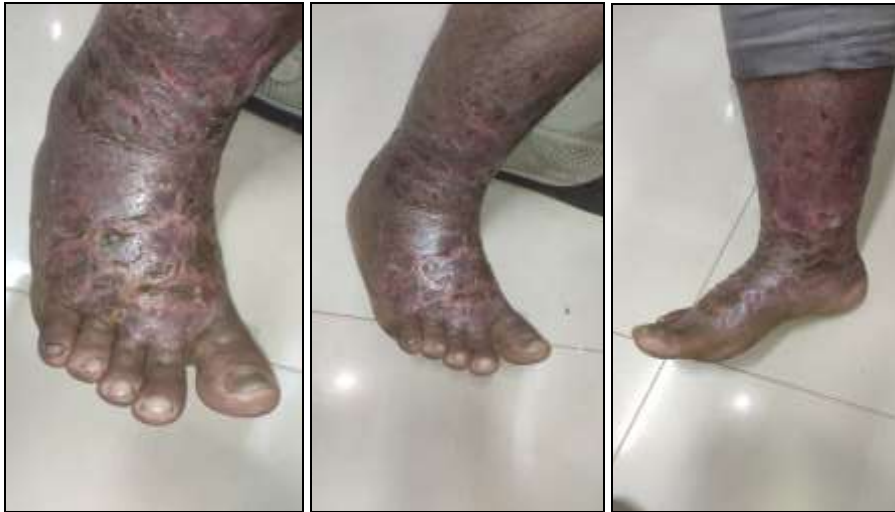

Fig 1: Initial Presentation

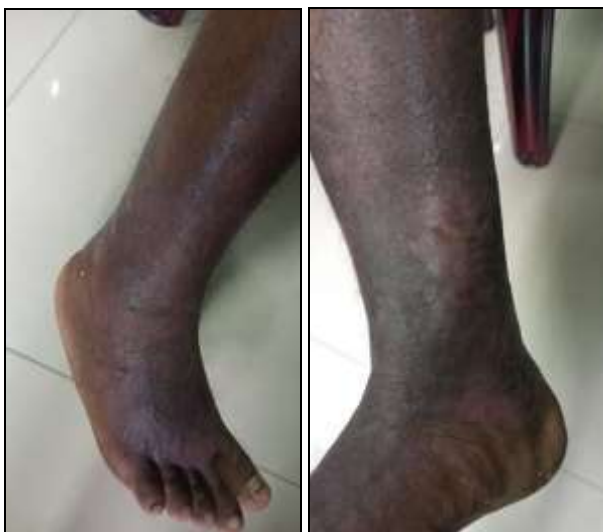

Fig 2: During treatment

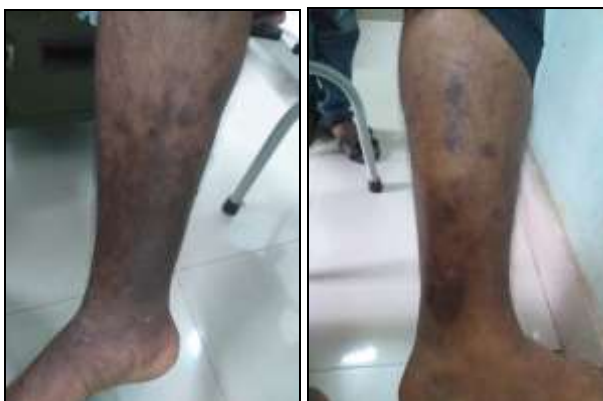

Fig 3: (On 4TH Visit)

Discussion and conclusion

This case report shows the effectiveness of homoeopathic medicines in the case of eczema. No local application was used. On the basis of the patients presenting symptoms and generals, Repertorisation is done, and then Graphites was selected on referring to the Materia Medica. 6C Potency is selected according to the susceptibility of the patient. Administration of Graphites yielded marked improvement in the follow-up. Graphites is well known for its action on the skin and hence showed its effect on eczema. However,

this is a single case report and further larger studies with different study designs and large sample sizes are required for determining the efficacy of homoeopathic treatment in cases of eczema.

Declaration of patient consent

The authors certify that they have obtained all appropriate patient consent.

Financial support and sponsorship

Nil.

Conflict of interest

There are no conflict of interest

References

1. Kim B. Atopic Dermatitis: Practice Essentials, Background, Pathophysiology, 2019. Available from: <http://www.emedicine.medscape/article/1049085-overview>. [Last accessed on 2019 Sep 17].
2. Gonzalez M. Definition of Dermatitis-Dermatologic Disorders. MSD Manual Professional Edition, 2019. Available from: <http://www.msmanuals/en,in/professional/dermatologicdisorders/dermatitis/definition-of-dermatitis>. [Last accessed on 2019 Sep 17]
3. Eichenfield LF, Tom WL, Chamlin SL, et al. Guidelines of care for the management of atopic dermatitis: section 1. Diagnosis and assessment of atopic dermatitis. *Journal of the American Academy of Dermatology*, 2014 [PubMed PMID: 24290431]
4. Tsakok T, Woolf R, Smith CH, Weidinger S, Flohr C. Atopic dermatitis: the skin barrier and beyond. *The British journal of dermatology*, 2018, 3. [PubMed PMID: 29969827]
5. Clausen ML, Edslev SM, Andersen PS, Clemmensen K, Krogfelt KA, Agner T. Staphylococcus aureus colonization in atopic eczema and its association with filaggrin gene mutations. *The British journal of dermatology*, 2017. [PubMed PMID: 28317091]
6. Siegfried EC, Hebert AA. Diagnosis of Atopic Dermatitis: Mimics, Overlaps, and Complications. *Journal of clinical medicine*, 2015, 6. [PubMed PMID: 26239454]
7. Hahnemann S, Boericke W, Dudgeon R. *Organon of Medicine*. New Delhi: B. Jain Publishers Private Ltd.,

- 2011.
8. Kent J. Repertory of the Homoeopathic Materia Medica. 6th ed. New Delhi: B. Jain Publishers Private Ltd., 2013.
 9. Schroyens F. Synthesis Repertorium Homoeopathicum Syntheticum. 9.1st ed. New Delhi: B. Jain Publishers Private Ltd., 2008.
 10. Boericke W, Boericke O. Pocket Manual of Homoeopathic Materia Medica Comprising of the Characteristic and Guiding Symptoms of all Remedies (Clinical and Pathogenetic). New Delhi: B. Jain Publishers Private Ltd., 2012, 309-12.
 11. Miller RG. Relationship of Remedies and Sides of the Body. New Delhi: B. Jain Publishers Private Ltd., 2002.