



International Journal of Homoeopathic Sciences

E-ISSN: 2616-4493

P-ISSN: 2616-4485

www.homoeopathicjournal.com

IJHS 2022; 6(3): 12-16

Received: 19-03-2022

Accepted: 14-04-2022

Saima Shamim

Lecturer, Department of
Material Medical, DN De
Homoeopathic Medical College
& Hospital, Kolkata,
West Bengal, India

Amulya Ratna Sahoo

Research Officer (H), S-3,
Regional Research Institute
for Homoeopathy, Guwahati
under CCRH, Ministry of
AYUSH, Govt. of India

Umakanta Prusty

Research officer (H), S-1, Drug
Proving Unit, Bhubaneswar
under CCRH, Ministry of
AYUSH, Govt. of India

Chintamani Nayak

Associate Professor,
Department of Homoeopathic
Materia Medica, National
Institute of Homoeopathy,
Kolkata, West Bengal, India

Corresponding Author:

Amulya Ratna Sahoo
Research officer (H), S-3,
Regional Research Institute
for Homoeopathy, Guwahati
under CCRH, Ministry of
AYUSH, Govt. of India

Role of Homoeopathy in Infectious Eczematous Dermatitis: A Case Report

**Saima Shamim, Amulya Ratna Sahoo, Umakanta Prusty and
Chintamani Nayak**

DOI: <https://doi.org/10.33545/26164485.2022.v6.i3a.591>

Abstract

Background: Skin diseases being one of the most prevalent human ailments continue to increase the disease burden worldwide. The prevalent modern treatments of skin diseases are palliative and very difficult to cure. This case report is an attempt to explore the effectiveness of individualized homoeopathic medicines in the treatment of skin diseases.

Methods: A female patient of 42 years presented with the symptoms of ulceration with itching and sticky discharges coming out from the left palm and webs of fingers. This case of diagnosed infectious eczematous dermatitis was taken at the outpatient department of the National Institute of Homoeopathy, Kolkata and got treated with individualized homoeopathic medicines.

Results: The patient was prescribed initially *Graphites* in LM potency showing much improvement and lastly followed with *Causticum* as the case demanded.

Conclusion: Individualized homoeopathic treatment may be an effective option for the treatment of infectious eczematous dermatitis.

Keywords: Infectious Eczematous Dermatitis, Case report, Homoeopathy.

Introduction

Eczematous dermatitis remains one of the challenging areas in the treatment of skin diseases for the poor response and frequent relapses^[1]. Infectious eczematous dermatitis is characterized by eruptions followed by discharge from a primary infected site^[2]. The lifetime prevalence of atopic dermatitis is 2-10% in adults which if left untreated may lead to poor quality of life^[3]. Skin is the reflector of the deranged internal dynamics and the symptoms that manifest themselves upon the skin are simply an external expression of internal change; the internal economy is usually relieved by such an expression^[4]. Hahnemann mentions never to consider any local disease to be limited to the skin but to consider the disorder of the vital principle and strictly warns against any kinds of external treatment and mentions the hazards of external application^[5]. Psora is the fundamental cause of all diseases. To treat the sick judiciously and to remove the PSORIC DYSCRASIA, a portrait of the totality of symptoms needs to be prepared. For such prescription signs and symptoms of the skin is a great source.

Case presentation

A female patient named Mrs DD aged 42 years presented with the complaint of ulceration with itching and sticky discharges coming out from the left palm and webs of fingers for the last 2-3 years. But for the last 15-20 days complaints were markedly aggravated especially itching at night.

On examination: Ulceration with watery discharges in the left palm and webs of fingers of the left palm. Clinically it was a diagnosed case of Infectious eczematous dermatitis characterized by rashes, red or purple patches scaling and cracking^[1].

Analysis of the case

The patient suffered from electric shock on the same hand 2 years ago after that ulceration got aggravated. Before electric shock, there were few small popular eruptions on the same hand. In the past, recurrent boils in childhood got treated with non-homoeopathic medicine. On the paternal side, the father was suffering from Asthma.

Physical general

Appearance-wise patient was dark-complexioned having a desire for sour things and a tendency to take extra salt. Aversion to sweets and hot food. The patient had aggravation from heat but a tendency to catch cold easily. The tongue was clean and moist. Occasionally patient was suffering from leucorrhoea excoriating in nature.

Mental general

Patient desired company. Used to hesitate, could not make any decision.

Miasmatic analysis

Allen says in eczema all the chronic miasmas are being reflected ^[4]. This case was also multimiasmatic but the predominance of Psora and Syphilis could be found ^[6].

The totality of characteristic symptoms

The following mental, physical generals and particular were

considered for making the totality of symptoms:

- Hesitates, and can't make any decision.
- Aversion of sweet and hot food.
- Tendency to catch a cold easily.
- Hot patient, but catches cold easily.
- Leucorrhoea excoriating in nature.
- Ulceration with itching and sticky discharges coming out from the left palm.
- Itching aggravated especially at night.

Final selection of the medicine (After Consultation with Material Medical)

After consulting material medica *Graphites* was found to cover the totality of symptoms. Therefore, *Graphites* was selected for the case.

Fasting blood sugar (FBS) and postprandial blood sugar (PPBS) was advised to the patient.

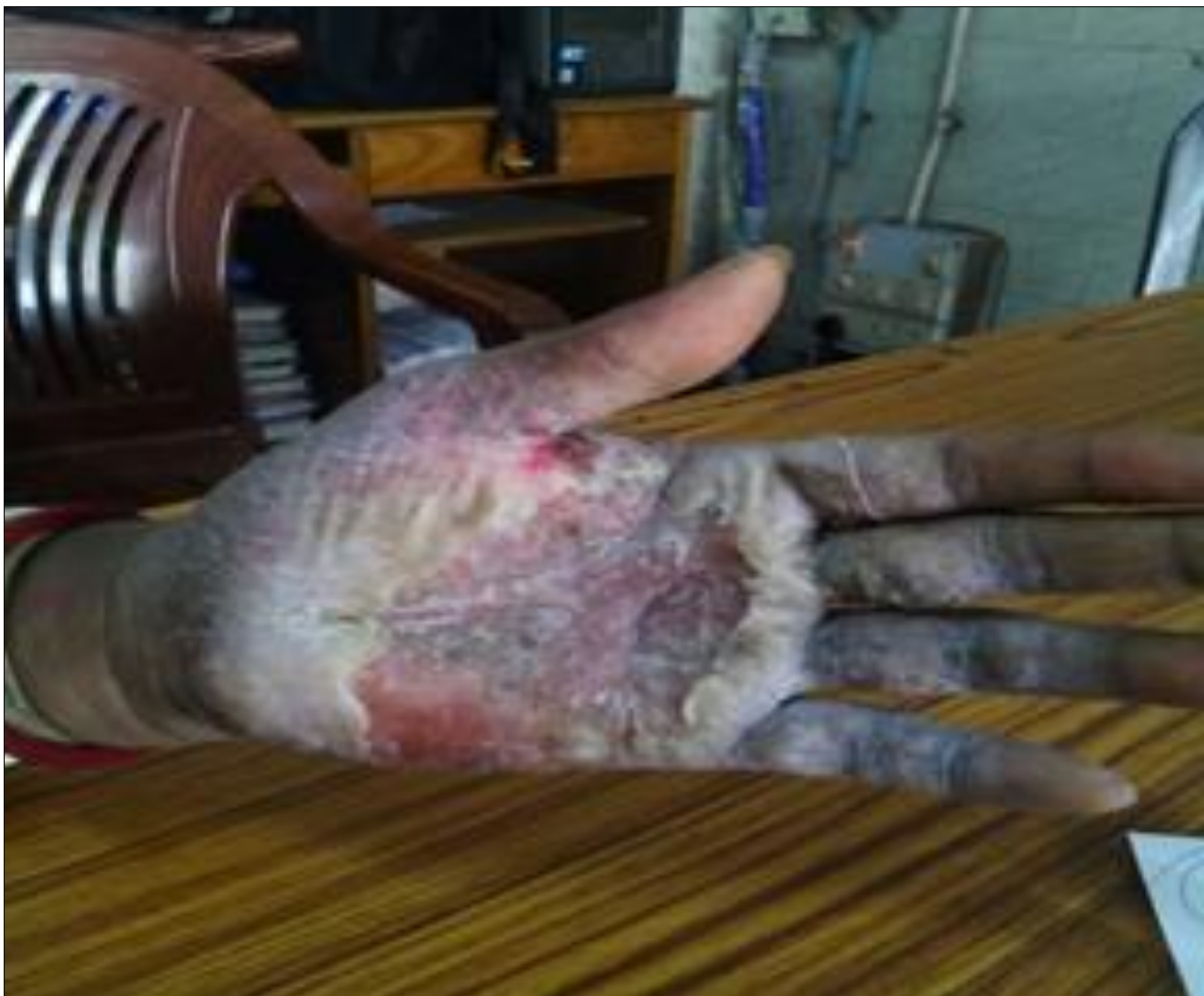


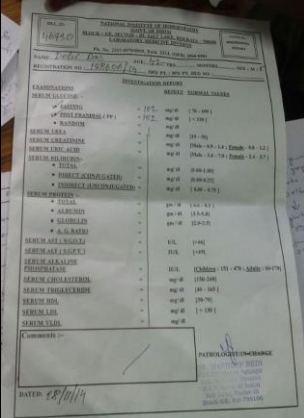


Fig 1: Graphites 0/1, 16 doses, OD X



Prescription

Graphites 0/1, 16 doses, OD X 16 days.

Followed by Graphites 0/2, 16 doses, OD X 16 days and Nihillinum 30/ 2 drachms, 2GLB. OD X 32 days

Table 1: Follow up

Date	Observation	Photographs	Prescription
03/12/14	Ulceration and discharges were markedly diminished. Patient did not take Graphites 0/2		Graphites 0/2, 16 doses, OD X 16 days followed by Graphites 0/3, 16 doses, OD X 16 days Nihillinum 30/ 2 drachms, 2 GLB. OD X 32 days
	Blood report done on 28/11/14 showed FBS-102 mg/dl PPBS- 152 mg/dl		
19/01/15	No trace of ulceration and discharges		Graphites 0/4, 16 doses, ADX 32 days Nihillinum 200/ 2 drachms, 2 GLB. OD X 32 days
20/02/15	No trace of ulceration and discharges. Patient then complained of pain at the lumbar region from which she was suffering for 18-29 yrs. which she forgot to tell in her first visit. Low back pain aggravated from physical exertion.		Graphites 0/5, 16 doses, ADX 32 days Nihillinum 200/ 2 drachms, 2GLB. OD X 32 days

01/04/15	No eruption and discharges. Low back pain was same as before		Graphites 0/6, 16 doses, ADX 32 days Nihillinum 1000/ 2 drachms, 2 GLB. OD X 32 days
06/05/15	No eruption and discharges. Low back pain same as before but the patient gave the modality that low back pain was ameliorated from warmth		Hypericum 10M/2doses OD Nihillinum 1000/ 2 drachms, 2 GLB. OD X 30 days
22/06/15	No eruption and discharges. Low back pain was better		Rubrum1000/ 2drachms, 2 GLB. OD X 30 days
31/08/15	No eruption and discharges. Low back pain was again aggravated. Now Patient gave few more symptoms: <ul style="list-style-type: none"> • Low back pain aggravated on bending forward and more at right side. • Cracking sound at back on motion ameliorated from warmth. • Easily catches cold. • Previous history of aversion of sweet. 		Causticum 1M/ 2 doses in sac lac OD Phytum 30/ 2 drachms, 01 glb. OD X 30 days

Conclusion

Patients suffering from skin diseases withdraw themselves from society due to the people’s obsessive reaction towards them, which leads to further mental distress for the sufferers. The cornerstone of management remains reassurance and counselling of patients and the society too. Investigations are rarely required. It has been an explanatory presentation of a case of a skin disease. There are many more skin diseases which can be treated marvellously by our homoeopathic remedies which should be used on the basis

of their characteristic symptoms. Though treatment of skin diseases is a big challenge for homoeopathy too, with the help of our homoeopathic medicines, this can be treated successfully.

Conflict of interest: None

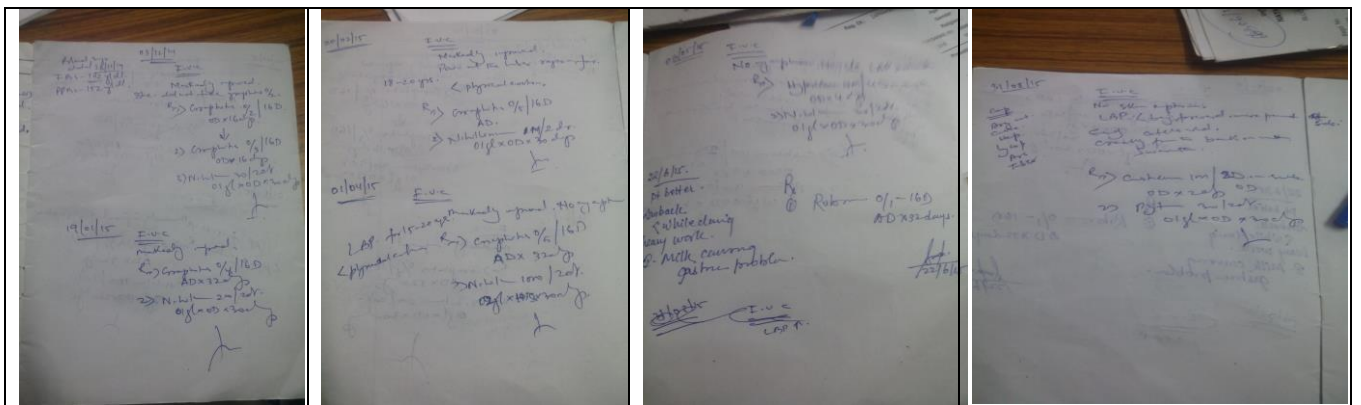
Informed Consent: The patient gave written consent for the treatment and publication of the case.

Table 2: Photographs of the patients showing improvement in the case of Infectious Eczematous Dermatitis

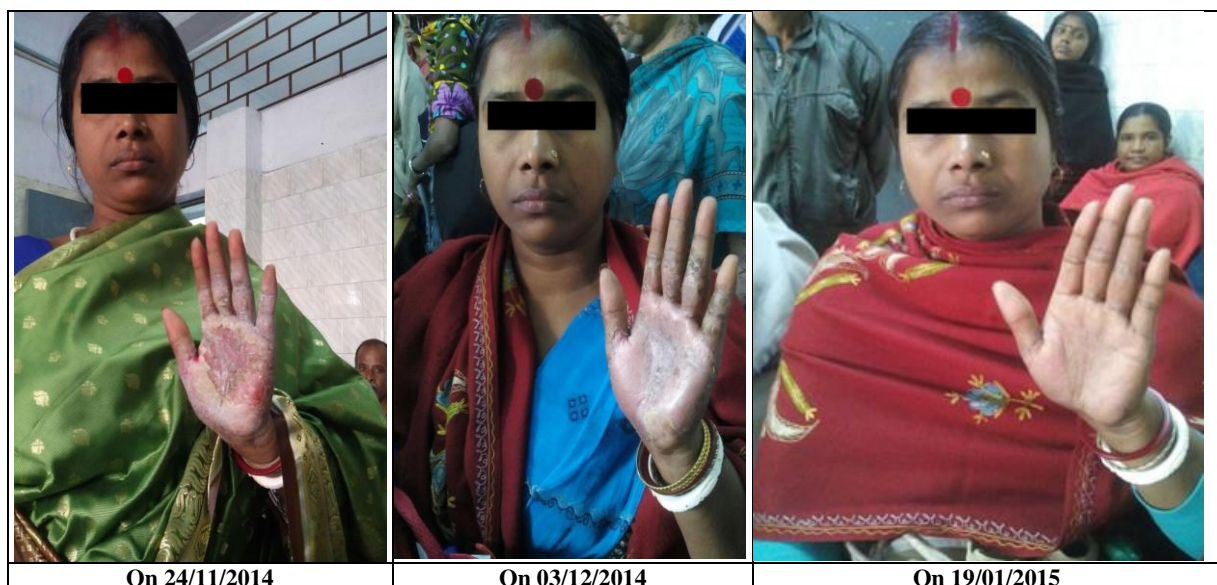



Table 3: Photographs of the follow up of the patient in the case of Infectious Eczematous Dermatitis



References

1. Yamany T, Schwartz RA. Infectious eczematous dermatitis: A comprehensive review. *J Eur Acad Dermatol Venereol*. 2015;29(2):203-208.
2. Bhatia KR, Brodell RT, Bhatia AC, *et al*. Interdigital Tinea: The Forerunner of Infectious Eczematoid Dermatitis. *SKIN The Journal of Cutaneous Medicine*. 2020;4(4):353–356.
3. Nemeth V, Evans J. Eczema. [Updated 2021 Aug 11]. In: StatPearls [Internet]. Treasure Island (FL): Stat Pearls Publishing, 2022.
4. Allen JH. The chronic miasmas with repertory. Rearranged and augmented ed. New Delhi: B. Jain Publishers (P) Ltd, 2007, 196-199.
5. Hahnemann S. Organon of Medicine. 5th & 6th ed. 12th impression. New Delhi: B. Jain Publishers (P) Ltd, 2018, 105-106.
6. Roberts HA. The Principles and Art of Cure by Homoeopathy. 12th impression. New Delhi: B. Jain Publishers (P) Ltd. 2012, 204-231.