



# International Journal of Homoeopathic Sciences

E-ISSN: 2616-4493  
P-ISSN: 2616-4485  
[www.homoeopathicjournal.com](http://www.homoeopathicjournal.com)  
IJHS 2022; 6(3): 20-25  
Received: 07-05-2022  
Accepted: 03-06-2022

**Rinku Yadav**  
Department of Homoeopathic  
Pharmacy, Bakson  
Homoeopathic Medical College  
and Hospital, Greater Noida,  
Uttar Pradesh, India

## Management of polycystic ovarian syndrome through Homoeopathy: A Case Report

**Rinku Yadav**

DOI: <https://doi.org/10.33545/26164485.2022.v6.i3a.593>

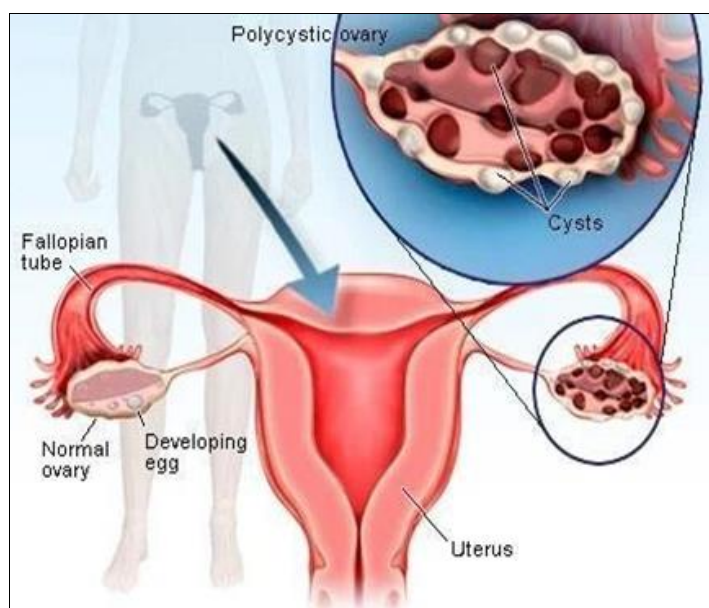
### Abstract

One of the most prevalent metabolic and reproductive disorders in women of reproductive age is polycystic ovarian syndrome (PCOS). Numerous symptoms that women with PCOS experience have a major negative influence on their standard of living. It raises the risk of numerous comorbidities, such as obesity, insulin resistance, type 2 diabetes, cardiovascular disease (CVS), infertility, and psychological conditions. A case of a 27-year-old female with PCOS is addressed. According to the report, she was successfully treated in 7 months by individualized homoeopathic treatment.

**Keywords:** Homoeopathy, Hyperandrogenism, Polycystic ovary, menstrual irregularity, Hirsutism

### Introduction

However not all sufferers have all of these symptoms, polycystic ovarian syndrome (PCOS) is a complicated metabolic, reproductive, and endocrine illness of the sufferers that manifests as irregular menstrual cycles, polycystic ovaries, excessive unwanted hair, and baldness. The word "polycystic" means "having numerous cysts," and PCOS is named after the ovaries' collections of tiny cysts the size of pearls. Due to hormonal deregulation, these cysts are fluid-filled follicles that store eggs which have not yet been released<sup>[1]</sup>.



**Fig 1:** Polycystic Ovarian Syndrome (PCOS)

**Corresponding Author:**  
**Rinku Yadav**  
Department of Homoeopathic  
Pharmacy, Bakson  
Homoeopathic Medical College  
and Hospital, Greater Noida,  
Uttar Pradesh, India

It affects between 5 and 10 percent of females in affluent countries, and similar prevalence is also seen in developing nations like China and India that are undergoing fast nutritional changes as a result of adopting westernized diets and lifestyles (9.13 percent)<sup>[2, 3]</sup>. Infertility, persistent premature ovarian failure, insulin resistance, and hyperandrogenism are some of its clinical characteristics. The risk of substantial metabolic repercussions, such as obesity, type 2 diabetes, and cardiovascular disease, outweighs the significant reproductive

traits [8].

The very first step in treatment is lifestyle adjustment, and it is well-known that even a 5–10% weight reduction has considerable clinical advantages, enhancing psychosocial factors as well as reproductive and metabolic aspects [4, 5]. It is evident that early detection in the morbidity.

The occurrence of any two of the following three traits constitutes (PCOS) according to the Rotterdam criteria

1. Oligo/amenorrhea: less than eight menstrual cycles per year and/or a menstrual absence of 45 days or more.
2. Modified Ferrimanand Gallwey Score of 6 or greater indicates clinical hyperandrogenism.
3. An echo-dense stroma and the presence of more than 10 cysts, each measuring 2 to 8 millimeters in diameter, indicate the existence of polycystic ovaries during a pelvic ultrasound scan [7].

**Following is the case of PCOS treated successfully with Homoeopathy**

A 27 year old unmarried women of height 165 cm and weight 65kg reported on 28 February 2019 with the complaints of irregular menses since 3 years, weight gain around neck, waist and on abdomen since one year. Painful and pustular eruptions over face since one year, Hair growth below chin since 8 months. She also complained of backache and abdominal pain before and during menses since 10years, that was relieved after menses. The patient was lean, thin and had gained weight about 12 kg since last 3 years. She was teacher by profession and she was very conscious about her health and weight. She took allopathic treatment for one year but got temporary relief.

During a pelvic ultrasound (single small GB calculi), polycystic ovaries and cholelithiasis with cholecystitis were discovered. There was no testing for dehydroepiandro-

sterone-sulfate, follicle-stimulating hormone, testosterone, or luteinizing hormone.

**Past History**

History of Dengue in 2012, treated by allopathic treatment

**Family History**

**Father:** H/O diabetes mellitus, hypertension and bypass surgery.

**Mother:** H/o diabetes mellitus

**Gynaecological History**

Menarche at 13 years of age, LMP - 2<sup>nd</sup> December 2018, Duration of period is 5 days, irregular cycle every 2.5-3 month before treatment, Character of blood – bright red with small clots, moderate backache and lower abdominal pain before and during menses.

**Physical Generals**

Patient was vegetarian and was a hot patient (thermal reaction). Her appetite was good and had desire for spicy things and fast food and her thirst was normal. Aversion for sweets and fruits. Her bowel movement were regular and satisfactory, Urine color was pale yellow with no burning.

**Mental Generals**

She was very gentle and polite in nature and weeps easily on smallest matter. She was fearful and anxious and always looking for company of known persons. She loves to do work, can't sit idle. Along with the chief complaint, there were also complaints of unexplained anxiety, especially in crowd and public places with intermittent fear of death.

**Analysis and Evaluation of symptoms**

S. No.	Symptoms	Intensity	Common/Uncommon	Miasm
1.	Irregular menses	3+	Uncommon	Psora
2.	Weight gain around neck	1+	Uncommon	Sycotic
3.	Weight gain around waist and abdomen	2+	Uncommon	Sycotic
4.	Hair growth below chin	1+	Uncommon	Sycotic
5.	Desire for spicy things and fast food	2+	Common	Sycotic
6.	Aversion for sweets and fruits	2+	Uncommon	Psoro- Syphilitic
7.	Fear of Death	2+	Uncommon	Psora
8.	Fear of Crowd	2+	Uncommon	Psora
9.	Anxiety about health	2+	Common	Psora
10.	Workaholic	2+	Common	Sycotic
11.	Company desire	2+	Common	Psora
12.	Weeps easily on smallest matter	2+	Uncommon	Psora
13.	Extrovert	3+	Common	Psora

**Predominant Miasm:** Sycotic

**Basis of Prescription**

**Totality of Symptoms**

Gentle and calm personality, fear of crowds and death, health anxiety Desires spicy foods; weeps easily over trivial matters; weeps when angry. Towards sweets and fruits.

**First Prescription**

*Pulsatilla-200*, TDS for one day along with placebo for one month and regular exercise for 30 min /per day with avoidance of junk /fast foods.

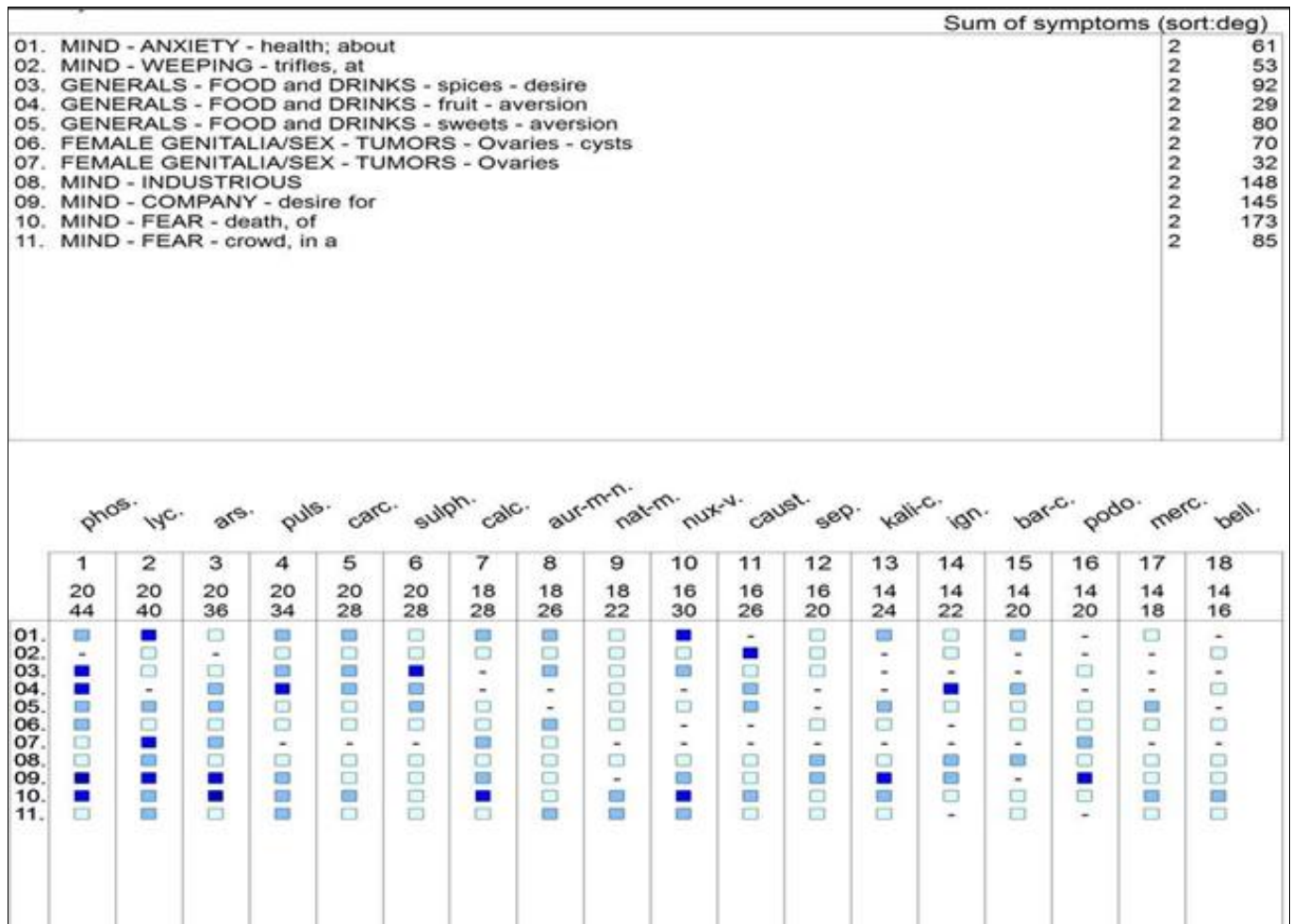


Fig 2: Repertorization chart (Synthesis Repertory)

Table 1: Follow up of the case

S. No.	Date	Complaints	Prescriptions	Weight
1.	28/3/2019	LMP:-10/3/2019 Menses appear, Bright red, small clots, painful but less than before	Sac lac 30/ BD for 1 month	65kg
2.	20/4/2019	LMP:-10/3/2019 Menses not yet appear, backache and lower abdominal pain is same, Distension of abdomen with sour eructation, Appetite decreased	Pulsatilla 1M/stat, Sac lac 30/ BD For 1 month	65kg
3.	30/5/2019	LMP: 25/4/2019 Acne better, black spot remain, no new hair growth, Appetite –good, relief in backache and abdominal pain, distension of abdomen with sour eructation is better	Sac lac 30/ BD for 1 month	63kg
4.	28/6/2019	LMP:-10/6/2019 Acne, black spots- better, no new hair growth	Sac lac 30/ BD for 1 month	62kg
5.	30/7/2019	Amenorrhea and all symptoms remain same	Pulsatilla 1M/3 dose OD for 3 Days	62kg
6.	29/8/2019	LMP:-2/8/2019, Menses appear, relief in all Symptoms	Sac lac 30/ BD for 1 month	61kg
7.	30/9/2019	LMP:-4/9/2019, Relief in all symptoms but slight pain during menses, USG report Done on 15/9/2019 is normal	Sac lac 30/ BD for 1 month	60kg

**Discussion**

The most typical hormonal issue among women of childbearing age is polycystic ovarian syndrome.

Given that its primary goal is to cure the disease at its source rather than merely masking the symptoms, homoeopathic treatment for polycystic ovarian syndrome is extremely effective by nature and unquestionably the finest alternative treatment for this problem. One can recover and regulate the body's vitality for general health with the use of homoeopathic medicines.

For the treatment of various PCOS presentations, the mainstream medical system uses metformin, oral contraceptives, the anti-androgen clomiphene citrate, and thiazolidinedione's. Most clinical signs of PCOS are typically treated with metformin, either on its

own or in conjunction with other drugs. However, 30% of patients experience gastrointestinal intolerance, which includes nausea, abdominal pain, and/or diarrhea. It is prohibited in cases of liver illness and a few other medical disorders [1, 6].

**Conclusion**

If the proper individualized homoeopathic medicine is administered following careful case taking, homoeopathic medications are quite efficient in treating chronic hormonal imbalance without causing any side effects. For PCOS, Cholelithiasis, and Cholecystitis, however, Allopathy recommends hormone-related treatment or surgery. Hyperandrogenism, irregular menstrual periods, and ultrasound-detected polycystic

ovaries in this case all supported the diagnosis of PCOS. Additionally, cholelithiasis and cholecystitis were seen in the patient's ultrasound report. Her cholelithiasis and related cholecystitis were also relieved, in addition to her PCOS. The patient was successfully treated with Pulsatilla 200-1M following

careful case taking and Repertorization. A normal examination was revealed by ultrasonography (USG). Since there have been no recurrences of the complaint in the past 1.5 years, it is likely that PCOS can be successfully managed by individualized treatment.

Patient's Name: _____	Age & Sex : 27 Yrs/F
Ref. Doctor: _____	Date : 26-Feb-19

**ULTRASONOGRAPHY OF WHOLE ABDOMEN**

On B Mode real time ultrasonography of abdomen

Liver is normal in size, shape & homogeneous in echotexture. No evidence of any discrete parenchyma pathology is seen. Portal vein & Intrahepatic biliary radicals are within normal limits.

Gall bladder-- Is dilated shape & increase wall thickness, Single GB Small calculi, of size 5.1mm is seen in gall bladder. CBD normal in caliber.

Pancreas, head, body & tail are normal in echo pattern. No calcification / Abscess / Pseudo cyst. Aorta, IVC & Para aortic lymphnode are normal. No evidence of ascites / pleural effusion.

Spleen is normal its size & shape Echotexture is normal. No SOL is seen in it.

Kidney-Right & Left kidney is normal in size, shape & position. Cortical thickness & Pelvicalyceal echopattern are normal. Corticomedullary differentiation is well maintained. There is no evidence of any hydronephrosis / calculus.

Right & Left iliac region shows no mass in it. Bowel motility & Psoas muscles are normal.

Urinary Bladder: bladder is normal in size shape & capacity. No SOL/calculus is seen in it


Uterus- is normal in size, shape and echotexture

Ovary—Left & right ovary normal in size, shape and with multiple ovarian very small follicles seen in periphery of both ovaries- Necklace appearance

**IMPRESSION:**

- Cholelithiasis with Cholecystitis (Single Small GB Calculi)
- Polycystic Ovary Disease (PCOD)

Advise - CBC, Hormonal Evaluation & Clinical correlation

Checked By 


  
 Consultant Sonologist  
 Dr. Ashish Sharma  
 MBBS (K.G.M.C, LKO)  
 M.D. (A.I.I.M.S, N. Delhi)

Fig 3: Before Treatment

Patient's Name : _____	Age & Sex : 28Y/F
Ref. Doctor : Self	Date : 15-Sep-19

### ULTRASONOGRAPHY OF WHOLE ABDOMEN

On B Mode real time ultrasonography of abdomen

**Liver-** is normal in size shape. No evidence of any discrete parenchyma pathology is seen. Portal vein & Intrahepatic biliary radicals are within normal limits

**Gall bladder** -It is normal in size, shape & wall thickness. No evidence of any acute / chronic Cholecystitis. No SOL/calculus is seen in it. CBD is normal in caliber. No calculus is seen in it.

**Pancreas-** head, body & tail are normal in echopattern. No calcification / Abscess / Pseudo cyst. Aorta, IVC & Para aortic lymphnode are normal. No evidence of ascites / pleural effusion.

**Spleen** - Normal its size & shape. Echotexture is normal. No SOL is seen in it.

**Kidneys-** left & right kidney is normal in size, shape & position. Cortical thickness & Pelvicalyceal echopattern are normal. Corticomedullary differentiation is well maintained. There is no evidence of any hydronephrosis / calculus.

**Right & Left iliac region-** shows no mass in it. Bowel motility & Psoas muscles are normal.

**Bladder** - Normal in size, shape & capacity. No SOL/calculus is seen in it.

**Uterus-** is normal in size (8.9cm x 4.0cm x 5.1cm = vol-97.5cc), shape and echotexture

**Ovary-** Bilateral ovary normal in size, shape and echotexture with multiple follicles seen.

**IMPRESSION:** Normal

**Advice-** CBC, Hormonal Evaluation for MC & Clinically Correlate

  
Checked By


  
Consultant Sonologist  
Dr. Ashish Sharma  
MBBS (K.G.M.C, LKO)  
M.D. (A.I.I.M.S, N. Delhi)

Fig 4: After Treatment

### References

1. Sheehan MT. Polycystic ovarian syndrome: Diagnosis and management. Clin Med Res. 2004;2:13-27.
2. Nidhi R, Padmalatha V, Nagarathna R, Amritanshu R. Prevalence of polycystic ovarian syndrome in Indian adolescents. J Pediatr Adolesc Gynecol. 2011;24:223-7.
3. Heidi A. Polycystic ovary syndrome (PCOS) in urban India. Manlove University of Nevada, Las Vegas. Available from: <http://digitalscholarship.unlv.edu/cgi/viewcontent.cgi?article=thsesdis+serrations> [Last accessed on 2011 Jan04].
4. Bates GW Jr, Propst AM. Polycystic ovarian syndrome management options. Obstet Gynecol Clin North Am. 2012;39:495-506.
5. Ganie MA, Kalra S. Polycystic ovary syndrome - A metabolic malady, the mother of all lifestyle disorders in women-Can Indian health budget tackle it in future? Indian J Endocrinol Metab. 2011;15:239-41.
6. Moghetti P, Castello R, Negri C, Tosi F, Perrone F, Caputo M, et al. Metformin effects on clinical features, endocrine and metabolic profiles, and insulin sensitivity in polycystic ovary syndrome: A randomized, double blind, placebo controlled 6 month trial, followed by open, long-term clinical evaluation. J

- Clin Endocrinol Metab. 2000;85:139-46.
7. Roe AH, Dokras A. The diagnosis of poly cystic ovary syndrome in adolescents. Rev obstet Gynecol. 2011;4:45-51.
  8. Evidence-based guidelines for the assessment and management of ovary syndrome. Jean Halles for women's health. Available from:  
<http://www.med.monash.edu.au/epidemiology/news>. Accessed on 2011 Jan 05.