



International Journal of Homoeopathic Sciences

E-ISSN: 2616-4493

P-ISSN: 2616-4485

www.homoeopathicjournal.com

IJHS 2022; 6(3): 220-222

Received: 16-05-2022

Accepted: 08-07-2022

Dr. Sreevidhya JS

Associate Professor,
Department of Obstetrics &
Gynaecology, MNR
Homoeopathic Medical
College, Sangareddy,
Telangana, India

Dr. Tummala Aarathi Reddy

Assistant Professor,
Department of Obstetrics &
Gynaecology, MNR
Homoeopathic Medical
College, Sangareddy,
Telangana, India

Dr. E Siva Rami Reddy

Professor and HOD,
Department of Practice of
Medicine, MNR Homoeopathic
Medical College, Sangareddy,
Telangana, India

Corresponding Author:

Dr. E Siva Rami Reddy

Professor & HOD
Department of Practice of
Medicine, MNR Homoeopathic
Medical College, Sangareddy,
Telangana, India

Individualized homoeopathic approach in external hordeolum: A case report

Dr. Sreevidhya JS, Dr. Tummala Aarathi Reddy and Dr. E Siva Rami Reddy

DOI: <https://doi.org/10.33545/26164485.2022.v6.i3d.623>

Abstract

A sty is an inflammation of meibomian gland usually noted on the margin of the eyelid at the level of the eyelashes or in the midportion of the eyelid. The case presented here is a girl of recurrent styes was treated with Staphysgria 200, according to symptom similarity with follow up of 6 months this case report is an evidence that homoeopathic medicine if given according to symptom similarity will even prevent the recurrence.

Keywords: Sty, recurrence, Homoeopathy, Staphysgria

Introduction

An eye issue called a sty, commonly referred to as a hordeolum, is frequently seen in both primary and urgent care settings. It is an acute suppurative inflammation of the follicle of the eyelash including the glands of Zies^[1]. It is more common in children and young adult and those who strain due to muscle imbalance or refractive errors. Constant rubbing of the eyes or fingering of the lids and nose are usually associated with recurrent styes^[2]. A hordeolum traditionally appears as a little pustule on the edge of the eyelid. Recurrent styes are common in patients with asthenopia, diabetes mellitus and chronic blepharitis^[3]. In the early phase the glands become red, swollen, hard and painful and usually the whole edge of the lid is oedematous, even resulting in abscess formation, which generally points near the base of one of the cilia^[4].

Although the exact incidence is unknown, hordeolum are fairly common. Every age group and demographic is impacted, while patients between the ages of 30 and 50 have a somewhat higher frequency. There are no recognized variations in occurrence across communities around the world. Patients who suffer from long-term illnesses including seborrheic dermatitis, diabetes, and high serum lipid levels may also be more vulnerable⁵. External eyelid styes can cause a variety of symptoms that differ from person to person. In general, styes are distinguished by the presence of a red lump on the upper eyelid. Other symptoms that are frequently associated with a sty include:

1. A gritty sensation in the eye pain or tenderness in the eye
2. Tearing or leakage of the eyes
3. Light sensitivity due to swollen eyelids
4. Redness and soreness around the eyelid

Case Report

A 18 year old girl had reported to the clinic on 2nd January 2022 with the complaints of sty over the left upper eyelid. The girl also have swelling and redness over upper eyelid with severe pressing pain aggravated by closing eyes and have increased sensitivity to light she also complaints of aching pain in eyes while reading.

History of presenting complaint

Complaints started since 6 months as recurrent attack of styes. She told that she is studying in Engineering and was good in her studies. Since 1 year she is very much addicted in mobile phone so couldn't concentrate more on her studies. Before 1 year her semester result came and she scored very less marks. So her teacher scolded very badly in front of all her friends. She felt insulted and ashamed. After going home she cried very badly and decided not to use mobile unnecessary hear after so had given mobile to her mother. She told after that incident only she had recurrent attack of styes monthly.

Generals

Appetite- Increased
 Urine- Normal
 Thirst- Normal
 Stool-Regular
 Sleep- Disturbed
 Sweat-Normal

Mental General

Angered easily.

Contradiction aggravation

Wants to be in company

Broods by thinking the past when alone

Evaluation of Symptoms

- Ailments from Insult
- Angered easily
- Styes in Left Upper eyelid
- Pressing pain in Left Eye
- Pain Aggravation by Closing Eyelid
- Aching pain in left eye aggravation by straining eyes

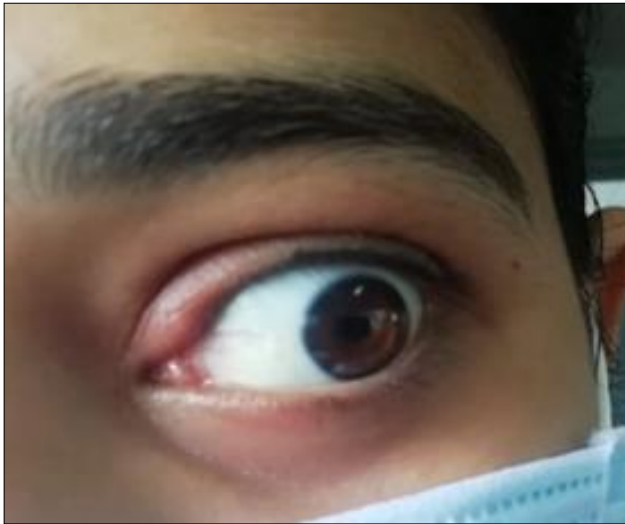


Fig 1: 2nd January 2022

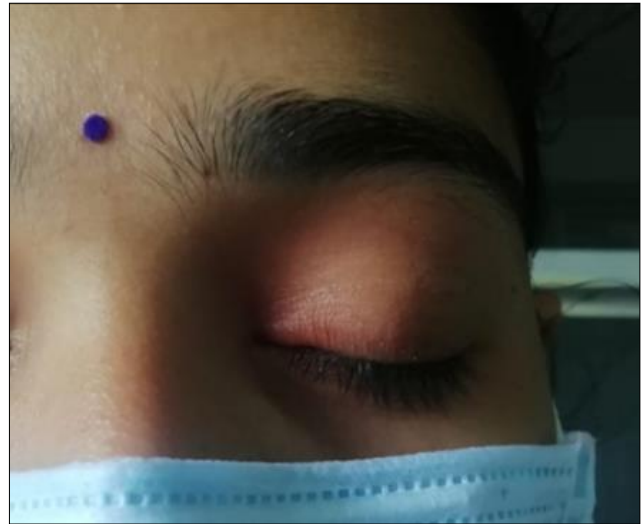

Fig 2: 2nd January 2022

← Repertorisation					
Symptoms: 6 Remedies: 67 Applied Filter					
Remedy Name	Staph	Lyc	Puls	Colch	Con
Totality / Symptom Covered	9 / 5	6 / 2	5 / 2	4 / 3	4 / 2
[Kent] [Eye]Styes: (37)	3	3	3	1	3
[Kent] [Eye]Styes:Left eye: (6)	1			1	
[Kent] [Eye]Pain:Pressing,pressure,etc.:Closing eyes,when: (3)	1				1
[Kent] [Eye]Pain:Aching:Reading.while: (9)	1		2		
[Kent] [Mind]Rudeness (compare insolent):Ailments,from: (7)	3			2	

Fig 3: Shows Repertorisation

Therapeutic Intervention

Case taking had done and repertorisation was done by using Kents method, Staphysagria 200 was selected and

Prescribed on 2nd January 2022.The patient was asked to report after 6 days.

Table 1: Shows the date symptoms Prescription/Dose Justification

Date	Symptoms	Prescription/Dose	Justification
9-1-2022	Stye better, No swelling, No pain, Generals good	Sac Lac/ 1 wk	Improved
16-1-2022	No complaints, Generals-good	Sac Lac/1 month	Improved
17-2-2022	No complaints, Generals-good	Sac Lac/1 month	Improved
16-3-22	No recurrence, No other complaint. Studying good	Sac Lac/1 dose	No recurrence Ask her to visit only if complaints are recurring

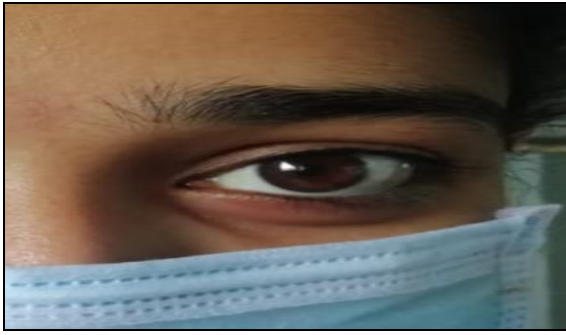

Fig 4: on 9-1-2022

Conclusion

This is a case of recurrent attack of stye. By individualization Staphysagria was selected according to symptom similarity. With single dose of staphysagria 200. Patient feels better and it even prevent the recurrence. Thus proved homoeopathy not only treat the symptoms but the disease from its root.

References

1. Chatterjees BM. Handbook of ophthalmology, 6th edition revised by L.P Agarwal. CBS Publishers & Distributors PVT. LTD, New Delhi, c1997, p. 260.
2. Khurana AK. Comprehensive Ophthalmology, 7th edition, Jaypee brothers medical publishers, New Delhi, c2019, p. 383.
3. Khurana AK. Review of Ophthalmology, Seventh Edition, Jaypee brothers medical publishers, New Delhi, 2019, 131.
4. Parsons Diseases of the Eye, Ramanjit Sihota, Radhika Tandon, 22nd Edition, Reed Elsevier India Private Limited. 2015, 452.
5. <https://www.ncbi.nlm.nih.gov/books/NBK459349/#article-29591.s3>, National library of medicine, Stye, Davis Willmann, Christian P. Guier, Bhupendra C. Patel, Scott W. Melanson, May 2 2022.
6. Allen HC, Adi BS, Rami SR, Reddy E. An open clinical study on the efficacy of Withania somnifera mother tincture in the management of hyperlipidemia. International Journal of Indigenous Herbs and Drugs. 2019 Jun 30:1-6.
7. Reddy SR. Effect of homoeopathic medicine Lycopodium clavatum in urinary calculi. International Journal of Applied Research. 2017;3(1):790-1.
8. Rami SR, Reddy E, Adi BS, Jamadade AK. Efficacy of lactuca sativa in hyperlipidemia: a pilot study. International Journal of Indigenous Herbs and Drugs. 2019 Feb 28:1-7.
9. Allen HC, Keynotes and characteristics with comparisons of some leading remedies of Materia Medica with Bowel Nosodes B Jain Publishers, 2002.
10. William Boericke, New Manual Of Homoeopathic Materia Medica & Repertory, Augmented Edition. Indian books & periodicals publishers New Delhi, December 2015, 106.