



International Journal of Homoeopathic Sciences

E-ISSN: 2616-4493

P-ISSN: 2616-4485

www.homoeopathicjournal.com

IJHS 2022; 6(4): 150-155

Received: 17-08-2022

Accepted: 19-09-2022

**Prof. (Dr.) Chandra Mukhi
Gupta**

Professor, HOD, Department
of Obstetrics & Gynaecology,
Bakson Homoeopathic Medical
College & Hospital; Greater
Noida; Uttar Pradesh, India

Dr. Ashish Goel

Medical Officer, Govt. of Uttar
Pradesh, Lucknow, Uttar
Pradesh, India

Corresponding Author:

**Prof. (Dr.) Chandra Mukhi
Gupta**

Professor, HOD at Obstetrics
& Gynaecology Dept., Bakson
Homoeopathic Medical College
& Hospital; Greater Noida,
Uttar Pradesh, India

Case report: Evidence based homoeopathic treatment of gangrene

Prof. (Dr.) Chandra Mukhi Gupta and Dr. Ashish Goel

DOI: <https://doi.org/10.33545/26164485.2022.v6.i4c.651>

Abstract

Introduction: Gangrene is one of the serious complications found mostly in people who have diabetes or blood vessel disease. Multidisciplinary management of gangrene is necessary to avoid complications like amputation and permanent disability. Homeopathy can prevent amputation by stimulating the immune response of the body. Homeopathy through its unique holistic approach offers a cost effective treatment and management. It helps in healing of wound by increasing the blood circulation of the affected area.

Case Summary: The objective of this case here is that, without amputation of the gangrenous part homoeopathy can treat the Gangrene effectively. Homeopathic medicines boost the immune system and helps in wound healing by establishing the circulation on the affected part. Medicines are selected on individual basis and have an answer to this surgical problem.

Keywords: Amputation, gangrene, homeopathic medicine, immune system

1. Introduction

Gangrene is a form of necrosis of tissues with superadded putrefaction. Gangrene happens when tissues in body die after a loss of blood supply. Gangrene is usually common in people who have vascular disease. People with combination of risk factors (like Diabetes mellitus Type 2, smoking, F/H are at greater risk^[2]. Diabetes is a serious condition. As per the IDF atlas -2021, it's estimated that 537million people have diabetes, and this number is projected to reach 643 million by 2030^[3]. Risk of amputation is high in diabetic's. In India there are about 1lakh of amputations done every year due to diabetes. The treatment of amputation is costly for a common man. The mortality rate among people who undergo amputation is very high, especially if they have peripheral vascular disease^[11].

Gangrene of lower extremities is one of the main complications of diabetics^[13]. In dry gangrene there is a classical line of demarcation between necrotic and normal tissues with little or no discharge or pus. As tissues dry up it changes colour, may be from blue to black and tissues often falls up. Dry gangrene may lead to wet gangrene if the affected area is not cleaned and gets superadded with infections. Gas gangrene is caused by a specific infection from clostridium perfringens, which releases gas and produces toxins; this causes bubbling of tissues^[1].

As a system of medicine, Homeopathic treatment can avoid amputation of the limb. A few case reports on homoeopathic treatment of Gangrene due to diabetes has been successfully documented^[4]. Case report on Integrative management of diabetic foot ulcer with Homoeopathy and standard care by Perssis Gadde^[9]. Five case studies on Gangrene by Vithoukias G^[8] and A case report on Management of Diabetic Foot Ulcer by Homoeopathy by Pal PP, Sadhukhan S^[15].

Case report

On 19th December,2019, a 58 years old male patient who was a known diabetic for the past 15 years presented with an gangrene on the calf of the right leg for 1year which was very painful on slight walking even hanging of leg from bed.

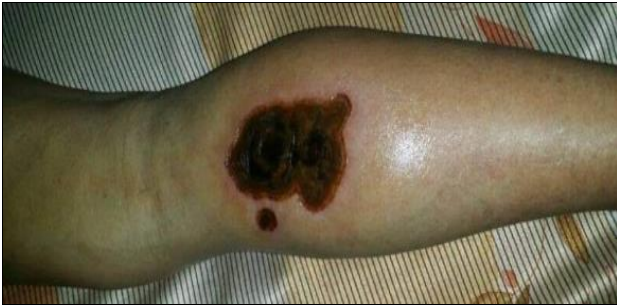

Fig 1: 12th December, 2019

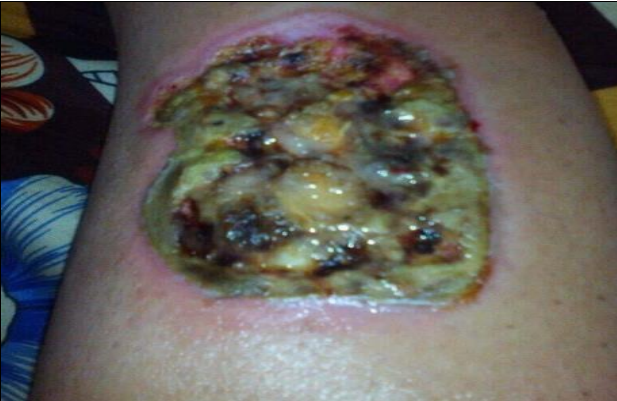

Fig 2: 30th December, 2019

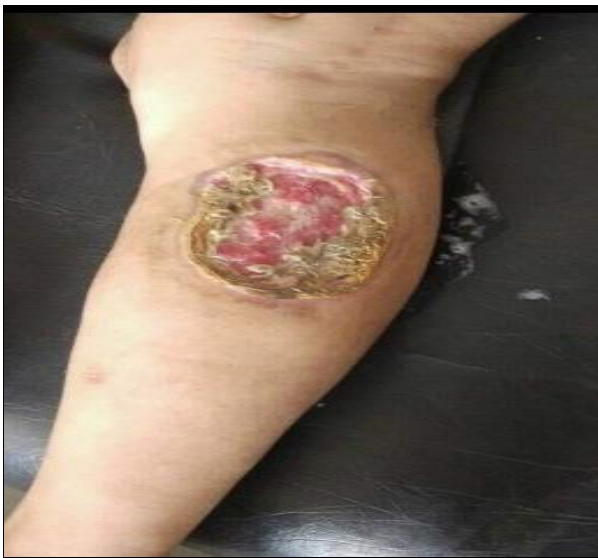

Fig 3: 28th February, 2020

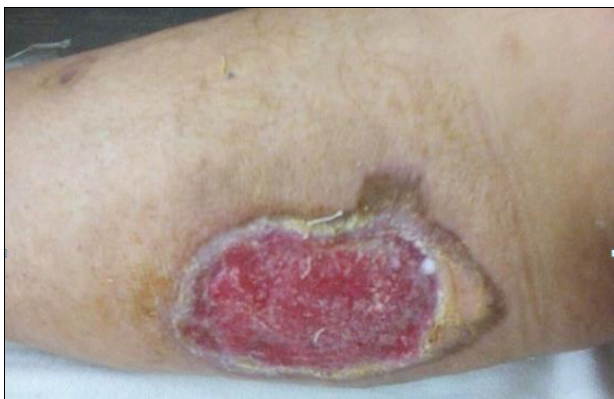

Fig 4: 27th June, 2020

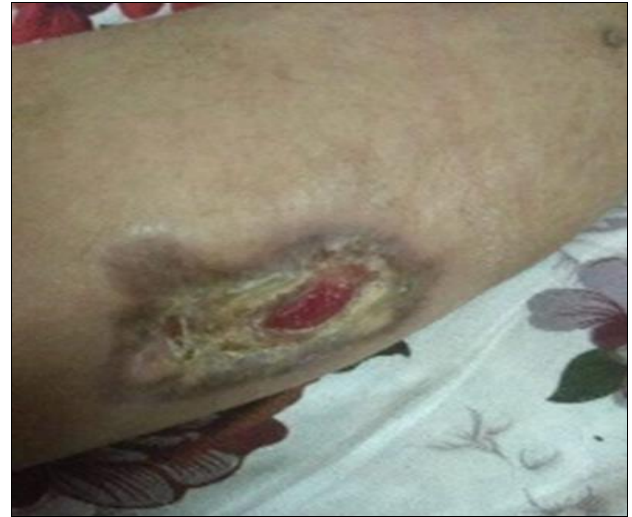

Fig 5: 28th Aug, 2020

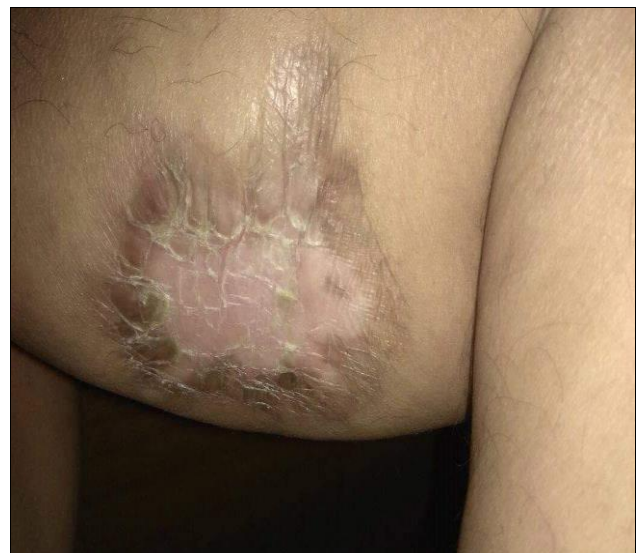

Fig 6: 27th September, 2020

History of presenting complaints

A male patient of 58 yrs visited for treatment in December 2019. With the following complaints for Gangrene on the right lower leg. Since 6 months patient was a known diabetic for 15years. He took family responsibilities earlier because of death of his parents. To relief stress he started smoking regularly. He was also taking alcohol. In 2004, he was diagnosed with diabetes. So he started taking *Metformin* 500mg morning and evening. He was in the habit of smoking 10-12 cigarettes a day. In 2016 he was diagnosed with gangrene of the right lower leg, which was confirmed by X-ray report and arterial colour Doppler. Gangrene was very painful. Patient was mostly bedridden. Even slight walking; hanging of leg from bed aggravates his pain severely. So he can only walk for only few km. He was taking 4-5 painkillers daily, oral hypoglycaemic drug along with blood thinner but still there was not much relief so patient was in a very distressing condition.

Past history

At the age of 33years he diagnosed with diabetes since then he was on oral hypoglycaemic drugs.

At the age of 35 years he suffered from Malaria, Dysentery and relieved.

At the age of 50 years he suffered from fungal infection of lower leg. Took allopathic treatment and relieved.

Family history

Grandfather was diabetic. Father was diabetic and died at age of 45 yrs due to heart attack. Mother also died and was also diabetic.

Physical Generals

- Desire - alcoholic drinks (++) , tea.(+)
- Appetite -normal
- Thirst -late night or middle of night
- Constipation -occasionally
- Urine- normal
- Perspiration – clammy and sticky.(++)
- Thermal reaction – cannot tolerate cold in general; complaints<cold(+++)
- Weakness (++)

Mental generals

- Desire company
- Greatest grief was death of his parents.
- Anxiety about his health
- Lack of self confidence
- Fear of alone, disease.
- Brooding

Life space investigation -The patient was a business man. Patient belongs to the middle class socio- economic status. Parents died early so he took all family responsibilities earlier. To relief extra burden and stress he started smoking at an earlier age.

General physical examination

- Weight – 60 kgs, Height – 5'4'', Jaundice – Nil, Anaemia – Nil, Cyanosis- Nil, generalised lymphadenopathy – Nil, Pulse- 74/min, Temperature – 98.6F, Respiratory rate- 14/min, BP – 130/80mmHg.
- Skin – black on the affected area of the right lower leg

Local Examination

Gangrene was present on the calf muscle of right lower leg. An edge has clear demarcation between healthy & necrotic tissues. There was blackish discolouration of skin and skin was cold to touch. There was no discharge coming from the affected area. Numbness was present along with severe pain.

Investigation findings

- Fasting blood sugar –272mg/dl
- Post Prandial blood sugar – 463mg/dl
- Urine – sugar – NIL

Clinical Diagnosis

Dry Gangrene

Totality of symptoms

- Gangrene
- Diabetes mellitus - weakness
- Sensitive to cold air
- Anxiety about health
- Leg Pain aggravate walking
- Desire alcoholic drinks
- Fear of being alone
- Perspiration - clammy, sticky
- Ailments from smoking
- Numbness of lower limb

Selection of remedy

Based on the Repertorisation result [Chart 1]

The case was repertories with the following rubrics, *Arsenicum album* 30c was prescribed based on the following symptoms. Oral hypoglycaemic drugs were continued as before. Diet restriction, quitting of smoking and alcohol was advised.

General management

Calendula mother tincture was prescribed for external application. The dressing was done by him. He was advised by the endocrinologist to continue oral hypoglycaemic drugs and to take adequate rest and proper diet.

Reportorial chart

Follow up Criteria

In beginning of treatment there was unbearable pain in gangrene. His blood sugar was FBS 272 mg/dl, PPBS 463 mg/dl [Figure1], despite of taking oral hypoglycemic drugs. In 2nd follow-up there was only slight decrease in pain and homoeopathic aggravation can be seen [Figure 2]. In his 4th follow-up after around 3months of treatment [Figure 3] the blood sugar level was reduced to FBS 150 mg/dl and PPBS- 350 mg/dl. During 6th follow up after 5 months of treatment [Figure 4] blood sugar comes down to FBS120mg/dl, PPBS 210mg/dl. And condition of the patient was improving. In his 8th follow up, done after 7 months of treatment [Figure 5], blood sugar level was reduced to FBS 105mg/dl, PPBS 148mg/dl so the *Metformin* dose was reduced to 250mg/dl/BD/daily. Patient condition much improved clinically. After 8months of treatment [Figure 6], blood sugar level comes down to normal {FBS- 97mg/dl, PPBS – 130mg/dl}. Gangrene was completely healed with *Arsenic album* and all symptoms of the patient were markedly improved. Pain completely disappeared. So patient discontinued the treatment. Gangrene and associated symptoms were monitored. The detailed follow-up of the case has been presented in the [Table1]. During treatment sugar level of the patient was regularly monitored by his endocrinologist.

The modified Naranjo criteria^[12], proposed by the clinical data working group of the homeopathic pharmacopoeia of the United States, for assigning the casual attribution between homeopathic medicine applied to the changes occurred in the patient , have been applied to this case and the total score outcome is 10. [Table 2]

Table 1: Follow-up on gangrene case

Gangrene on the right leg	DATES									
	12th December, 2019	30th December, 2019	15th January, 2020	28th February, 2020	28th April, 2020	27th June, 2020	30th July, 2020	28th August, 2020	27th September, 2020	
pain	persistent	slight better	slight better	slight better	moderate	moderate	much better	much better	Much relief	
skin color/texture	black, shiny, dry	yellow, bubbles appear	redness	red	red	redness	much reduced	slight redness	normal healed skin	
discharge	absent	present	reducing	absent	absent	absent	absent	absent	absent	
numbness	present	present	present	slight better	slight better	slight better	much reduced	much reduced	no numbness	
signs of inflammation	present	present	present	reducing	reducing	reducing	much reduced	no sign	no sign	
line of separation	present	present	present	present	reducing	reducing	reducing	much reduced	no line of separation	
Blood Sugar										
FBS in mg/dl	272	202	188	150	152	120	120	105	97	
PPBS in mg/dl	463	410	395	350	268	210	180	148	130	
History of taking Allopathic medicine										
Merformin dose	500mg/BD/daily	500mg/BD/daily	500mg/BD/daily	500mg/BD/daily	500mg/BD/daily	500mg/BD/daily	250 mg/BD/Daily	250 mg/BD/Daily	250 mg/BD/Daily	
Perspiration	sticky	sticky	sticky	sticky	sticky	less sticky	less sticky	normal	normal	
weakness	severe	severe	severe	moderate	moderate	moderate	mild	mild	no	
anxiety	present	present	present	slight reduced	same	less	no	no	no	
coldness of extremities	present	present	present	reduced	reduced	much reduced	absent	absent	absent	
Treatment	* Ars alb 30C, 7doses, once a week *SL -4pills thrice daily	*SL for 28days	*SL 30 for 15 days	*SL 30 for 45 days	*Ars album 200C, 5pills 3 water doses *OD for 3days. *SL for 1mon	*SL for 1mon	*SL for 1mon	*SL for 1mon	*SL for 1mon	

Abbreviations: OD – Once daily, BD- Twice daily, TDS – Thrice daily

Discussion

The above case was of a case of dry gangrene. This case report shows the importance of homoeopathic treatment in dry gangrene. Patient took homoeopathic treatment in spite of conventional treatment because there was no improvement in his condition. Patient was not able to tolerate pain despite of taking 4-5 painkillers daily. At this stage patient comes to consult Homoeopathic physician. The homoeopathic remedy *Arsenicum album 30c*, was prescribed taking into consideration of patient as a whole. In the next visit patient complain of discharging and bubbling sensation over the affected part. This clearly shows homoeopathic aggravation which is a good sign. During further follow-ups healing accelerates and marked improvement seen in his all symptoms and also on the blood sugar levels [Table 1: follow-up on gangrene case]. The total score of outcome 10 as the Modified Naranjo Criteria in this case, shows the definite causal attribution of homoeopathic treatment with the outcome. [12]

Thus this case shows a miraculous cure of gangrene with homoeopathic treatment. The patient was advised to continue the oral hypoglycaemic drugs but all other medicines such as antibiotic, multivitamins, blood thinners etc. were stopped. The auxiliary management such as diet regimen, proper leg care and dressing with homoeopathic external application-*Calendula Q* (mother tincture) was advised for dressing daily. The improvement assessment was done objectively by taking periodical photographs of the gangrene before, during and at the end of treatment. The gangrene took up to 9 months to completely heal.

As per literature *Arsenicum album*, is an important remedy for gangrene, chilliness, anxiety about health, right sided complaints, diabetes mellitus and blackening of skin [6].

However, 50% of new cases of diabetes mellitus can be adequately controlled by diet [14]. The importance of life style changes such as taking regular exercise, healthy diet, reducing alcohol consumption should not be underestimated in improving diabetes. Patient should also be encouraged to stop smoking.

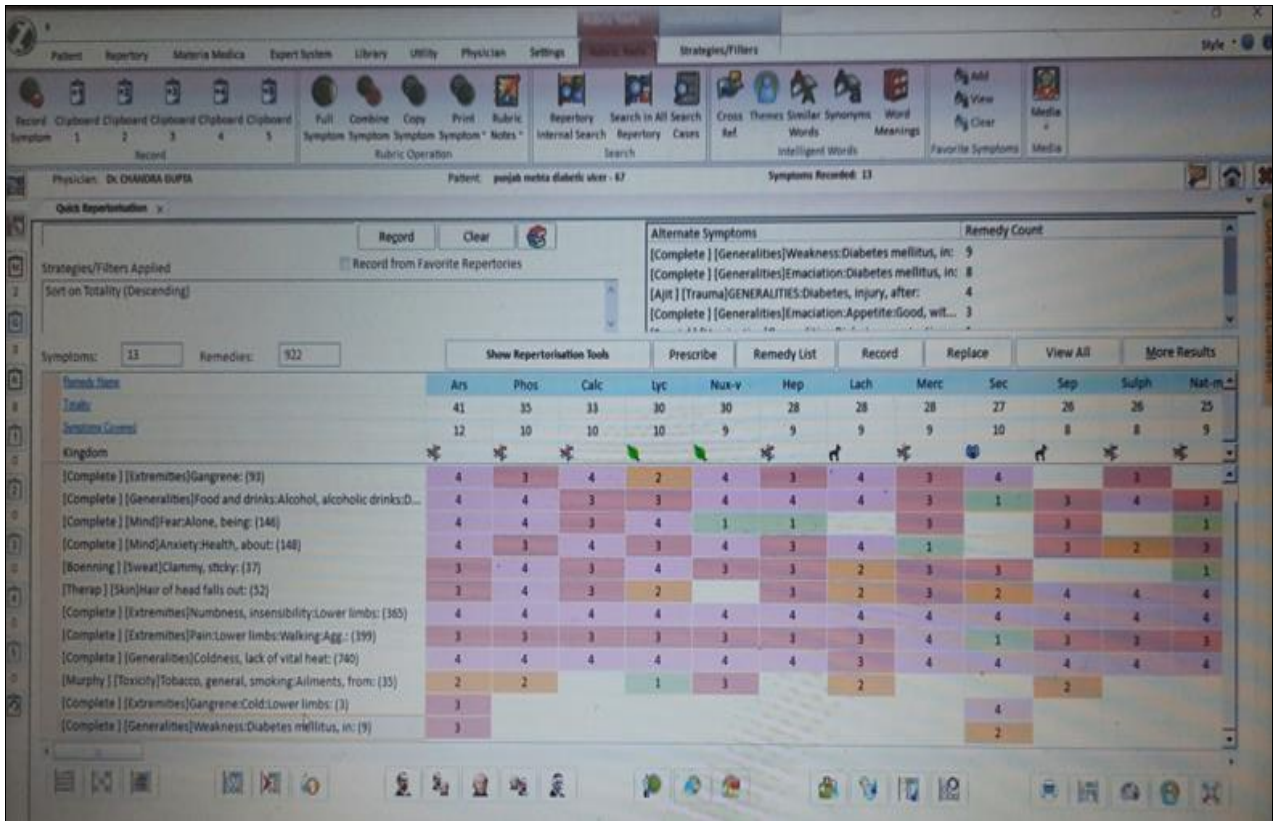


Chart 1: Repertorial Chart (jpg)

Conclusion

Chronic disease in a person is the reflection of the patient to the unfavorable nurture during his life time. The body functions and react as a whole. Emotions and thoughts have a great influence on the function of the body [16]. Our immune system not only responds to stimuli from outside the body but also to those from within mind. So a holistic treatment is require to keep the disease process in check. Homoeopathy considers a human as one unit. It is not a science of therapeutics, it is based on expressions of the symptoms individualistically in different manners [10]. In the above case we consider unhealed wound turned into

gangrene due to chronic arterial occlusion or long standing peripheral vascular disease [14]. Homoeopathy stimulates the blood circulation of the affected area through its immune mechanism, so the cure is achieved and health is re-established.

This case report clearly provide a rationale for the use of homoeopathy in the treatment of Gangrene. Homoeopathic treatment can be thought of primarily as an adjuvant to conventional treatment (Modern System of Medicine) for an early recovery and to save the suffering humanity from such deadly gangrene.

Table 2: Assessment of outcome with Modified Naranjo algorithm:[12]

Table 2: Assessment of Outcome with modified Naranjo Algorithm			
Modified Naranjo Algorithm	Yes	No	Not Sure or N/A
1. Was there an improvement in the main symptom or condition for which the homeopathic medicine was	+2		
2. Did the clinical improvement occur within a plausible timeframe relative to the drug intake?	+1		
3. Was there an initial aggravation of symptoms?	+1		
4. Did the effect encompass more than the main symptom or condition (i.e., were other symptoms ultimately improved or changed)?	+1		
5. Did overall well-being improve? (suggest using validated scale)	+1		
6A Direction of cure: did some symptoms improve in the opposite order of the development of symptoms of the			0
6B Direction of cure: did at least two of the following aspects apply to the order of improvement of symptoms: —from organs of more importance to those of less importance? —from deeper to more superficial aspects of the individual? —from the top downwards?			0
7. Did "old symptoms" (defined as non-seasonal and non-cyclical symptoms that were previously thought to have resolved) reappear temporarily during the course of improvement?			0
8. Are there alternate causes (other than the medicine) that—with a high probability— could have caused the improvement? (Consider known course of disease, other forms of treatment, and other clinically relevant		+1	
9. Was the health improvement confirmed by any objective evidence? (e.g., laboratory test, clinical observation,	+2		
10. Did repeat dosing, if conducted, create similar clinical improvement?	+1		
Total Score			10

Modified Naranjo algorithm

Note: Maximum score = 13, minimum score = - 6.

References

1. Mohan H. Textbook of Pathology. Textbook of Pathology; c2015.
2. Davidson's principles and practice of medicine | WorldCat.org [Internet]. [cited 2022 Sep 18]. Available from: <https://www.worldcat.org/title/davidsons-principles-and-practice-of-medicine/oclc/34558340>
3. Sun H, Saedi P, Karuranga S, Pinkepank M, Ogurtsova K, Duncan BB, *et al.* IDF Diabetes Atlas: Global, regional and country-level diabetes prevalence estimates for 2021 and projections for 2045. *Diabetes Res Clin Pract.* 2022 Jan 1, 183.
4. Teut M, Van Haselen RA, Rutten L, Lamba CD, Bleul G, Ulbrich-Zürni S. Case Reporting in Homeopathy-An Overview of Guidelines and Scientific Tools. Vol. 111, Homeopathy. Georg Thieme Verlag; c2022, p. 2–9.
5. Deekshitulu V. Alternative Medicine Physician BP, Deekshitulu V BP. Treatment of Gangrene in Homeopathy. *International Journal of Traditional and Complementary Medicine*, 2018, 3.
6. Kent JT. Lectures on homeopathic materia medica. 1916, 1808. Available from: <http://peeyushtewari.tripod.com/pdf/kentmm.pdf>
7. The Essence of Materia Medica (PDFDrive) (1):1-132.
8. Vithoulkas G, Mahesh S, Mallappa M. Gangrene: Five case studies of gangrene, preventing amputation through Homoeopathic therapy. *Indian J Res Homoeopath.* 2015;9(2):114.
9. Gadde P, Narasimhulu Dc, Rompicherla KR. Integrative management of diabetic foot ulcer with Homoeopathy and standard care. *Indian J Res Homoeopath.* 2018;12(3):180.
10. Treatment of Gangrene in Homeopathy - eSciPub Journals [Internet]. [cited 2022 Sep 20].
11. Raj P, Sharma PK, Ambily B. Assessing the reliable symptoms of rhus tox and kali carb in the treatment of lumbar spondylosis with sciatica syndrome—an observational study. *International Journal of Alternative and Complementary Medicine.* 2020 Jun 30, 11-6.
12. Cho NH, Shaw JE, Karuranga S, Huang Y, da Rocha Fernandes JD, Ohlrogge AW, *et al.* IDF Diabetes Atlas: Global estimates of diabetes prevalence for 2017 and projections for 2045. *Diabetes Res Clin Pract* [Internet]. 2018;138:271-81. Available from: <https://doi.org/10.1016/j.diabres>.
13. Lamba CD, Gupta VK, Van Haselen R, Rutten L, Mahajan N, Molla AM, *et al.* Evaluation of the Modified Naranjo Criteria for Assessing Causal Attribution of Clinical Outcome to Homeopathic Intervention as Presented in Case Reports. *Homeopathy* [Internet]. 2020 Nov 1 [cited 2022 Sep 25];109(4):191-7.
14. Nishiyama S. Dermatological complication of diabetes mellitus. *Nippon rinsho Japanese J Clin Med.* 1991;49(5):307–12.
15. Lal BS. Diabetes: Causes Symptoms And Treatments Diabetes: Causes, Symptoms And Treatments, 2016 January.
16. Pal PP, Sadhukhan S, Saha S. *International Journal of Ayush Case Reports (IJA-Care)* Management of Diabetic Foot Ulcer by Homoeopathy-A Case Report.
17. Tafel LH, Hughes R, Dudley P, Hempel CJ. The Chronic Diseases, their Peculiar Nature and their Homeopathic. 1845, 53.

How to Cite This Article

Gupta CM, Goel A. Case report: Evidence based homoeopathic treatment of gangrene. *International Journal of Homoeopathic Sciences.* 2022;6(4):150-155.

DOI: <https://doi.org/10.33545/26164485.2022.v6.i4c.651>

Creative Commons (CC) License

This is an open access journal, and articles are distributed under the terms of the Creative Commons Attribution-NonCommercial-ShareAlike 4.0 International (CC BY-NC-SA 4.0) License, which allows others to remix, tweak, and build upon the work non-commercially, as long as appropriate credit is given and the new creations are licensed under the identical terms.