



# International Journal of Homoeopathic Sciences

E-ISSN: 2616-4493

P-ISSN: 2616-4485

[www.homoeopathicjournal.com](http://www.homoeopathicjournal.com)

IJHS 2022; 6(4): 215-220

Received: 03-08-2022

Accepted: 04-09-2022

**Dr. Parizad Damania**

Principal, Chandaben Monhanbhai Patel Homeopathic Medical College, Vile Parle, West, Mumbai, Maharashtra, India

**Dr. Gausia Sayed**

Head of Department & Associate Professor in Case taking and Repertory, Smt. Chandaben Monhanbhai Patel Homeopathic Medical College, Mumbai, Homeopathic OPD/IPD Consultant at Shree Mumbadevi Homeopathic Hospital, Vile Parle (West), Mumbai and Honorary Consultant at Holy Spirit Hospital and Shakuntala Memorial Hospital, Andheri, Mumbai, Maharashtra, India

**Dr. Abhinandan Hulaman**

Associate Professor of Homoeopathic Materia Medica, Smt. Chandaben Monhanbhai Patel Homeopathic Medical College, Mumbai, Homeopathic OPD/IPD Consultant at Shree Mumbadevi Homeopathic Hospital, Vile Parle (West), Mumbai, Maharashtra, India

**Dr. Chinmayi Haldankar**

Ambadnya Homoeopathy Clinic, Prabhadevi, Mumbai, Maharashtra, India

**Dr. Sana Baig**

Ambadnya Homoeopathy Clinic, Prabhadevi, Mumbai, Maharashtra, India

**Kinjal Pamecha**

Fourth year B.H.M.S., at Smt. Chandaben Monhanbhai Patel Homeopathic Medical College, Mumbai, India

**Corresponding Author:****Dr. Gausia Sayed**

Head of Department & Associate Professor in Case taking and Repertory, Smt. Chandaben Monhanbhai Patel Homeopathic Medical College, Mumbai, Homeopathic OPD/IPD Consultant at Shree Mumbadevi Homeopathic Hospital, Vile Parle (West), Mumbai and Honorary Consultant at Holy Spirit Hospital and Shakuntala Memorial Hospital, Andheri, Mumbai, Maharashtra, India

## Significance of constitutional in atopic dermatitis

**Dr. Parizad Damania, Dr. Gausia Sayed, Dr. Abhinandan Hulaman, Dr. Chinmayi Haldankar, Dr. Sana Baig and Kinjal Pamecha**

DOI: <https://doi.org/10.33545/26164485.2022.v6.i4d.661>

**Abstract**

Atopic Dermatitis is an intermittent severely pruritic eczematous dermatitis with scaly erythematous patches, vesiculation, crusting and fissuring. It is a reaction pattern that presents with variable clinical and histological findings. It affects at least 20% of school children and 5-10 % of adults. It constitutes atopy, a condition of altered reactivity to common and mild environmental stimuli. Mainly affects the face and flexures of infants and children. In infants, eczema often starts on the face before spreading to the body. There is positive family history or past history of atopic conditions like asthma, etc.

**Keywords:** Atopic dermatitis, mental characteristics, constitutional prescription

**Introduction**

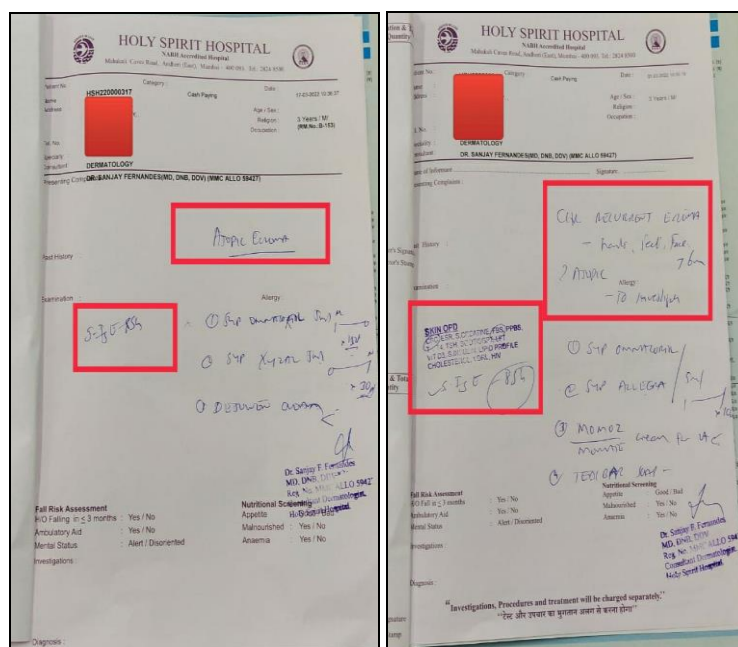
Atopic Dermatitis is itchy and scaly condition. The distribution of the rash vary with age. Clinical diagnostic criteria can be made by history of atopic diseases, dry skin, visible flexural eczema and starting in first 2 years of life.

According to 6th edition of Organon of Medicine, Aphorism 153 explains about importance of characteristic symptom for selection of the similimum.

**Clinical case presentation**

A 4 year old male child came with the complaint of itching below right eye macular reddish patch and on left elbow region and left foot since 1 year. There is dryness and scaling over the patches. These were recurrent patches and patient had taken many allopathic medications with no such relief.

Took allopathic treatment from dermatologist & paediatrician on and off since 1 ½ years but no relief.



**Fig 1, 2: Prescription from the Dermatologist**

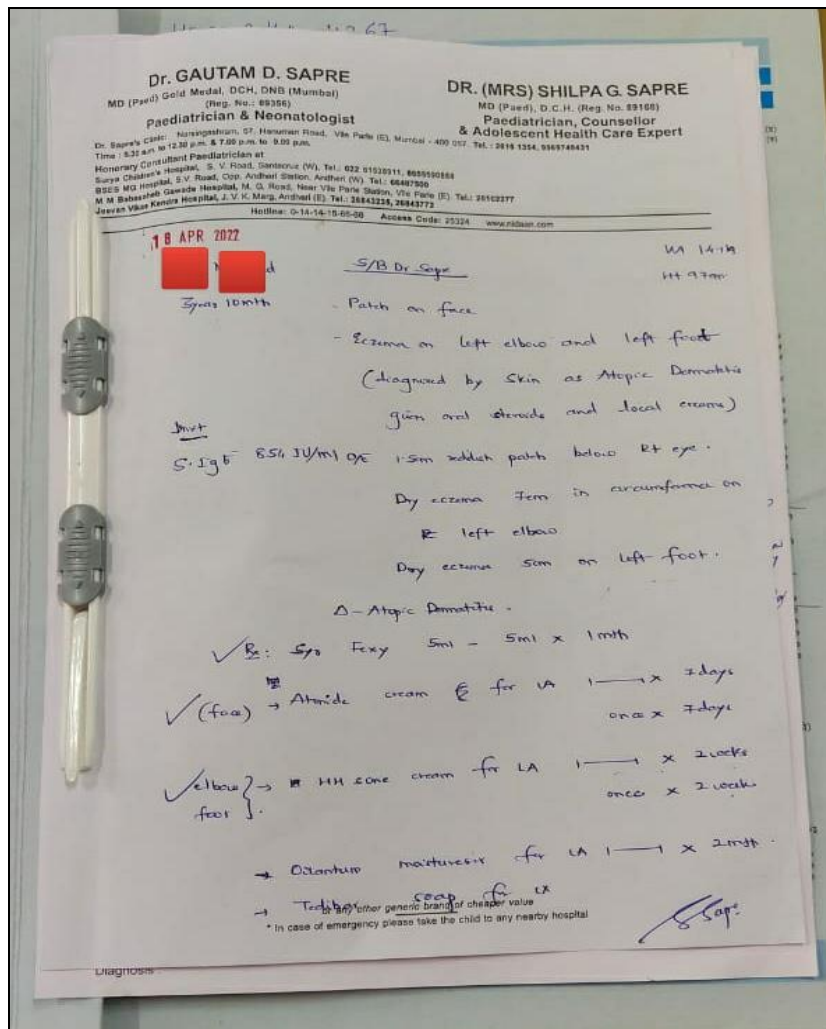


Fig 3: Prescription from paediatrician

**Physical generals:** Appearance: fair moderate built, mischievous boy  
Appetite: normal; Thirst: normal; Thermals: Chilly patient  
No complaints in urine and stools.  
With no significant family history.  
Past history of recurrent patches at same places with no

relief from allopathic medications.  
Family history – Grandfather: itching in hands  
Father: Tinea in right upper extremity  
Elder brother: Eczema

#### Clinical appearance

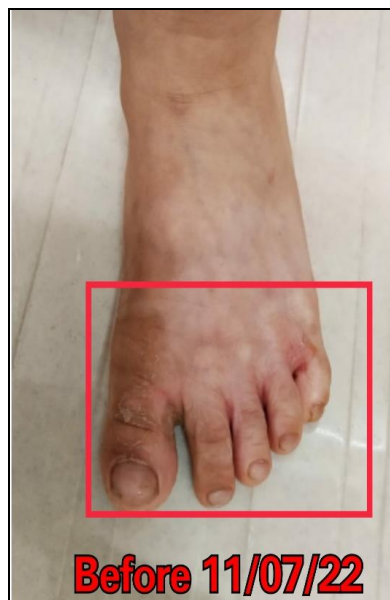

Fig 4: Macular eruptions over left foot

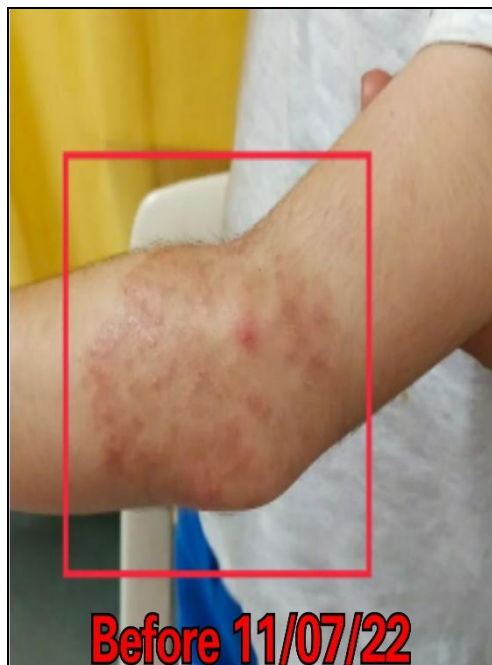

Fig 5: Macular eruptions over left elbow

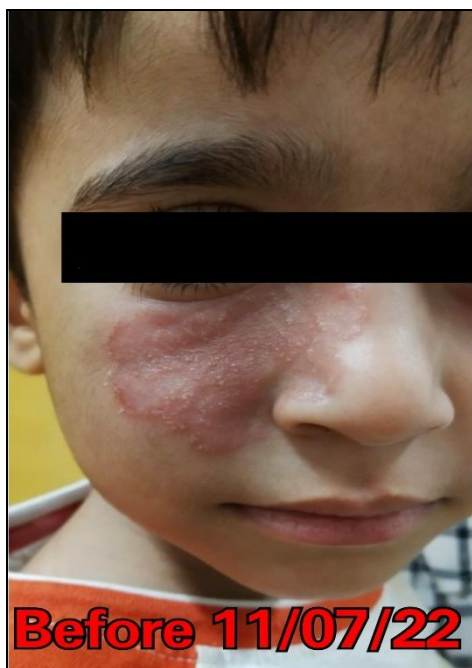

Fig 6: Macular eruption below right eye. WEB – SHAPED Appearance

### Mental characteristics

Patient was very restless, hyperactive child - mischievous running around the o.p.d, full of energy, couldn't sit in one place. He desires to play outdoor games and he likes to listen music. The patient is good in his curricular activities.

### Child development

Delivery – FTND

Milestones – All normal as per age

H/O Pica – Absent

Vaccination – done as per the schedule

Birth weight – 3 kg

### Clinical diagnosis – Atopic Dermatitis

Homeopathic Classification Of Disease – Dynamic,

Chronic, Miasmatic disease with fully developed symptoms.  
Miasm – Tubercular

**Susceptibility:** High susceptibility due to following reasons:

- Symptom similarity
- More characteristic symptoms at the level of mind and physical general
- Young male patient
- Good immune response

**O/E-The patch looked like a spider web below right eye.**

**Examination findings** – General condition fare.

Throat, R.S., C.V.S., G.I.T., C.N.S – No Abnormality detected.

**Investigation – 09/3/22**

IgE Total antibody – 854 IU/mL

**Totality of symptoms – According to Kent**

1. Mischievous child
2. Physical restlessness
3. Likes music
4. Eruptions itchy
5. Eruptions dry

**Kentian approach:** As we see many characteristics in this case at the level of mind then physical generals.

**Repertorial Totality from Hompath App**

1. Mind : Mischievous
2. Mind : Restlessness : nervousness
3. Mind : Excitement : excitable : music from
4. Mind : Destructiveness
5. Mind : Anger, irascibility : Violent
6. Face : Itching
7. Skin : Eruptions : Dry

**Repertorial Totality from Synthesis App:**

1. Mind - Anger - Violent
2. Mind - Colors - Bright - Amel
3. Mind -Destructiveness
4. Mind - Excitement -music,from
5. Mind - Mischievous
6. Mind - Restlessness
7. Face - Eruption-Itching
8. Skin-Eruption-Dry

| Repertorisation  |        |        |        |        |        |       |
|--|--------|--------|--------|--------|--------|-------|
| Symptoms: 7 Remedies: 284 Applied Filter                                     |        |        |        |        |        |       |
| Remedy Name  | Calc   | Tarent | Anac   | Ars    | Verat  | Hyos  |
| <b>Totality / Symptom Covered</b>  | 14 / 6 | 13 / 6 | 12 / 5 | 12 / 5 | 10 / 6 | 9 / 5 |
| [Kent] [Mind]Mischievous: (16)   | 2      | 2      | 3      | 2      | 2      | 2     |
| [Kent] [Mind]Excitement,excitable:Music,from: (3)                            |        | 2      |        |        |        |       |
| [Kent] [Mind]Restlessness,nervousness: (249)                                 | 3      | 3      | 3      | 3      | 1      | 3     |
| [Kent] [Skin]Eruptions:Dry: (61)   | 3      |        | 1      | 3      | 3      | 1     |
| [Kent] [Mind]Destructiveness: (29)   | 1      | 2      |        |        | 2      | 2     |
| [Kent] [Mind]Anger,irascibility (see irritability,quarrelsome):Violent: (35) | 2      | 3      | 3      | 2      | 1      | 1     |

Fig 7: Repertorization sheet from Hompath FireFly app



| MIND                                 |      |      |                  |
|--------------------------------------|------|------|------------------|
| 1 MIND - ANGER - violent             |      |      | ×                |
| 2 MIND - COLORS - bright -<br>amel.  |      |      | ×                |
| 3 MIND - DESTRUCTIVENESS             |      |      | ×                |
| 4 MIND - EXCITEMENT -<br>music, from |      |      | ×                |
| 5 MIND - MISCHIEVOUS                 |      |      | ×                |
| 6 MIND - RESTLESSNESS                |      |      | ×                |
| FACE                                 |      |      |                  |
| 7 FACE - ERUPTIONS - itching         |      |      | ×                |
| SKIN                                 |      |      |                  |
| 8 SKIN - ERUPTIONS - dry             |      |      | ×                |
| Remedies                             | ΣSym | ΣDeg | Symptoms         |
| tarent.                              | 6    | 15   | 1, 2, 3, 4, 5, 6 |
| anac.                                | 6    | 13   | 1, 3, 5, 6, 7,   |

Fig 8: Repertorization sheet from Synthesis App

**Remedy Selection**

1. Tarentula 200 tds X 3 days

2. Followed by SL tds X 5 days

Table 1: Date Follow Ups Prescription

| Date       | Follow Ups                   | Prescription  |
|------------|------------------------------|---|
| 11/07/2022 | 1 <sup>st</sup> prescription | Tarentula 200 tds X 3 days<br>Followed by SL tds X 5 days |
| 18/07/2022 | Better                       | SL 200 t.d.s X 7 days                                     |
| 25/07/2022 | Better IgE – 460.1 (22/7/22) | SL t.d.s X 7 days   |

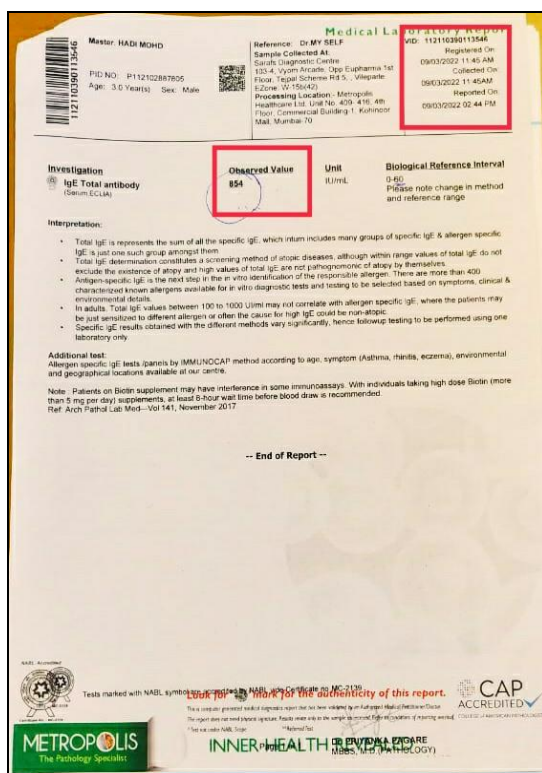


Fig 9: IgE levels (09/03/22)

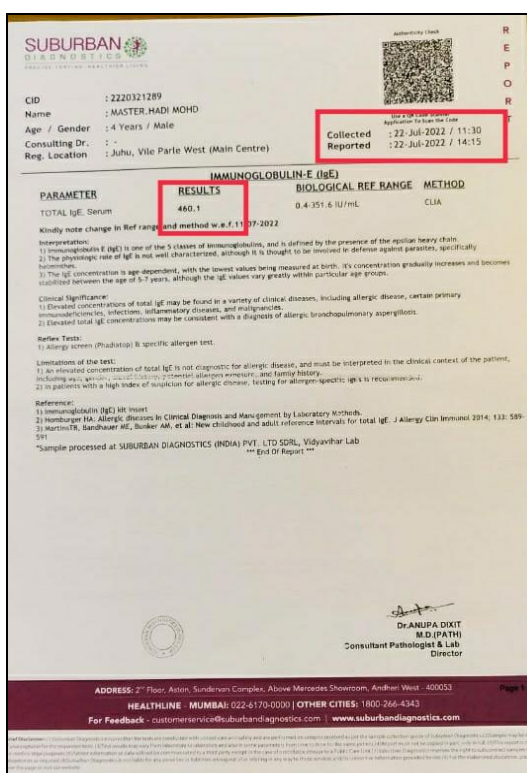


Fig 10: IgE levels (22/7/22)

## References

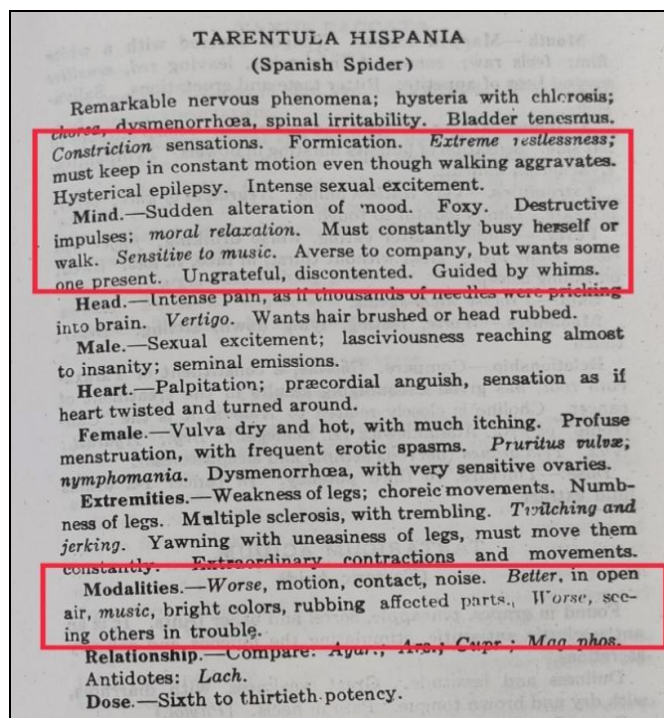
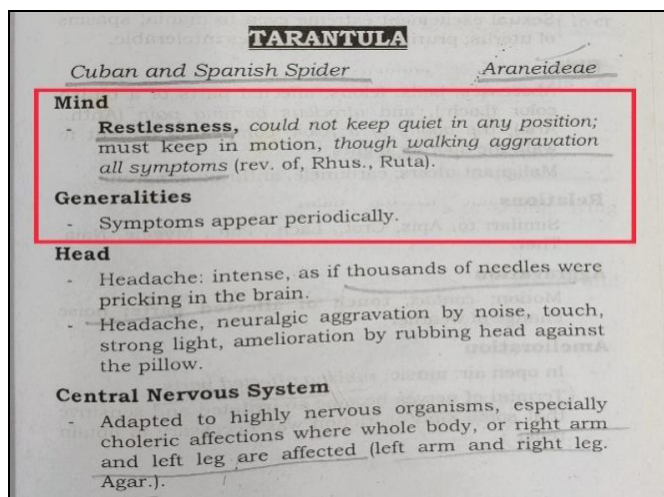
Fig 11: Pocket Manual of Homoeopathic Materia Medica by William Boericke – 9<sup>th</sup> Edition – Tarentula (page no-633)

Fig 12: Keynotes Rearranged &amp; Classified by H.C. Allen – Tarentula (page no. 383)

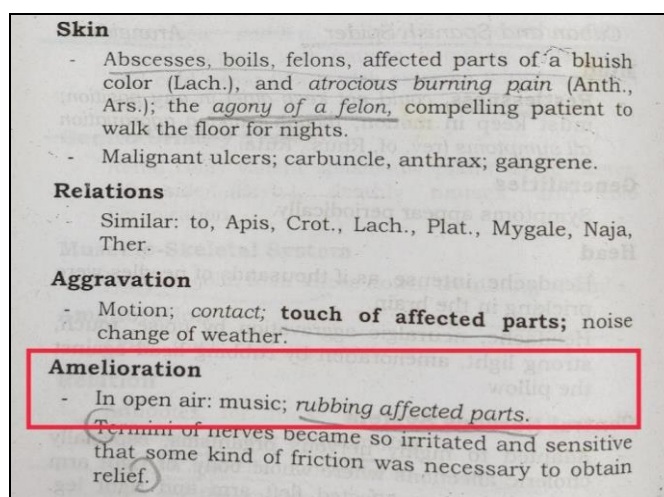
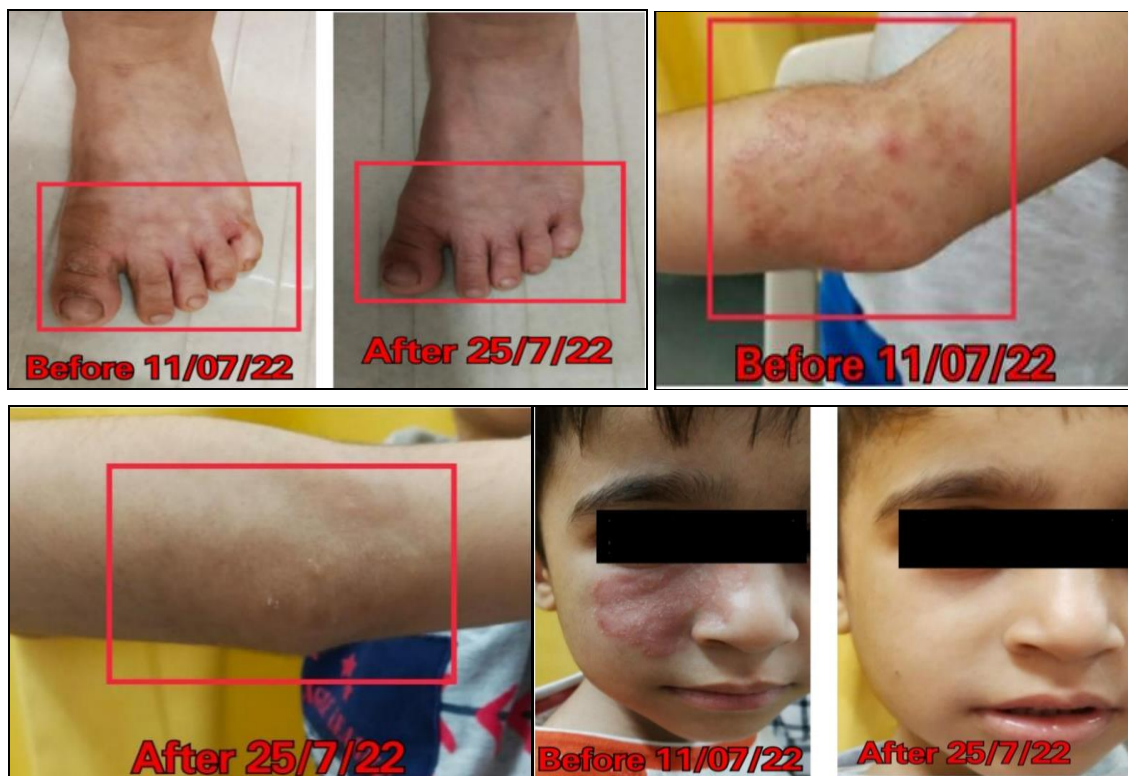

Fig 13: Keynotes Rearranged &amp; Classified by H.C. Allen – Tarentula (page no. 384)



### Acknowledgement

A heartfelt and sincere gratitude to Shri. Mumbadevi Homoeopathic Hospital, Holy Spirit Hospital. We would like to thank Dr. Mohanbhai Patel, Chairman, The Homeopathic Education Society, Vile Parle west, Mumbai. Dr. Asmita Parikh, General Secretary, The Homeopathic Education Society, Vile Parle west, Mumbai.

### Conflict of Interest

Not available

### Financial Support

Not available

### Reference

1. Skin Diseases. Sexually Transmitted Infections by Uday Khopkar-7<sup>th</sup> Edition-Page no 111-CBC Publishers and Distributors-ISBN-978-93-88-108-45
2. Harrison's Principles of Internal Medicine- 19th Edition 2:344. ISBN-978-0-07-18423-7
3. Kumar and Clark's Clinical Medicine by Praveen Kumar and Michael Clark-9th Edition-International Edition-Page no 1349-ISBN-978-0-7020-6599-6
4. Pocket Manual of Homoeopathic Materia Medica by William Boericke, MD. 9TH Edition. Revised & Enlarged with the addition of a Repertory by Oscar E. Boericke AB, M.D-Indian Books & Periodicals Publishers New Delhi- 110 005 India, 633.
5. Keynotes Rearranged & Classified by H.C. Allen, MD- 12th reprint edition. Indian Books & Periodicals Publishers New Delhi-110005 India; c2015. p. 383-384.
6. Roxburgh's Common Skin Diseases by Ronald Marks- 17th Edition-International Students Edition-Page no 105. Arnold Publishers-ISBN-0-340-76233-0
7. Davidson's Principles and Practice of Medicine – 23rd Edition – International edition – Page no 1245. Elsevier Publication -ISBN-978-0-7020-7027-3
8. Lectures on Homoeopathic Materia Medica by J.T.

Kent, Page no 990- B. Jain Publisher Pvt Ltd, New Delhi, 2002, 12th Impression: c2014, p. 467-473.

9. Materia Medica of Homeopathic Medicines by dr. S.R. Phatak, M.B.B.S- Second edition Revised and enlarged- B. Jain Publishers (P) Ltd; 646-648.
10. Allen TF. Encyclopedia of Pure Materia Medica, B Jain Regular; c1981. p. c411-419.
11. Repertorization Software App-Homopath Firefly Application.
12. Organon of Medicine by Samuel Hahnemann-6th Edition- Translated with preface by William Boericke, M.D -Indian Books and Periodicals Publishers; 93:204.
13. Repertory of Homoeopathic Materia Medica by Dr. J.T. Kent - Enriched Indian Edition Reprinted from 6th American edition Page no 66. B Jain Publishers (P) Ltd.- ISBN 978-81-319-0094-9
14. Boericke's New Manual of Homeopathic Materia Medica with Repertory by William Boericke- Third Revised and Augmented Edition based on Ninth Edition- Page no 881- B Jain Publishers (P) Ltd.
15. A Concise Repertory of Homoeopathic Medicines y Dr. S. R. Phatak - Fourth edition Revised and Corrected- Page no 273 - B Jain Publishers (P) Ltd.
16. Repertorization Software App - Synthesis Application.

### How to Cite This Article

Damania P, Sayed G, Hulaman A, Haldankar C, Baig S, Pamecha K. Significance of constitutional in atopic dermatitis. National Journal of Clinical Orthopaedics. 2022;6(4):215-220.  
DOI: <https://doi.org/10.33545/26164485.2022.v6.i4d.661>

### Creative Commons (CC) License

This is an open access journal, and articles are distributed under the terms of the Creative Commons Attribution-NonCommercial-ShareAlike 4.0 International (CC BY-NC-SA 4.0) License, which allows others to remix, tweak, and build upon the work non-commercially, as long as appropriate credit is given and the new creations are licensed under the identical terms.