



International Journal of Homoeopathic Sciences

E-ISSN: 2616-4493
P-ISSN: 2616-4485
www.homoeopathicjournal.com
IJHS 2022; 6(4): 389-391
Received: 19-08-2022
Accepted: 23-09-2022

Dr. Tummala Aarathi Reddy
Assistant Professor,
Department of Obstetrics &
Gynaecology, MNR
Homoeopathic Medical
College, Sangareddy,
Telangana, India

Dr. Sreevidhya JS
Associate Professor,
Department of Obstetrics &
Gynaecology, MNR
Homoeopathic Medical
College, Sangareddy,
Telangana, India

Dr. E Siva Rami Reddy
Professor and Head,
Department of Practice of
Medicine, MNR Homoeopathic
Medical College, Sangareddy,
Telangana, India

Corresponding Author:
Dr. Tummala Aarathi Reddy
Assistant Professor,
Department of Obstetrics &
Gynaecology, MNR
Homoeopathic Medical
College, Sangareddy,
Telangana, India

The enchantress of white cider in treating warts: A case report

Dr. Tummala Aarathi Reddy, Dr. Sreevidhya JS and Dr. E Siva Rami Reddy

DOI: <https://doi.org/10.33545/26164485.2022.v6.i4f.689>

Abstract

Warts are rough non-cancerous bumps that appear on the skin caused by Human papilloma virus. Painless fleshy growth over the skin. A 29 years old lady presented with warts over the upper lip and was treated with Thuja 200, according to symptom similarity with follow up of 3 months. This case report proves that homoeopathic medicine prescribed based on symptom similarity will explore with wonderful results and can even prevent the recurrence.

Keywords: Warts, recurrence, homoeopathy, Thuja

Introduction

Warts are benign lesions usually caused by Human papilloma virus. There are various types of warts. Common, flat, plantar, filiform, Mosaic, genital, periungual. Most of the warts doesn't cause any problem but they cause cosmetic problem. Recurrence of warts is quite common. warts may be transmitted by direct contact or indirect contact. Transformation of simple warts into malignant conditions is due to immunocompromisisation. This particular case is of common warts which are on the sides of upper lips^[1-10].

Case Report

A 29years old lady had reported to the clinic on 3rd November 2021 with the complaints of warts over the upper lips. Lady was having only concern regarding the cosmetic issue. There are no other complaints.

History of presenting complaint

Complaints started since 1year. Warts over the upperlip. She is working lady. Married to loved ones going against to parents for which she is forced to stay away from parents. She is leading her happy married life, but feels bad while thinking regarding her parents. Both the couples work hard and trying to cope up with situation as they are in demand of money. She is very emotional, trembling and weeping while telling the complaints. She likes to eat cold food, but these days developed decreased appetite. She is having Menses in regular manner but scanty flow with too much of perspiration prior to menses. Dyspareunia, vagina sensitive to coital act.

Generals

Appetite: Decreased
Urine: Normal
Thirst: Normal
Stool: loose motions after break fast
Sleep: Disturbed
Sweat: Increased before menses
Mental generals:

Emotional

Trembling and weeping while narrating the complaints
Broods things regarding past

Evaluation of symptoms

- Emotional sensitive
- Weeping while listening to music
- Warts over upper lip on Rt side of face
- Desires cold food
- Increased Perspiration before menses
- Sensitiveness in vagina

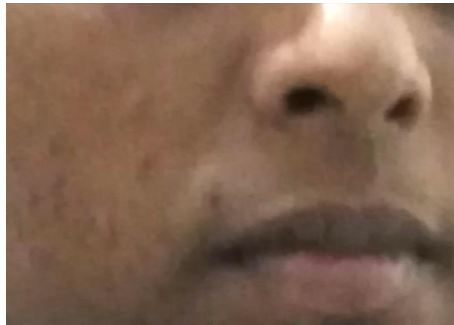

Fig 1: 3rd November 2021

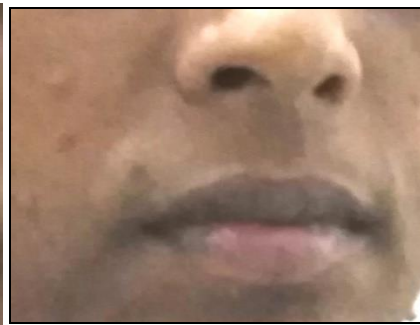


Fig 2: 18th November 2021

Remedy Name	Thuj	Staph	Lyc	Caust	Sep
Totality / Symptom Covered	10 / 5	8 / 4	7 / 4	7 / 3	7 / 3
[Kent] [Mind]Sensitive,oversensitive (see offended):Music,to: (27)	1		2	1	3
[Kent] [Stomach]Desires:Cold :Food: (14)	2		2		
[Kent] [Genitalia female]Sensitive:Vagina: (23)	2	3			2
[Kent] [Skin]Warts (see excrescences): (65)	3	1	1	3	2

Fig 3: Repertorisation chart

Therapeutic Intervention

Case taking had done and repertorisation was done by following Kentian method of Repertorisation, Thuja 200 was selected based on the grounds of Miasmatic

consideration Sycotic miasm was predominant, while we know Thuja is an antisycotic remedy. The patient was asked to report after 15days.

Table 1: Data of symptoms, follow up, Prescription

Date	Symptoms	Prescription/Dose	Justification
3 rd November 2021 1 st visit	Warts over the upper lip(Rt)	Thuja 200/ 1 dose	-----
18 th November 2021 2 nd visit	Size slightly decreased	Sac Lac/1 dose	Improving
3 rd December 2021 3 rd visit	Wart resolved completely	Sac Lac/1 dose/1 month	Improved
4 th January 2022 4 th visit	No recurrence	Sac Lac/1 dose	No recurrence Asked her only to turn back when its needed

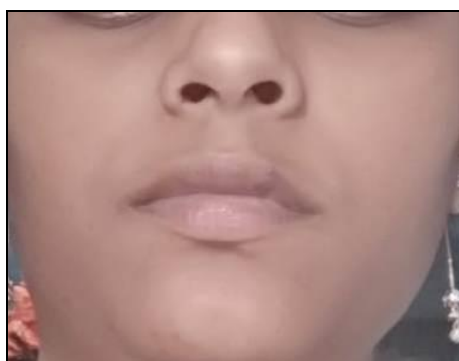


Fig 4: 3rd December 2021

and had no recurrence. Thus proved homoeopathy not only treat the symptoms the cause from the root is removed.

Acknowledgement

Not available

Author’s Contribution

Not available

Conflict of Interest

Not available

Financial Support

Not available

Conclusion

This is a case of Warts. By the symptom similarity, Individualisation &Repertorisation Thuja was selected. With single dose of 200 potency Pt had resolved with warts

References

1. William Boericke, New Manual of Homoeopathic Materia Medica &Repertory, Augmented Edition.

- Indian books & periodicals publishers New Delhi; c2015
2. Allen HC. Keynotes Rearranged & Classified with leading remedies of Materia medica added with other leading nosodes & bowel nosodes 10th edition Indian books & Periodicals publishers.
 3. Kent JT. Repertory of the Homoeopathic Materia Medica 6th American edition Indian books and Periodical publishers.
 4. Reddy SR. Effect of homoeopathic medicine Lycopodium clavatum in urinary calculi. International Journal of Applied Research. 2017;3(1):790-1.
 5. Sterling JC, Handfield-Jones S, Hudson PM. British Association of Dermatologists. Guidelines for the management of cutaneous warts. Br J Dermatol c2001;
 6. Hahnemann S, Boericke W, Krauss J. Organon of Medicine. 6th ed. New Delhi: B. Jain Publishers (Pvt.) Ltd; c2003.
 7. Brian R Walker, Nicki R Colledge, Stuart H Ralston, Ian D Penman. Davidson's Principles & Practice of Medicine. 22nd Edition, Churchill Livingstone Elsevier, China; c2014.
 8. Dr. Farokh J Master. Skin Homoeopathic approach to Dermatology, Second revised edition. B. Jain Publishers (P) LTD, USA, 2006, 500-509.
 9. Tanuja BM. Text Book of Medicine.
 10. Ramji Gupta RK Manchanda. Textbook of Dermatology for homoeopaths, Forth edition B. Jain Publishers (P) ltd, usa; c2011.

How to Cite This Article

Dr. Tummala Aarathi Reddy, Dr. Sreevidhya JS, Dr. E Siva Rami Reddy. The enchantress of white cider in treating warts: A case report. International Journal of Homoeopathic Sciences. 2022;6(4):389-391.

Creative Commons (CC) License

This is an open access journal, and articles are distributed under the terms of the Creative Commons Attribution-NonCommercial-ShareAlike 4.0 International (CC BY-NC-SA 4.0) License, which allows others to remix, tweak, and build upon the work non-commercially, as long as appropriate credit is given and the new creations are licensed under the identical terms.