



International Journal of Homoeopathic Sciences

E-ISSN: 2616-4493
P-ISSN: 2616-4485
www.homoeopathicjournal.com
IJHS 2022; 6(4): 503-509
Received: 25-07-2022
Accepted: 28-09-2022

Dr. Tanmay Sarkar
Lecturer, Department of
Homoeopathic Pharmacy,
Metropolitan Homoeopathic
Medical College and Hospital,
Ramchandrapur, Sodepur,
Kolkata, West Bengal, India

Dr. Abhinandan Das
Lecturer, Department of
Physiology and Biochemistry,
Bengal Homoeopathic Medical
College and Hospital,
MXC8+7G2, Ismile, Shatabdi
Nagar, Asansol, West Bengal,
India

Corresponding Author:
Dr. Tanmay Sarkar
Lecturer, Department of
Homoeopathic Pharmacy,
Metropolitan Homoeopathic
Medical College and Hospital,
Ramchandrapur, Sodepur,
Kolkata, West Bengal, India

Atopic dermatitis successfully treatment by constitutional homoeopathic medicine graphites: A case report

Dr. Tanmay Sarkar and Dr. Abhinandan Das

DOI: <https://doi.org/10.33545/26164485.2022.v6.i4h.703>

Abstract

Atopic dermatitis (AD) is a commonly recurring inflammatory eczematous condition of the skin which affects up to 2.4% of the global population and among them, 15-20% of children and 1-3% of adults are affected globally. A 48 years old female patient diagnosed with AD, suffering from complaints of pruritic eczematous lesions with sticky pus collection on both arm and abdominal region for the last 36 months. The patient was treated with modern medicine for a long time but there was no permanent relief. Therefore, the patient sought out homoeopathic treatment for a long-lasting cure. A constitutional medicine Graphites 0/1 was prescribed based on the totality of symptoms. All problems showed better, but after a while, they all came to a standstill. As per homoeopathic principles, this led to an increasing the potency of Graphites 0/2. Following four months of treatment, there was a considerable improvement in the eczematous lesions and all accompanying complaints, as well as a noticeable improvement in the SCORAD Index. This case shows that AD is cured by constitutional homoeopathic treatment.

Keywords: Atopic dermatitis, homoeopathy, Graphites, constitutional treatment, SCORAD index

Introduction

Atopic dermatitis is a prevalent, chronic, recurrent, inflammatory skin condition. "derma" and "itis" is Greek term it translates to "skin" and "inflammation," respectively^[1, 2]. AD is more frequent in developed countries than in agriculture-based countries^[2]. The term "atopy" refers to the genetic propensity to create immunoglobulin E (IgE) antibodies in reaction to very small amounts of common environmental proteins such as pollen, house dust mites, livestock, and food allergies^[3]. Atopic eczema is a major public health problem worldwide, affecting around 5% to 20% of children ages 6 to 7 and 13 to 14 years^[4]. International asthma and allergies in childhood (ISSAC) say that the manifestation of AD is 10% to 20% in children and 1% to 3% in adults globally^[5]. On the cheeks, flexor surfaces of the arms, chest, and forehead, in particular, the condition is characterised by the development of dry, scaly patches of skin. Patients who frequently exhibit severe pruritis, xerosis, erosions, excoriations, and ill-defined areas of erythema throughout acute flares might be diagnosed with AD^[5, 6]. The distribution of these symptoms varies with age^[6]. In some cases, the pathogenesis of AD begins with a genetically predetermined skin barrier defect that manifests as dry skin. This innate skin barrier deficit results in the overexpression of pro-inflammatory cytokines released, which leads to the activation of innate lymphocyte subsets and antigen-presenting cells. Sometimes few cytokines are involved in the itch sensation^[7, 8]. Not only patients are affected by the social shame of an obvious skin condition, but the characteristic of extreme itching of the disease usually results in skin injury and significant rest disturbances^[9]. AD disturbed the health-related quality of life (HRQoL) of children and their families. Sleeplessness is caused by itching and pain in more than 60% of people. Lose of Sleep leads to weariness, mood swings, and impaired psychosocial functioning of school-going children and family members^[10, 11, 12]. Overall physical, psychological, and psycho-social life was hampered by AD^[11]. Homoeopathy is based on 'like cures like. Clinical research and meta-analysis proved that homoeopathy has its own actions^[13]. Homoeopathy is a unique and classical therapeutics of science^[14]. Positive effects of Homoeopathy suffering from AD and asthma in children and adult age^[15].

Case report

A 48 year's old Hindu female patient visited the OPD of Dr. Tanmay Sarkar on 06/06/2022 and presented with complaints of eczematous skin diseases in various parts of the body but especially in the arm along with severe itching, after scratching thick sticky discharge collection, mild lichenification, dryness, cracked of skin from last 3 years (Figure1). Itching aggravated in the evening & at night and amelioration from wrapping up. Tenderness with pain in both knee joints legs especially in open air & change weather, Sensitive to cold. The patient was anxious, melancholic, and depressed, forget her words when she speaks or interact with others and forgetful & confused. She has a weeping disposition and wants to be crying alone. Before coming to my O.P.D she was treated with modern medicine (anti- fungal and steroidal ointment) for 3 years by a dermatologist for Atopic Eczema (Dermatitis), at that time she complained was little ameliorated for 1 month and after that, eczema became more violent than earlier. She changed dermatologists every time when her complaints aggravated but each time complaint not cure. Under these circumstances, she was going to decide to take homoeopathic treatment.

There was a past history of skin irruption, and dust allergy treated with modern medication, Chickenpox was affected in childhood. She had no addiction and was not on any ongoing allopathic medicine. In the family history, father and paternal grandfather had hypertension and skin disease. Mother had osteoarthritis with uric acid.

The patient had short stature, dark complexion, and rough skin. Her facial expression was always anxious & a panic mood for her suffering complaint.

On examination of the skin, there were reddish-brown patches with crusty scab formation after thick exudation, dry, cracked, itching and mild lichenification over both arms. Other systemic examinations like respiratory, CVA, and Abdomen were normal but extremities gaits & movement were changed.

Homoeopathic Generalities

Mental Generals: - Patient complains were Indiscretion++, forgetfulness++, irritability++, anxiety++ and tensive++, confusion of mind+++, depression++ (sad, melancholic), weeping disposition <alone+++, desire to company++, Hesitating++, Restlessness in working++.

Physical Generals: - The physical generalities were appetite good, bitter taste, hot things disagree, Stomach heavy & ameliorated by lying+, Stool difficult to pass (hard, stringy, tough), thermal reaction chilly++, desire salty things + and curd+, aversion in sweets+++, milk+++, aversion to bathing & open air+, especially in winter+++, Great thirst in the morning & after meal ++, Urine-Involuntary emission of urine ++, perspiration- head but offensive++,

sleep- disturbed/ un-refreshing+++, Dreams- death & fire ++. Her menstrual cycle was stopped at 43 years of age & she has 2 children.

Analysis of the case and repertorization: - A detailed analysis and evaluation of the characteristics and symptoms were converted to totality & further converted to the rubrics.

Totality of Symptoms & Rubrics

Indiscretion++
 forgetfulness++
 confusion of mind++
 depression++ (sad, melancholic)
 weeping disposition <alone++
 desire to company++
 Hesitating++
 Restlessness in working++
 Thermal reaction chilly++,
 Desire salty things + and curd++
 Aversion in sweets++
 sleep- disturbed/ un-refreshing++
 Dreams- death & fire ++
 Involuntary emission of urine ++
 Stomach heavy & ameliorated by lying+
 Stool difficult to pass (hard, stringy, tough)
 Eruption: Discharging, scratching after
 Eruption: Discharging: Moist
 Eruption: Discharging glutinous++
 Skin: Cracks painful
 Excoriated: denuded, raw
 Skin: dry/ dryness
 Itching aggravated in the evening & at night and amelioration from wrapping up

Clinical diagnosis: Atopic Dermatitis (Hanifin and Rajka-developed criteria for diagnosis in 1980)

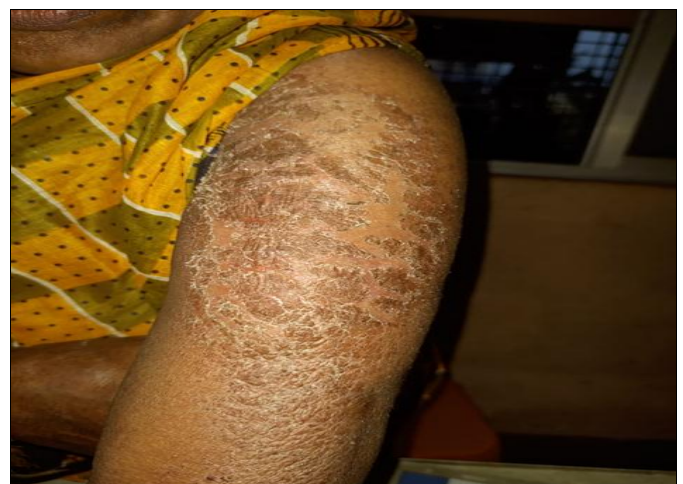

Fig 1: Before Homoeopathic Treatment

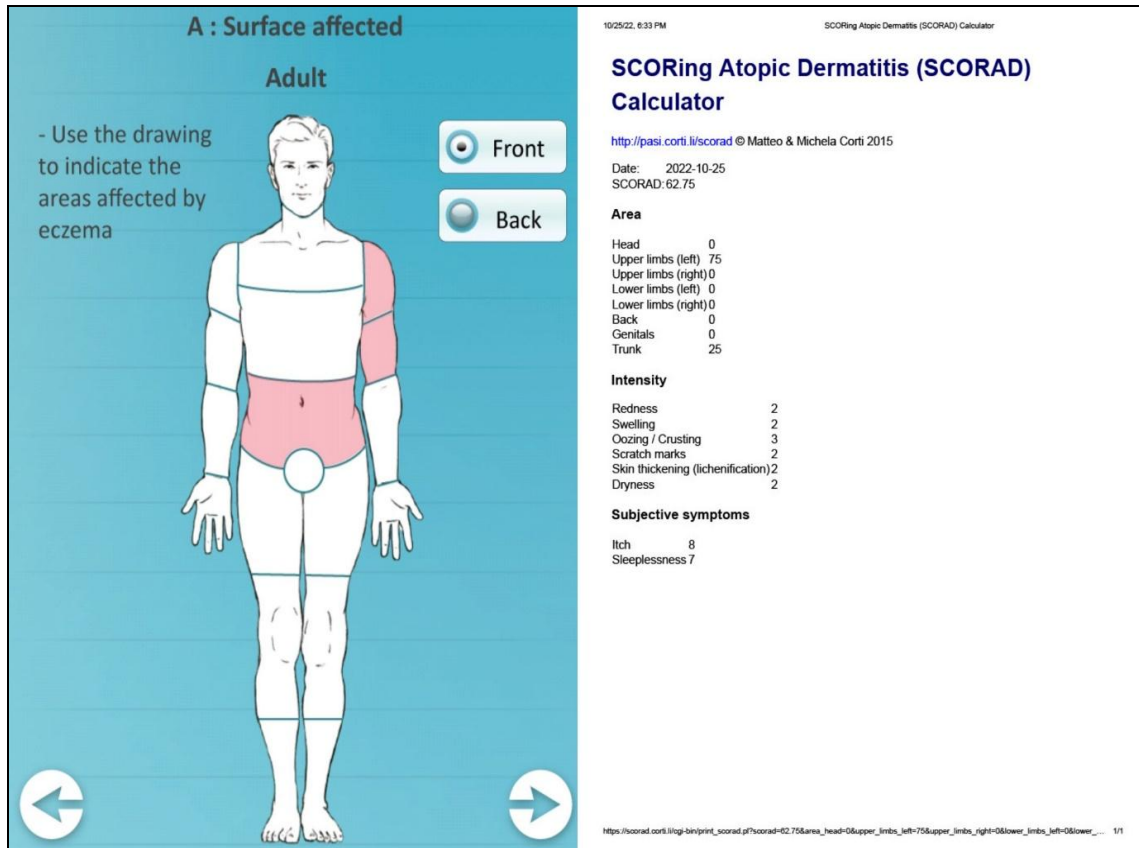


Fig 2: SCORAD Index before Homoeopathic Treatment

Table 1: Repertorial analysis of the characteristic Symptoms

Remedy Name	Sulph	Graph	Nat-m	Lyc	Phos	Arsc	Calc	Carb-v	Merc	Sep	Lac h	Barr-c
Totality	45	43	40	38	37	36	34	33	31	31	31	30
Symptoms Covered	20	18	19	15	15	17	16	17	17	14	13	17
Kingdom												
[Kent] [Mind]Indiscretion:			1									
[Kent] [Mind]Forgetful (see memory):	2	2	2	3	3	1	2	2	3	1	2	3
[Kent] [Mind]Confusion of mind (see concentration):	2	2	3	2	2	2	3	3	3	3	3	2
[Kent] [Mind]Sadness,mental depression:	3	3	3	3	2	3	3	2	3	3	3	2
[Kent] [Mind]Weeping,tearful mood,etc.:Alone,when:			2									
[Kent] [Mind]Company:Desire for:				3	3	3	2	1	1	2		
[Kent] [Mind]Restlessness,nervousness:Working,while:		3										
[Kent] [Generalities]Heat:Vital,lack of:	2	3	2	2	3	3	3	2	2	2	2	3
[Kent] [Stomach]Desires:Salt things:	1		3		3		2	3				
[Kent] [Stomach]Aversion:Sweets:	2	3			2	2			2			1
[Kent] [Sleep]Disturbed:	3	3	1			2			1	1		1
[Kent] [Sleep]Unrefreshing:	2	1	2	2	3	2	1	1		2	3	2
[Kent] [Sleep]Dreams:Death:Of:	2		1	1		1	2				3	
[Kent] [Sleep]Dreams:Fire:	2	1	2		2	2	1	1	1			1
[Kent] [Bladder]Urination:Involuntary:	2	1	3	3	3	3	1	2	2	3	2	2
[Kent] [Stomach]Heaviness,weight,oppression (see fullness):	3		2	3	2	2		2	1	1	1	2
[Kent] [Stool]Hard:	3	3	3	3	3	2	3	2	2	3	3	2
[Kent] [Stool]Stringy:								2				

[Kent] [Stool]Tough:	3												1
[Kent] [Skin]Eruptions:Discharging:Scratching,after:	1	3	1	3		1	1	2	1	2	3		1
[Kent] [Skin]Eruptions:Discharging:Moist:	2	3	3	3	2	2	2	3	2	3	2		2
[Kent] [Skin]Eruptions:Discharging:Glutinous:	1	3	2				2						
[Kent] [Skin]Cracks:Painful:		2											
[Kent] [Skin]Excoriation (see intertrigo):	3	3	2	3	1	2	3	2	2	3			3
[Kent] [Skin]Dry:	3	2	2	3	3	3	3	2	2	2	2		1
[Kent] [Skin]Itching:Evening:				1				1	2				
[Kent] [Skin]Itching:Night:	3	2							1		2		1

Bases of Selection Individualized Homoeopathic Medicine (IHM): - Graphites is chosen based on the Totality of Symptoms. Repertorial analysis done by J.T.

Kent & Symptoms Cross checked by Clark materia medica [16, 17, 18, 19]. We selected Graphites as a constitutional remedy.

Table 2: Patient Follow-up

Date	Symptoms	Remedy
06/06/2022	Baseline presentation [Figure 1] severe itching (Pruritus), serous exudates like thick honey fluid, lichenification, dryness, and cracked skin. Itching aggravated in the evening & at night, complaints amelioration from wrapping up.	Graphites 0/1 OD* 16 doses
24/06/2022	Eczema - discharges less, itching persists & Involuntary emission of urine complaints ameliorated	Graphites 0/2 OD* 16 doses
11/07/2022	No new symptoms arise, Skin and mental symptoms were ameliorated.	Graphites 0/3 OD* 16 doses
30/07/2022	No itching, no discharges.	Graphites 0/4 OD* 16 doses
18/08/2022	No itching, no discharges.	Placebo-30 4 globs* TDS* 15 days
05/09/2022	No itching, no discharges.	Placebo-30 4 globs* TDS* 15 days

Table 3: Assessment by Modified Naranjo Criteria Score [20, 21, 22, 23]

S.N.	Item/Question	Yes	No	Not sure or N/A
01	Was there an improvement in the main symptom or condition for which the homoeopathic medicine was prescribed?	+2	0	0
02	Did the clinical improvement occur within a plausible time frame relative to the drug intake?	+1	-2	0
03	Was there an initial aggravation of the symptom? (need to define in a glossary)	+1	0	0
04	Did the effect encompass more than the main symptom or condition, i.e., were other symptoms ultimately improved or changed?	+1	0	0
05	Did overall well-being improve? (suggest using a validated scale)	+1	0	0
06 (a)	The direction of cure: did some symptoms improve in the opposite order of the development of symptoms of the disease?	+1	0	0
06 (b)	The direction of cure: did at least two of the following aspects apply to the order of improvement of symptoms -from organs of more importance to those of less importance - from deeper to more superficial aspects of the individual - from the top downwards.	+1	0	0
07	Did old symptoms” (defined as non-seasonal and non-cyclical that were previously thought to have resolved) reappear temporarily during the course of improvement?	+1	0	0
08	Are there alternate causes (other than the medicine) that-with a high probability- could have caused the improvement? (consider the known course of the disease, other forms of treatment and other clinically relevant intervention)	-2	+1	0
09	Was the health improvement confirmed by any objective evidence? (e.g. lab test, clinical observation, etc.)	+1	0	0
10	Did repeat dosing, if conducted, create similar clinical improvement?	+2	0	0
Total score =Maximum score=13 Minimum score=02				Score=09

The interpretation of the total Naranjo Score predicting drug action is as follows: Total scores range from -4 to +13; the reaction is considered definite if the score is 9 or higher,

probable if 5 to 8, and possible if 1 to 4, and doubtful if 0 or less [20, 21, 22, 23].

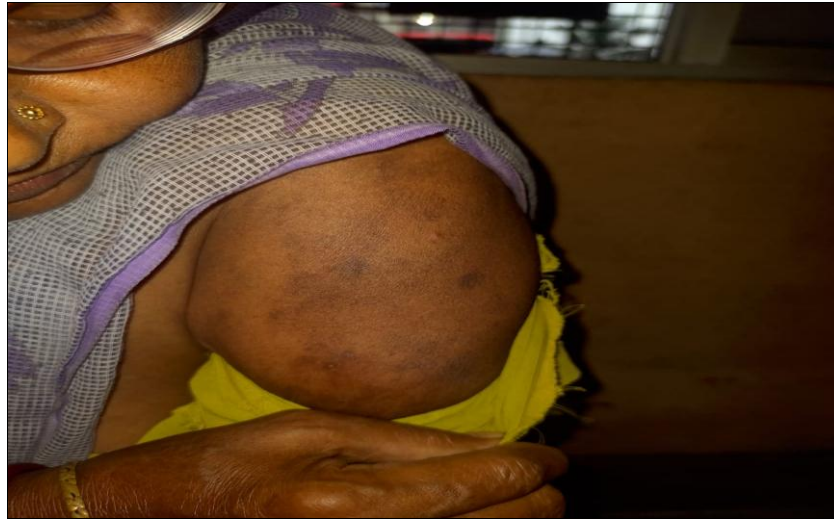

Fig 3: After Homoeopathic Treatment

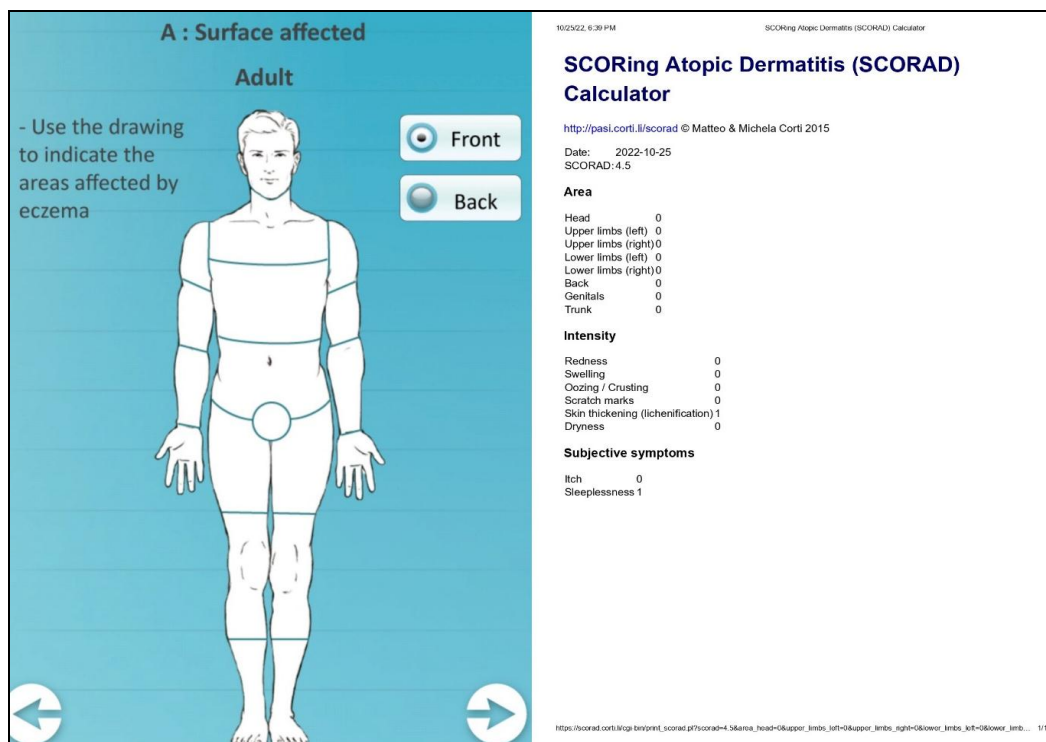


Fig 4: SCORAD Index after Homoeopathic Treatment

Discussion

Homoeopathy is the world’s 2nd largest system of treatment & it treats the patient not the disease [24, 25, 26]. If we selected a proper individualised Homoeopathic Medicine (IHM) for the treatment then it works not only symptomatically but also works holistically. In this case report, there was also a selected IHM that was *Graphitis 0/1* & it’s also followed constitutionally. After the prescription, no new symptoms came & patient had 50% relief on the 3rd follow-up. In the 5th & 6th follow-ups mentioned the complaints were gone. The Case report Figures 01 & 03 was a clear picture that *Graphites* work beautifully & SCORAD index was before 62.75 & after treatment 4.5. Assessment by Modified Naranjo Criteria Score (Table 3) 09 out of 13, which means IHM works tremendously well [22, 26].

Conclusion

Homoeopathy is a remarkable alternative system of

medicine in the modern era (13, 26). Homoeopathic medicines are effective in the treatment of AD, which has been proven once again under this case report. If we selected remedies on the bases of the totality of characteristic symptoms and through individualization which covers the patient’s miasmatic background. These types of remedy selection procedures can cure the patient at a deeper level & patient relief permanent. If we choose symptomatic treatment, a mixture of various medicines or use any suppressive external application, which affects badly to the patient. Individualized Homoeopathic Medicine (IHM) is also capable to cure the mental symptoms of the comorbidity AD patient. *Graphites* proved that it can cure the characteristic symptoms of AD, along with mental symptoms. Meanwhile good homoeopathic case-taking & prescription is important for every acute & chronic case. Further research study needed on this topic for the betterment of Homoeopathy.

Acknowledgement: The author wishes special thanks to Dr. Joydev Sarkar and Dr. Prof. Asok Kumar Das.

Conflict of Interest: None

Source of Funding: None

Author's Contribution: Not available

Declaration of patient consent

The authors attest to having obtained the required patient consent form. The patient has granted her permission in the form for her photos and other clinical data to be published in the publication. The patient is aware that her name and initials won't be published, and that appropriate measures will be taken to keep her identity a secret.

Reference

1. Thomsen SF. Atopic dermatitis: natural history, diagnosis, and treatment. *International Scholarly Research Notices*; c2014.
2. Odhiambo JA, Williams HC, Clayton TO, Robertson CF, Asher MI. ISAAC Phase Three Study Group. Global variations in prevalence of eczema symptoms in children from ISAAC Phase Three. *Journal of Allergy and Clinical Immunology*. 2009 Dec 1;124(6):1251-8.
3. Spergel JM. From atopic dermatitis to asthma: the atopic march. *Annals of allergy, asthma & immunology*. 2010 Aug 1;105(2):99-106.
4. Williams H, Robertson C, Stewart A, Ait-Khaled N, Anabwani G, Anderson R, *et al.* Worldwide variations in the prevalence of symptoms of atopic eczema in the International Study of Asthma and Allergies in Childhood. *Journal of allergy and clinical immunology*. 1999 Jan 1;103(1):125-38.
5. Lee C, Lee S, Kim SW, Sung M. Clinical significance of atopic dermatitis with hypoalbuminemia in Korean children. *Iranian Journal of Pediatrics*. 2017 Apr 30, 27(2).
6. Bagdi N, Ram H. A case report for successful treatment of atopic dermatitis (AD) with a Constitutional homoeopathic medicine Natrum muriaticum. *Int. J Homoeopath Sci*. 2020;4(02):46-51.
7. Stefanovic N, Flohr C, Irvine AD. The exposome in atopic dermatitis. *Allergy*. 2020 Jan;75(1):63-74.
8. Silvestre, Marilene Chaves, Reis, Vitor Manoel Silva. Dos Evaluation of the profile of inflammatory cytokines, through immunohistochemistry, in the skin of patients with allergic contact dermatitis to nickel in the acute and chronic phases* * Work conducted at Faculdade de Medicina, Universidade de São Paulo, São Paulo (SP); and Hospital das Clínicas, Universidade Federal de Goiás, Goiás (GO), Brazil. *Anais Brasileiros de Dermatologia [online]*. 2018;93(6):829-835. [Accessed 25 October 2022]. Available from: <<https://doi.org/10.1590/abd1806-4841.20187126>>. ISSN 1806-4841. <https://doi.org/10.1590/abd1806-4841.20187126>.
9. Jamadade AK, Adi BS. Atopic Dermatitis With Homoeopathic Medicine Graphites: A Case Report. *International Journal of Alternative and Complementary Medicine*. 2020 Jun 30, 21-5.
10. Lewis- Jones S. Quality of life and childhood atopic dermatitis: the misery of living with childhood eczema. *International journal of clinical practice*. 2006 Aug;60(8):984-92.
11. Sach TH, McManus E, Levell NJ. Understanding economic evidence for the prevention and treatment of atopic eczema. *Br J Dermatol*. 2019 Oct;181(4):707-716. Doi: 10.1111/bjd.17696. Epub 2019 Apr 11. PMID: 30693473; PMCID: PMC6790711.
12. Fisher P. What is homeopathy? An introduction. *Frontiers in Bioscience-Elite*. 2012 Jan 1;4(5):1669-82.
13. Sarkar T, Anand PK, Jadhav AB, Kunchiraman BN, Shinde CH, Dhankawadi P. Anti-bacterial activity of homoeopathic medicine Sulphanilamide against *Staphylococcus epidermidis in-vitro*. *International Journal of Health Sciences & Research*. 2019;9(12):44-8.
14. Rossi E, Bartoli P, Bianchi A, Da Frè M. Homeopathy in paediatric atopic diseases: Long-term results in children with atopic dermatitis. *Homeopathy*. 2012 Jan;101(01):13-20.
15. Roll S, Reinhold T, Pach D, Brinkhaus B, Icke K, Staab D, Jäckel T, *et al.* Comparative effectiveness of homoeopathic vs. conventional therapy in usual care of atopic eczema in children: long-term medical and economic outcomes. *PLoS One*. 2013;8(1):e54973. doi: 10.1371/journal.pone.0054973. Epub 2013 Jan 31. PMID: 23383019; PMCID: PMC3561412.
16. Allen JH. The chronic miasmas with repertory. Rearranged and augmented ed. New Delhi: B. Jain Publishers (P) Ltd, 2007, 196-199.
17. Roberts HA. The Principles and Art of Cure by Homoeopathy. 12th impression. New Delhi: B. Jain Publishers (P) Ltd; c2012. p. 204-231.
18. Homoeopathic Comparative Materia Medica By N. C. Ghosh
19. A Dictionary of Practical Materia MEDICA By John Henry CLARKE, M.D.
20. Dr. Gurpreet Kaur Gill, Dr. Suruchi Sharda. Atopic dermatitis: The lesser indicated homoeopathic medicines. *Int. J Hom Sci*. 2021;5(4):255-258. DOI: 10.33545/26164485.2021.v5.i4d.482
21. Dr. Priyanka Nagar. Stress does hurt skin: Stress and atopic dermatitis. *International Journal of Homoeopathic Sciences*. 2020;4(3):95-97. E-ISSN: 2616-4493, P-ISSN: 2616-4485
22. Mahesh S, Mallappa M, Habchi O, Konstanta V, Chise C, Sykiotou P, *et al.* Appearance of Acute Inflammatory State Indicates Improvement in Atopic Dermatitis Cases Under Classical Homeopathic Treatment: A Case Series. *Clinical Medicine Insights: Case Reports*. 2021 Feb;14:1179547621994103.
23. Saima Shamim, Amulya Ratna Sahoo, Umakanta Prusty, Chintamani Nayak. Role of Homoeopathy in Infectious Eczematous Dermatitis: A Case Report. *Int. J Hom Sci*. 2022;6(3):12-16. DOI: 10.33545/26164485.2022.v6.i3a.591
24. https://www.ijhsr.org/IJHSR_Vol.12_Issue.9_Sep2022/IJHSR-Abstract26.html
25. Nwabudike, Lawrence Chukwudi. Atopic Dermatitis and Homeopathy. *Our Dermatology Online*. 2012;3:217-220. 10.7241/ourd.20123.50.
26. Mahesh S, Mallappa M, Habchi O, Konstanta V, Chise C, Sykiotou P, *et al.* Appearance of Acute Inflammatory State Indicates Improvement in Atopic Dermatitis Cases Under Classical Homeopathic Treatment: A Case Series. *Clin Med Insights Case Rep*. 2021 Feb 11;14:1179547621994103. doi:

10.1177/1179547621994103. PMID: 33628071;
PMCID: PMC7882755.

How to Cite This Article

S Tanmay, D Abhinandan. Atopic dermatitis successfully treatment by constitutional homoeopathic medicine Graphites: A case report. International Journal of Homoeopathic Sciences. 2022;6(4):503-509.

Creative Commons (CC) License

This is an open access journal, and articles are distributed under the terms of the Creative Commons Attribution-Non Commercial-Share Alike 4.0 International (CC BY-NC-SA 4.0) License, which allows others to remix, tweak, and build upon the work non-commercially, as long as appropriate credit is given and the new creations are licensed under the identical terms.