



International Journal of Homoeopathic Sciences

E-ISSN: 2616-4493

P-ISSN: 2616-4485

www.homoeopathicjournal.com

IJHS 2022; 6(4): 573-579

Received: 01-08-2022

Accepted: 03-09-2022

Dr. Abhinandan Das

Lecturer-Department of
Physiology and Biochemistry,
Bengal Homoeopathic Medical
College and Hospital,
MXC8+7G2, Ismile, Shatabdi
Nagar, Asansol, West Bengal,
India

Dr. Tanmay Sarkar

Lecturer-Department of
Homoeopathic Pharmacy,
Metropolitan Homoeopathic
Medical College and Hospital,
Ramchandrapur, Sodepur,
Kolkata, West Bengal, India

Dr. Abhisake Sabud

Lecturer, Department of
Organon of Medicine, with
Homoeopathic Philosophy,
Kharagpur Homoeopathic
Medical College & Hospital.

Corresponding Author:

Dr. Abhinandan Das

Lecturer-Department of
Physiology and Biochemistry,
Bengal Homoeopathic Medical
College and Hospital,
MXC8+7G2, Ismile, Shatabdi
Nagar, Asansol, West Bengal,
India

Homoeopathic management can cure non-communicable chronic Atopic Eczema (Dermatitis) with Sleeplessness, indigestion & depression: A case report upon neurodermatitis

Dr. Abhinandan Das, Dr. Tanmay Sarkar and Dr. Abhisake Sabud

DOI: <https://doi.org/10.33545/26164485.2022.v6.i4i.711>

Abstract

Atopic dermatitis (AD) also known as atopic eczema is a chronic inflammatory dermatosis characterised by pruritus & chronicity due to antigen-antibody reaction manifesting on skin conditions associated with intra & intercellular Creaked & oedema. The prevalence of AD is 20% (5%–30% in the paediatric and 1%–10% in the adult population) worldwide; 3%–6% in Asian-Pacific countries, Eastern Mediterranean region, and India. A Hindu 45 years female chief complains were hot, dry skin in all over the body, dry eruption with a small brown-black scab in both palms, lower abdomen & soles. Ulcer formation corrodes & becomes deeper like punched-out edges with a tendency to penetrate and tenacious exudation without spreading in circumference & she suffered for 3-4 years. We evaluated this case on SCORAD Index & Assessment by Modified Naranjo Criteria Score. This case report highlighted the mental symptoms followed by physical & particular symptoms. The study was clearly shown the good scope of homoeopathic remedies work for treatment of Atopic Eczema (Dermatitis) along with mental complaints like, depression, anxiety, ill humour, low spirit, sleeplessness etc. There have some limitations to Atopic Eczema (Dermatitis) like, Sever bronchial asthma, hay fever, Alzheimer's disease, Multiple Sclerosis etc.

Keywords: Atopic dermatitis (AD), SCORAD Index, modified naranjo criteria score, sever bronchial asthma, hay fever, Alzheimer's disease, Multiple Sclerosis, CIHM

Introduction

Atopic dermatitis (AD) also known as atopic eczema or neuro dermatitis [(ICD-10, L28.0) & added quality of life, behavioural, emotional, and sleep disturbances, and family functioning] is a chronic inflammatory dermatosis characterised by pruritus & chronicity due to antigen-antibody reaction manifesting on skin conditions associated with intra & intercellular Creaked & oedema [1]. *Atopy* means exaggerated immunoglobulin E (IgE) & *Dermatitis* derives from the Greek “derma” which means skin and “itis” which means inflammation [2]. If anyone's family history has pruritic skin disease or asthma, allergic rhinitis, food allergies etc. are triggering factors [3]. Atopic dermatitis (AD) pathophysiology is either primary irritants like acids, alkalis, etc. or maybe secondary allergens like, Penicillin, Streptomycin, Lipsticks, Nail varnish, Hair dyes, and Plants Flowers [4]. Other factors like self or consciousness, anxiety, depression, loss of school days, work and daily activities, increase sick days in bed, sleeplessness due to pruritus, creaks impact on a personal relationship, participation limitation, and financial burden, genetic, dietetic (egg & milk) & heat, humidity, dryness also plays some role [4,5]. The symptomatology includes dry skin, papules, pruritus, Cracks, serous exudates, excoriation, and lichenification (a secondary skin lesion wherein the characteristic features of skin thickening, hyperpigmentation, and exaggerated skin lines) [4,5,6]. AD affects the face, extensor surfaces of the body, fold of arms, legs, Sole, Palm and neck. The prevalence of AD is 20% (5%–30% in the paediatric and 1%–10% in the adult population) worldwide; 12%–14% in Africa; 6%–10% in Latin America; 3%–6% in Asian-Pacific countries, Eastern Mediterranean region, and India [5,6,7]. Over the last 40 years, the incidence of AD has risen, it appears to be commoner in urban & semi-urban areas than in rural areas and in the industrialised as opposed to less industrialised countries [6,7,8]. Conventional treatment is dependent on severity and extent of disease, Basic use of moisturizers to improve the skin's hydration and barrier function.

Antihistamines, Anti-bacterial and antimycotic therapy, Topical anti-inflammatory medications, such as topical corticosteroids and topical calcineurin inhibitors, phototherapy, systemic immunosuppressants, and systemic corticosteroids are recommended for recalcitrant or severe cases [9, 10, 11]. These treatments are often cost effective with lots of side effect are present. The following cases are demonstrated of AD that has been successfully treated by constitutional Individualised homoeopathic Medicine (CIHM) after proper case taking and also demonstrate the utility of single and minimum doses in homoeopathy [12, 13, 14, 15, 21, 22].

Case Summary: A Hindu 45 years female visited Dr Abhinandan das O.P.D for a skin complaint. Her chief complaints were hot, dry skin in all over the body, dry eruption with a small black scab in both palms, lower abdomen & soles. The eruption begins in hot weather, itching with vesicular eruption & brown spots like scabs on fingers. Swellings were forming an irregular ulcer, covered with dry scabs & painful to touch, hard & dry. Ulcer formation corrodes & becomes deeper like punched-out edges with tendency to penetrate and tenacious exudation without spreading in circumference & she suffered for 3-4 years. Patient was restless, anxious, can't share anything to other, ill-humour, low-spirited. Forgetful & confused. She has weeping disposition. She

Before coming to the O.P.D, she was treated with modern medication (anti-fungal, anti-histamines with steroidal ointment) for 3-4 years by a dermatologist for Atopic Eczema (Dermatitis), at that time her complained was little ameliorate for 3-4 months and after that, eczema became more violent than earlier and She changed dermatologist in every time when she complained aggravated but each time complain not cure. Under these circumstances, she going to decide to take homoeopathic treatment.

There was a past history of skin irruption, dust allergy & treated with modern medication. Typhoid was affected in childhood. She had an addiction of tobacco chewing and took HTN allopathic tablet daily in the early morning. In the family history, the father and paternal grandfather had

hypertension and Mother had osteoarthritis with diabetes. The patient had short stature, dark complexion, and rough skin. She was very talkative & panic to complaints.

Homoeopathic Generalities

Mental Generals: Ill-humoured+++ , low-spirited++ , Aversion to mental exertion+++ , weak memory++ , Weeping disposition+.

Physical Generals: Appetites less++ , thirst full ++ , aversion to meat+++ , desire sweet+++ , sour+++ , bitter+ , Tongue thick brown yellowish coted +++ , Stool constipated with hard, knotty followed by burning in anus+++ , sensitive to cold & open air+++ , unrefreshing sleep, Headache & cough at 2 to 4 a.m.

Gynaecology history: She had 2 children & suffering from uterine prolapse worse in hot weather+++ with post menopause.

Miasmatic Analysis: In eczema all the chronic miasmas are reflected said by Allen [16, 33]. This case was also multi-miasmatic but the predominance of Psora and Syphilis could be found [17, 34].

Analysis & Totality of symptoms: Ill-humoured+++ , low-spirited++ , Aversion to mental exertion+++ , weak memory++ , Weeping disposition+ . Appetites less++ , thirst full ++ , aversion to meat+++ , desire sweet+++ , sour+++ , Tongue thick brown yellowish coted +++ , Stool constipated with hard, knotty followed by burning in anus+++ , sensitive to cold & open air+++ , unrefreshing sleep++ , Headache & cough at 2 to 4 a.m.++ & uterine prolapse++ , itching with vesicular eruption & brown spots like scabs on fingers of palm & sole++ , punched-out edges with tendency to penetrate and tenacious exudation without spreading in circumference+++ , hot, dry, body, dry eruption with a small black scab in both palms, lower abdomen & soles+++.

Clinical diagnosis: Atopic Dermatitis (Hanifin and Rajka-developed criteria for diagnosis in 1980) [18, 19, 20].

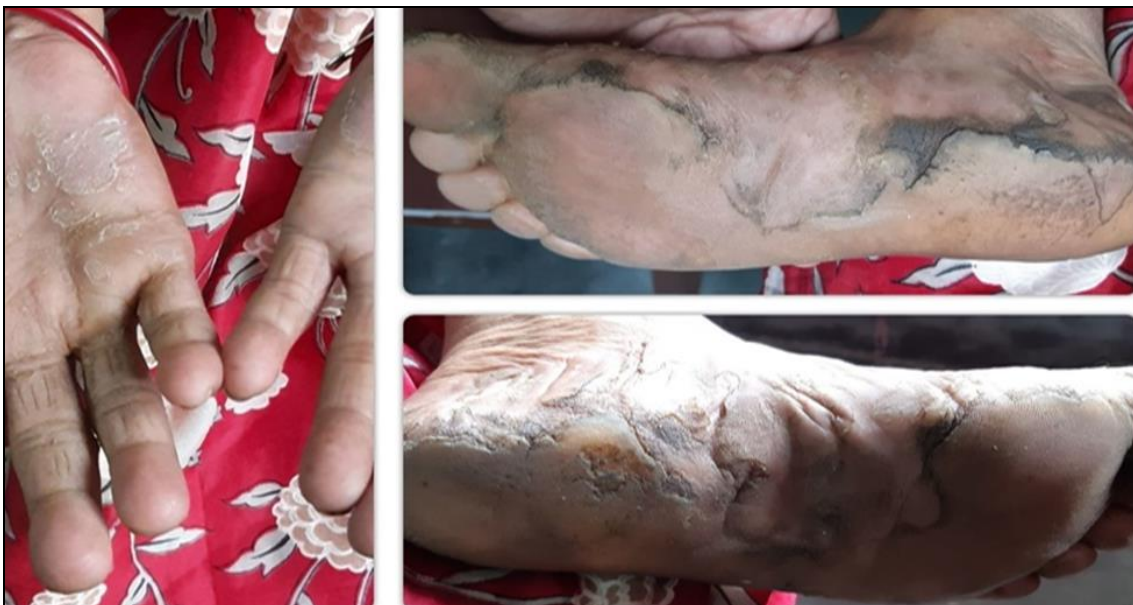

Fig 1: Before Homoeopathic Treatment

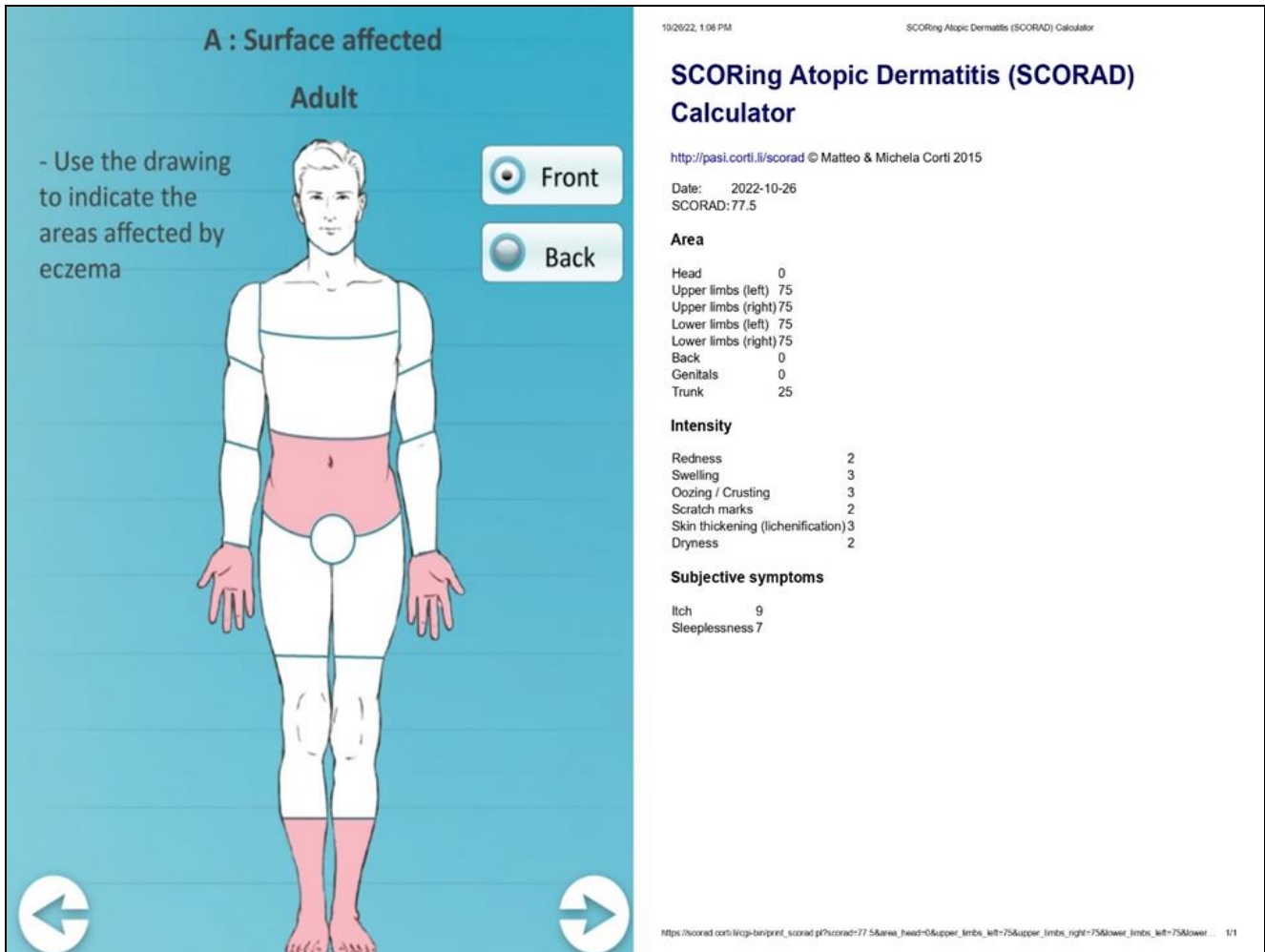


Fig 2: SCORAD index value before Homoeopathic treatment

Table 1: Reportorial analysis of the characteristic Symptoms

Remedy Name	Sulph	Sep	Phos	Calc	Nux-v	Nat-m	Lyc	Sil	Ars	Puls	Chin	Lach
Totality	58	53	50	48	48	47	47	47	44	43	42	42
Symptoms Covered	23	22	21	20	20	21	20	19	21	19	20	20
Kingdom												
[Kent] [Mind]Irritability (see anger):	3	3	3	3	3	3	3	3	2	3	2	2
[Kent] [Mind]Sadness,mental depression:	3	3	2	3	2	3	3	2	3	3	3	3
[Kent] [Mind]Exertion:Agg from mental:	2	3	2	3	3	3	3	3	1	2	2	3
[Kent] [Mind]Memory :Weakness of (see mistakes):	2	3	3	1	2	2	3	2	3	2	2	3
[Kent] [Mind]Weeping,tearful mood,etc.:	3	3	2	3	2	3	3	1	1	3	1	1
[Kent] [Stomach]Appetite:Wanting:	3	3	3	3	3	3	3	3	3	3	3	1
[Kent] [Stomach]Thirst:	3	1	3	3	2	3	1	3	3	1	3	2
[Kent] [Stomach]Aversion:Meat:	3	3	2	3	3	2	2	3	2	3	3	
[Kent] [Stomach]Desires:Sweets:	3	2		2	1	1	3		1		3	
[Kent] [Stomach]Desires:Sour,acids,etc.:	2	2	2	2		2			2	2	1	2
[Kent] [Mouth]Discoloration:Tongue:Brown:	2	2	3		2		2	2	3		2	3
[Kent] [Mouth]Discoloration:Tongue:Yellow:	2	2	2		2	1	1		1	2	2	2
[Kent] [Rectum]Constipation (see inactivity):	3	3	3	3	3	3	3	3	3	2	2	3
[Kent] [Stool]Hard:	3	3	3	3	3	3	3	3	2	2	1	3
[Kent] [Stool]Knotty,nodular,lumpy:	3	2	1	2	2	1	3	3	1		1	2
[Kent] [Rectum]Pain:Burning:Stool:After:	3	1	2	2	2	2	2	3	3	2		2
[Kent] [Generalities]Cold :In general agg:	2	3	3	3	3	2	3	3	3	2	3	1
[Kent] [Sleep]Unrefreshing:	2	2	3	1	2	2	2	2	2	2	2	3
[Kent] [Head]Pain,headache in general:Morning:	2	2	2	2	3	2		2	1	1	1	2
[Kent] [Cough]Morning:	3	2	3	3	3	2	2	2	3	3	3	1

Table 1: Continued.....

[Kent] [Genitalia female]Prolapsus :Uterus:	2	3	2	2	2	2	1	2	1	3	2	2
[Kent] [Extremities]Eruption:Fingers:Itching:												
[Kent] [Extremities]Eruption:Fingers:Scabs:							1					
[Kent] [Extremities]Eruption:Fingers:Vesicles:	2	2	1	1		2		2		2		1
[Kent] [Extremities]Eruption:Hand:Palm:Dry tetter:	2											

Bases of Selection Constitutional Individualized Homoeopathic Medicine (CIHM): - Repertorial analysis done by kent & Symptoms Cross cheek done by Clark

materia medica [23, 24, 25]. We selected 2nd remedy *Sepia* as a constitutional remedy.

Table no 2: Timeline including follow-up of the case

Date	Symptoms	Remedy
15/06/21 Prescription	Baseline presentation [Figure 1] severe itching (Pruritus), Scabs, papules, dryness, cracking of skin). Punched-out edges without spreading in circumference. Appetites less, ill-humour, low-spirited, unrefreshing sleep, depreion, stool constipated.	1) Sep 30(OD× 4 days) & 2) Placebo 30/ 30 ml (BD× PC)
13/07/21 1 st follow up	No new symptoms, no aggravation, skin and mental symptoms were same.	1) Placebo 30 (OD× 10 days) & 2) Placebo 200/ 30 ml (BD× PC)
10/08/21 2 nd follow up	No new symptoms & no aggravation happened but Skin complaints were mildly ameliorated.	1) Sepia 30 (OD× 06 days) & Placebo 200/30 ml (BD×PC)
21/09/21 3 rd follow up	Eczema - discharges less, itching persists but complaint ameliorated. No change on depression. Ill humour & low spirit symptoms, i.e., sadness, irritability, difficult concentration, sleeplessness, and restlessness, appetited less, constipation mildly ameliorated.	1) Sepia 200 (OD× 04 days) & Sac. Lac 200/ 18 dose (BD×PC)
03/11/21 4 th follow up	Eczema- itching, scabs, Punched-out edges & discharge less than earlier, mildly improvement in depression, forgetfulness, sleeplessness & restlessness complaints. Appetite good & stool regular, soft.	1) Placebo 200 (OD × 10 days) & 2) Sac. Lac 200/ 18 dose (BD× PC)
21/12/2021 5 th follow up	Eczema- complain as usual but the mental complaint was improved (50%) & Patient was affected by severe indigestion due to heavy meals.	1) Nuv.vom 200/globs (TDS × 7 days) & 2) Sac. Lac 200/ 10 dose (BD× PC)
11/01/22 6 th follow up	Skin complaints as usual but indigestion complain was ameliorated.	1) Placebo 200/ 100 ml (OD × 16 days)
01/02/22 7 th follow up	Skin complaints as usual but the Physical & mental symptoms were standstill.	1) Sepia 200 (OD× 04 days) & 2) Sac.lac 200/ 18 dose (BD× PC)
08/03/22 8 th follow up	Eczema - more drying, crusting, edges-reduced, looking better than earlier. Depression symptoms - sleep better and restlessness reduced, low spirit mood- better, other symptoms were same	1) Placebo 200 (OD× 4days) & 2) Sac.lac 200/13 dose (BD× PC)
19/04/22 9 th follow up	Eczema- complain little improved & The mental complaint was improved (70%)	1)Sepia 1M (OD×2 days) & 2) placebo 200/ 30 ml (BD× PC)
29/05/22 10 th follow up	Eczema - no more oozing, edges and crusting, Itching - less, mental symptoms showing improvements such as depression, low spirit mood was better, inattention and concentration difficulty reduced, irritability, and confusion- reduced Sleep - better, Stool soft.	1) Sulp 200/ 100 ml (BD× PC)
28/06/22 11 th follow up	All complaints were improving	1) Placebo 200/ 100 ml (BD× PC)
19/07/22 12 th follow up	Both AD, mental & physical complaints not returned. (Figure 03)	1) Placebo 200/ 100 ml (BD×PC)
23/08/22 13 th follow up	Both AD, mental & physical complaints not returned.	1) Placebo 200/ 100 ml (OD× 20 days)

Table 3: Assessment by Modified Naranjo Criteria Score [17, 18, 25, 26, 27, 28, 29]

Sl. No	Item/ Question	Yes	No	Not sure or N/A
01	Was there an improvement in the main symptom or condition for which the homoeopathic medicine was prescribed?	+2	0	0
02	Did the clinical improvement occur within a plausible time frame relative to the drug intake?	+1	-2	0
03	Was there an initial aggravation of symptom? (Need to define in glossary)	+1	0	0
04	Did the effect encompass more than the main symptom or condition, i.e., were other symptoms ultimately improved or changed?	+1	0	0
05	Did overall wellbeing improve? (Suggest using a validated scale)	+1	0	0
06 (A)	Direction of cure: did some symptoms improve in the opposite order of the development of symptoms of the disease?	+1	0	0
06 (B)	Direction of cure: did at least two of the following aspects apply to the order of improvement of symptoms -from organs of more importance to those of less importance - from deeper to more superficial aspects of the individual - from the top downwards.	+1	0	0
07	Did old symptoms” (Defined as non-seasonal and non-cyclical that were previously thought to have resolved) reappear temporarily during the course of improvement?	+1	0	0
08	Are there alternate causes (Other than the medicine) that-with a high probability- could have caused the improvement? (consider known course of disease, other forms of treatment and other clinically relevant intervention	-2	+1	0
09	Was the health improvement confirmed by any objective evidence? (e.g. lab test, clinical observation, etc.)	+1	0	0
10	Did repeat dosing, if conducted, create similar clinical improvement?	+2	0	0
Total score =Maximum score=13 Minimum score=02				Score=09

The interpretation of the total Naranjo Score predicting drug action is as follows: Total scores range from -4 to +13; the

reaction is considered definite if the score is 9 or higher, probable if 5 to 8, and possible if 1 to 4, and doubtful if 0 or less.

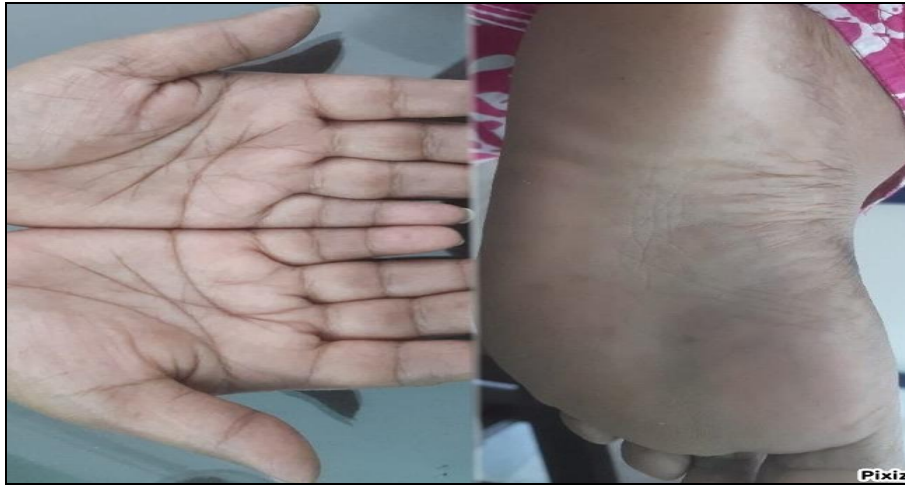

Fig 3: After Homoeopathic Treatment

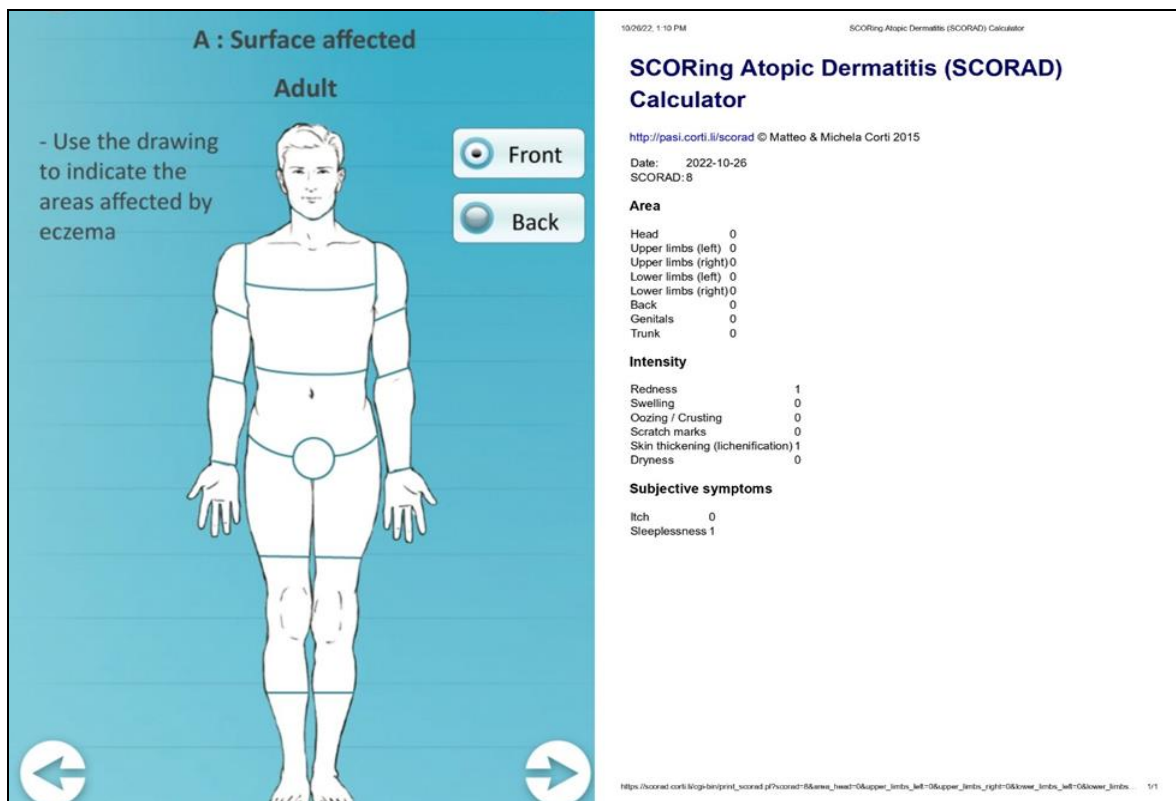


Fig 4: SCORAD Index value after Homoeopathic index

Discussion

Homoeopathy is the world’s 2nd largest system of treatment & it treats the patient not the disease. If we selected a proper Constitutional individualised Homoeopathic Medicine (CIHM) for the treatment then it works not only symptomatically but also works holistically [30, 31, 32]. In this case report, *SEPIA* was chosen as constitutionally. After the prescription, new symptoms like, Indigestion came on 5th follow-up & we prescribed *Nux.Vom* as a complementary remedy of *Sepia*. The 7th follows up symptom was standing and we prescribed it once again *Sepia* because complementary of *Nux.Vom*. In the 10th follow up clearly mentioned the complaints were gone both mentally & physically that’s why we gave *Sulphur* [33, 34, 35]. In the 11th to 13th follow up we prescribed a placebo because we observed the patient holistically. The Case report’s Figures 01 & 03 was a clear picture that *Sepia* worked beautifully &

In the SCORAD index (Figure no 2 & 4) was before 77.5 & after treatment 8. Assessment by Modified Naranjo Criteria Score (Table 3) 09 out of 13, which means CIHM work tremendously well.

Conclusion

Homoeopathic medicines are effective in the treatment of AD, which has been proven once again under this case report. If we selected remedies on the bases of totality symptoms and through individualization which covers the patient’s Miasmatic background. These types of remedy selection procedures have the capability to cure the patient at inner level & patient relief constitutionally. Always remember a good case taking is definitely helping for selection of accurate remedies. This case report highlighted the mental symptoms followed by physical & particular symptoms. It’s very unique case report as comparison to

others because it's followed proper homoeopathic guidelines & proper Kent case taking. Constitutional Individualized Homoeopathic Medicine (CIHM) is also capable to cure the mental symptoms of the comorbidity AD patient. *Sepia* followed by *Nuv vomica* proved once again without doubt that it can cure the characteristic symptoms of AD, along with mental symptoms. This study was clearly shown the good scope of homoeopathic remedies work for the treatment of Atopic Eczema (Dermatitis) along with mental complaints like, depression, anxiety, ill humour, low spirit, sleeplessness etc. There have some limitations for Atopic Eczema (Dermatitis) like, Sever bronchial asthma, hay fever, Alzheimer's disease, Multiple Sclerosis etc. So, before going to start medication, always remember these limitations. Further research study like, RCT, Case report etc. needed on this topic for the betterment of Homoeopathy.

Declaration of patient consent: -The author certifies that she has obtained the appropriate patient consent forms. In the form, the patient has given her consent for her images and other clinical information to be reported in the journal. The patient understands that her name and initials will not be published.

Acknowledgement: Authors are especially thankful to the Principal Sir of Bengal Homoeopathic Medical College & Hospital. Also, thankful to Principal Sir of Bengal Homoeopathic Medical College & Hospital for their support.

Conflicts of interest: -None declared.

Financial support and sponsorship: Nil

References

1. Agrawal E, Gautam AK, Shaikh AR, Dutta S, Dey S, Mukherjee SK, *et al.* Factor structure of the Bengali version of atopic dermatitis burden scale for adults: A cross-sectional study. *J Dermatol Dermatol Surg.* 2021; 25(2):102-13.
2. Pathak Kumar Praveen, Sahani KM. Atopic dermatitis. *A Homoeopathic Review. Journal of Medical and Pharmaceutical Innovation, All Rights Reserved.* 2020, 7(35).
3. Fatani MI, Al Sheikh AA, Alajlan MA, Alharithy RS, Binamer Y, Albarakati RG, *et al.* National Saudi Consensus Statement on the Management of Atopic Dermatitis. *Dermatol Ther (Heidelb).* 2021-2022 Jul;12(7):1551-1575. Doi: 10.1007/s13555-022-00762-6. Epub 2022 Jul 4. PMID: 35788543; PMCID: PMC9252549.
4. Bieber T. Atopic dermatitis: An expanding therapeutic pipeline for a complex disease. *Nat Rev Drug Discov.* 2022 Jan;21(1):21-40. Doi: 10.1038/s41573-021-00266-6. Epub 2021 Aug 20. PMID: 34417579; PMCID: PMC8377708.
5. Bosma AL, Ascott A, Iskandar R, Farquhar K, Matthewman J, Langendam MW, *et al.* Classifying atopic dermatitis: A systematic review of phenotypes and associated characteristics. *Journal of the European Academy of Dermatology and Venereology.* 2022 Jun;36(6):807-19.
6. Arents BWM, van Zuuren EJ, Vermeulen S, Schoones JW, Fedorowicz Z. Global Guidelines in Dermatology Mapping Project (GUIDEMAP), a systematic review of atopic dermatitis clinical practice guidelines: are they clear, unbiased, trustworthy and evidence based (CUTE)? *Br J Dermatol.* 2022 May;186(5):792-802. Doi: 10.1111/bjd.20972. PMID: 34984668; PMCID: PMC9325494.
7. Griffiths C, de Bruin-Weller M, Deleuran M, Fargnoli MC, Staumont-Sallé D, Hong CH, *et al.* Dupilumab in Adults with Moderate-to-Severe Atopic Dermatitis and Prior Use of Systemic Non-Steroidal Immunosuppressants: Analysis of Four Phase 3 Trials. *Dermatol Ther (Heidelb).* 2021 Aug;11(4):1357-1372. Doi:10.1007/s13555-021-00558-0. Epub 2021 Jun 18. PMID: 34142350; PMCID: PMC8322347.
8. Darsow U, Wollenberg A, Simon D, Taïeb A, Werfel T, Oranje A, Gelmetti C, Svensson A, *et al.* European Task Force on Atopic Dermatitis / EADV Eczema Task Force. Difficult to control atopic dermatitis. *The World Allergy Organization Journal.* 2013;6(1):6. <https://doi.org/10.1186/1939-4551-6-6>
9. Schmidt S, Olsen M, Schmidt M, Vestergaard C, Langan SM, Deleuran MS, *et al.* Atopic dermatitis and risk of atrial fibrillation or flutter: A 35-year follow-up study. *Journal of the American Academy of Dermatology.* 2020;83(6):1616-1624. <https://doi.org/10.1016/j.jaad.2019.08.039>
10. Kim J, Kim BE, Leung DY. Pathophysiology of atopic dermatitis: Clinical implications. In *Allergy and asthma proceedings 2019 Mar 40(2):84.* Ocean Side Publications.
11. Bagdi Navita, Choudhary Hanuman. A case report for successful treatment of atopic dermatitis (AD) with a Constitutional homoeopathic medicine *Natrum muriaticum.* 2020;4:46-51.
12. Parveen Suraia. Homoeopathic treatment in a case of co-morbid atopic dermatitis and depressive disorder. *Indian Journal of Research in Homoeopathy.* 2016;10:75. 10.4103/0974-7168.179145.
13. Rossi E, Bartoli P, Bianchi A, Da Frè M. Homeopathy in paediatric atopic diseases: long-term results in children with atopic dermatitis. *Homeopathy.* 2012 Jan;101(01):13-20.
14. Das Mousumi. Atopic Dermatitis: Case Series of Individualized Homoeopathic Treatment: *International Journal of Health Sciences and Research.* November 2021, 11(11). Website: www.ijhsr.or, Case Series ISSN: 2249-957. DOI: <https://doi.org/10.52403/ijhsr.20211114>
15. Sithara VP, Sankar AS, Dr. Suman Prasobh. Homoeopathic cure in a case of atopic dermatitis. *International Journal of Homoeopathic Sciences.* 2022;6:76-78. 10.33545/26164485.2022.v6.i3b.599.
16. Dey S, Shaikh AR, Saha S, Agrawal E, Gautam AK, Karuppusamy A, *et al.* Efficacy of Individualized Homeopathic Medicines in the Treatment of Atopic Dermatitis in Adults: A Double-Blind, Randomized, Placebo-Controlled, Preliminary Trial. *Complement Med Res.* 2022;29(1):17-26. Doi: 10.1159/000516026
17. Saima Shamim, Amulya Ratna Sahoo, Umakanta Prusty, Chintamani Nayak. Role of Homoeopathy in Infectious Eczematous Dermatitis: A Case Report. *Int J Hom Sci* 2022;6(3):12-16. DOI: 10.33545/26164485.2022.v6.i3a.591

18. Nwabudike Lawrence Chukwudi. Atopic Dermatitis and Homeopathy. *Our Dermatology Online*. 2012;3(3):217-220. 10.7241/ourd.20123.50.
19. Mahesh S, Mallappa M, Habchi O, Konstanta V, Chise C, Sykiotou P, *et al.* Appearance of Acute Inflammatory State Indicates Improvement in Atopic Dermatitis Cases Under Classical Homeopathic Treatment: A Case Series. *Clin Med Insights Case Rep*. 2021 Feb 11;14:1179547621994103. doi: 10.1177/1179547621994103. PMID: 33628071; PMCID: PMC7882755.
20. Sach TH, McManus E, Levell NJ. Understanding economic evidence for the prevention and treatment of atopic eczema. *Br J Dermatol*. 2019 Oct;181(4):707-716. Doi: 10.1111/bjd.17696. Epub 2019 Apr 11. PMID: 30693473; PMCID: PMC6790711.
21. Roll S, Reinhold T, Pach D, Brinkhaus B, Icke K, Staab D, *et al.* Comparative effectiveness of homoeopathic vs. conventional therapy in usual care of atopic eczema in children: long-term medical and economic outcomes. *PLoS One*. 2013;8(1):e54973. doi: 10.1371/journal.pone.0054973. Epub 2013 Jan 31. PMID: 23383019; PMCID: PMC3561412.
22. Dr. Gurpreet Kaur Gill, Dr. Suruchi Sharda. Atopic dermatitis: The lesser indicated homoeopathic medicines. *Int J Hom Sci*. 2021;5(4):255-258. DOI: 10.33545/26164485.2021.v5.i4d.482
23. A Dictionary of Practical Materia Medica By John Henry Clarke, M.D.
24. Dr. Priyanka Nagar. Stress does hurt skin: Stress and atopic dermatitis. *International Journal of Homoeopathic Sciences*. 2020;4(3):95-97. E-ISSN: 2616-4493, P-ISSN: 2616-4485
25. Silvestre Marilene Chaves, Reis, Vitor Manoel Silva dos. Evaluation of the profile of inflammatory cytokines, through immunohistochemistry, in the skin of patients with allergic contact dermatitis to nickel in the acute and chronic phases* * Work conducted at Faculdade de Medicina, Universidade de São Paulo, São Paulo (SP); and Hospital das Clínicas, Universidade Federal de Goiás, Goiás (GO), Brazil.. *Anais Brasileiros de Dermatologia* [online]. 2018;93(6):829-835. [Accessed 25 October 2022], Available from: <<https://doi.org/10.1590/abd1806-4841.20187126>>. ISSN 1806-4841. <https://doi.org/10.1590/abd1806-4841.20187126>.
26. Feldman SR, Cox LS, Strowd LC, Gerber RA, Faulkner S, Sierka D, *et al.* The Challenge of Managing Atopic Dermatitis in the United States. *American health & drug benefits*. 2019;12(2):83-93.
27. Dr. Esha Tyagi, Dr. Prerna Tiwari. Homoeopathic veterinary in skin: A systematic review. E-ISSN: 2616-4493, P-ISSN: 2616-4485, *IJHS*. 2019;3(2):89-92.
28. Fania L, Moretta G, Antonelli F, Scala E, Abeni D, Albanesi C, *et al.* Multiple Roles for Cytokines in Atopic Dermatitis: From Pathogenic Mediators to Endotype-Specific Biomarkers to Therapeutic Targets. *Int J Mol Sci*. 2022 Feb 28;23(5):2684. doi: 10.3390/ijms23052684. PMID: 35269828; PMCID: PMC8910412.
29. Wollenberg A, Barbarot S, Bieber T, Christen-Zaech S, Deleuran M, Fink-Wagner A, *et al.* European Dermatology Forum (EDF), the European Academy of Dermatology and Venereology (EADV), the European Academy of Allergy and Clinical Immunology (EAACI), the European Task Force on Atopic Dermatitis (ETFAD), European Federation of Allergy and Airways Diseases Patients' Associations (EFA), the European Society for Dermatology and Psychiatry (ESDaP), the European Society of Pediatric Dermatology (ESPD), Global Allergy and Asthma European Network (GA2LEN) and the European Union of Medical Specialists (UEMS). Consensus-based European guidelines for treatment of atopic eczema (atopic dermatitis) in adults and children: part II. *J Eur Acad Dermatol Venereol*. 2018 Jun;32(6):850-878. Doi: 10.1111/jdv.14888. PMID: 29878606.
30. Jamadade Kumar Arun, Basavaraj S Adi. Atopic dermatitis with homoeopathic medicine *graphites*: A CASE REPORT. *International Journal of Alternative and Complementary Medicine*.
31. Bhattacharjee Baidurjya, Pachuau Vanlalfakawmi. Homoeopathic Treatment of Atopic Dermatitis in an Infant: A Case Report. *Homoeopathic Links*; c2020. 10.1055/s-0040-1714382.
32. Drucker AM, Eyerich K, de Bruin-Weller MS, Thyssen JP, Spuls PI, Irvine AD, Girolomoni G, *et al.* Use of systemic corticosteroids for atopic dermatitis: International Eczema Council consensus statement. *Br J Dermatol*. 2018 Mar;178(3):768-775. Doi: 10.1111/bjd.15928. Epub 2018 Jan 28. PMID: 28865094; PMCID: PMC5901393.
33. Allen JH. The chronic miasmas with repertory. Rearranged and augmented ed. New Delhi: B. Jain Publishers (P) Ltd, 2007, 196-199.
34. Roberts HA. The Principles and Art of Cure by Homoeopathy. 12th impression. New Delhi: B. Jain Publishers (P) Ltd. 2012, 204-231.
35. Homoeopathic Comparative Materia Medica By N. C. Ghosh
36. Das Abhinandan, Jadhav Arun, Jadhav Ravikiran. "Antagonistic Effect of Homoeopathic Preparations on *Acinetobacter baumannii*, A Common Nosocomial Infectious Agent through *In Vitro* Study. 2022;9:36-42. 10.9790/1959-0903063642.
37. Tanmay Sarkar, Abhinandan Das. A case report of appendicitis and management by alternative treatment of medicine. *Int J Health Sci Res*. 2022;12(9):190-193. DOI: <https://doi.org/10.52403/ijhsr.20220926>
38. Ostermann JK, Witt CM, Reinhold T. A retrospective cost-analysis of additional homeopathic treatment in Germany: Long-term economic outcomes. *PLoS One*. 2017 Sep 15;12(9):e0182897. doi: 10.1371/journal.pone.0182897. PMID: 28915242; PMCID: PMC5600367.
39. Abhisake Sabud, Abhinandan Das. Homoeopathic constitutional medicine helps to cure ovarian cyst: A case report. *Int J Hom Sci* 2022;6(4):319-324. DOI: 10.33545/26164485.2022.v6.i4e.678.

How to Cite This Article

D Abhinandan, S Tanmay, S Abhisake. Homoeopathic management can cure non-communicable chronic Atopic Eczema (Dermatitis) with Sleeplessness, indigestion & depression: A Case Report upon neurodermatitis. *International Journal of Homoeopathic Sciences*. 2022;6(4):566-572.

Creative Commons (CC) License

This is an open access journal, and articles are distributed under the terms of the Creative Commons Attribution-NonCommercial-ShareAlike 4.0 International (CC BY-NC-SA 4.0) License, which allows others to remix, tweak, and build upon the work non-commercially, as long as appropriate credit is given and the new creations are licensed under the identical terms.