



International Journal of Homoeopathic Sciences

E-ISSN: 2616-4493
P-ISSN: 2616-4485
www.homoeopathicjournal.com
IJHS 2022; 6(4): 584-587
Received: 06-08-2022
Accepted: 10-09-2022

Dr. Madhu Gautam
Post-Graduate Trainee,
Department of Case Taking
and Repertory, National
Institute of Homoeopathy,
Govt. of India, Block GE,
Sector 3, Salt Lake, Kolkata,
West Bengal, India

Dr. Ajay Kumar Yadav
Post-Graduate Trainee,
Department of Case Taking
and Repertory, National
Institute of Homoeopathy,
Govt. of India, Block GE,
Sector 3, Salt Lake, Kolkata,
West Bengal, India

Dr. Shweta Gupta
Post-Graduate Trainee,
Department of Case Taking
and Repertory, National
Institute of Homoeopathy,
Govt. of India, Block GE,
Sector 3, Salt Lake, Kolkata,
West Bengal, India

Dr. Sanjay Kumar
Post-Graduate Trainee,
Department of Case Taking
and Repertory, National
Institute of Homoeopathy,
Govt. of India, Block GE,
Sector 3, Salt Lake, Kolkata,
West Bengal, India

Dr. Birendra Prasad Srivastava
Professor, Department of Case
Taking and Repertory,
National Institute of
Homoeopathy, Govt. of India,
Block GE, Sector 3, Salt Lake
Kolkata, West Bengal, India

Corresponding Author:
Dr. Madhu Gautam
Post-Graduate Trainee,
Department of Case Taking
and Repertory, National
Institute of Homoeopathy,
Govt. of India, Block GE,
Sector 3, Salt Lake, Kolkata,
West Bengal, India

Individualized homoeopathic treatment of vitiligo: A case report

Dr. Madhu Gautam, Dr. Ajay Kumar Yadav, Dr. Shweta Gupta Dr. Sanjay Kumar and Dr. Birendra Prasad Srivastava

DOI: <https://doi.org/10.33545/26164485.2022.v6.i4i.713>

Abstract

Vitiligo is a common chronic skin depigmentation disorder. Vitiligo affects about 1% of population in world and is characterized by depigmented patches of skin from which melanocytes (melanin producing cells) have been lost. There are different types of vitiligo, in which the most common type is non-segmental generalized vitiligo, that are widely distributed, usually symmetric, and progressive lesions. Vitiligo has a great impact on the physical and mental health of patients, including loss of skin photo protection and an appreciable reduction in quality of life that is directly correlated with the early age of onset (especially first two decades of life).

This case study suggests homoeopathic treatment as a promising complementary or alternate therapy, which emphasising the significance of repertorization with Kent's Repertory and individualized homoeopathic prescription in the patients suffering from vitiligo.

Keywords: Vitiligo, homoeopathic treatment, hypo-pigmented patches, case report, kent's repertory, symptoms, rubrics, repertorization

Introduction

Skin disease is known to have a significant impact on quality of life, productivity and mental health. The Global Burden of Disease (GBD) Study 2013, found skin disease to be the fourth (non-fatal) cause of disability worldwide [4]. Vitiligo is the most common skin disorder of depigmentation or hypo-pigmentation. The prevalence of vitiligo was ranged from 0.06-2.28% in 2012, worldwide [5, 6]. It is characterized by the absence of melanin pigment in the skin, that is secondary to the loss of melanocytes [5, 7]. Melanocytes are the cells which are present in several tissues in the skin, hair follicles, eyes, inner ear, bones, heart, brain and in the basal layer of the epidermis, together with the surrounding keratinocytes form the epidermal unit, whose main function is to produce and distribute melanin by a complex process, that process is known as Melanogenesis [8, 11]. Melanin is a pigment, having two forms, eumelanin (brown/black or black) and pheomelanin (red/yellow) [10, 12]. It has light-absorbing property that confer photoprotection [8, 10-12]. Melanogenesis is determined genetically but is influenced by several intrinsic and extrinsic factors [9]. The intrinsic factors are released by surrounding cells, including keratinocytes, fibroblasts, inflammatory, neural and endocrine cells [8, 9, 10, 13, 14]. The extrinsic factors are ultraviolet radiation and drugs [9]. The presentation of vitiligo is asymptomatic depigmented macules anywhere on the body including mucous membranes of lips and genitalia, etc. It can affect whole population in the world and 8.8% prevalence have been reported in India, where considerable stigma is attached to the disease.

Depigmented patches can appear anywhere on the skin, but most commonly affected sites are area around the orifices, the genitals or any sun-exposed areas such as the face and hands. The hair and eye may also be affected however chances are less [15].

There are some studies which shows, fifty percent of cases appear before the age of 20, with the disfigurement resulting in psychiatric morbidity in 16%–35% of those affected. Depression, sleep disturbances, suicidal thoughts, suicidal attempts, difficulties in relationships, and avoidance of social situations have been reported in individuals afflicted by vitiligo before adulthood [15].

The proportion of patients with genetic inheritance varies from one part of the world to another and some studies show the impact of family history of vitiligo has a connection, it is approximately 40%. In India, in particular, it ranges from 6.25% to 18% [15].

Homeopathy is a system of medicine which includes a holistic approach in the understanding of the patients and integrates this approach to provide individualized treatment. There are certain diseases which may manifest when genetic predisposition combines with stress, etc. Homeopathy considers the patient’s susceptibility to certain kind of stress, which means that homeopathy can be more successful during the early development of a disease, even before conventional medicine usually begins [16].

Case Proper

A 45 years old lady from Ballygunje, Kolkata, West Bengal, visited the OPD of National Institute of Homoeopathy on 6th AUG. 2021, presented with complaint of Hypo-pigmented patches on body for last 6 years.

- Location - upper back, left side of lower back.
- Margins of the white patches are well demarcated.
- No sensory impairment
- No itching on affected area.

History of present complaints

Patient was apparently well 6 years before. She noticed small hypo-pigmented spot on left side lower back and upper back (near nape of neck). Spots gradually increased in size. There was a history of allopathic treatment without any noticeable improvement.

Past history

1. Typhoid fever - at 25 years of age - Allopathic treatment was given.
2. Chikungunya - 5 years back – Allopathic treatment was given.

Family history

- Mother – Suffering from Osteoarthritis.

- Father - History of Pulmonary tuberculosis at age of 47 years.

Mental generals

- Irritability
- Desire form company
- Consolation amelioration
- Anxiety about her health
- Likes to clean the things and arranging them properly.

Physical Generals

- Appetite – Good, can tolerate hunger well
- Thirst – 5-6 L/ day, Increased, takes water frequently but little at a time.
- Desire – Salt (2+), warm food (1+)
- Stool – Irregular, on alternate days
- Urine – D (9-10) N (1-2), sometimes burning sensation during urination.
- Perspiration – Generalised, profuse, stains the clothes yellow
- Sleep – Good, prefers to lie on abdomen
- Dreams – Dreams of accidents
- Thermal reaction – Chilly

Totality of symptoms

1. Likes to clean the things and arrange them
2. Anxiety about health
3. Thirst increased, drinks water often
4. Desire for salty food
5. Profuse sweat, stains the clothes yellow
6. Dreams of accidents
7. Prefers to lie on abdomen
8. Chilly patient
9. White patches on upper back and left side of lower back.

Table 1: Conversion of symptoms into rubrics

S. N.	Symptoms	Chapter	Rubrics
1	Likes to clean the things and arrange them	Mind	Fastidious
2	Anxiety about health	Mind	Anxiety, health about
3	Thirst increased, drinks water often	Stomach	Thirst, small quantities, for, often
4	Desire for salty food	Stomach	Desires, salt things
5	Profuse sweat	Perspiration	Profuse
6	stains the clothes yellow	Perspiration	Staining the linen, yellow
7	Dreams of accidents	Sleep	Dreams, accidents
8	Prefers to lie on abdomen	Sleep	Position, abdomen, on
9	White patches on upper back and left side of lower back.	Skin	Discolouration, white, spots




Fig 1: Repertorization [17]

Reportorial result

- 1. Arsenic Album – 17 / 8
- 2. Sulphur – 9 / 6
- 3. Bell. – 10 / 5
- 4. Calc. - 10 / 5

This case was repertorised using Kent’s Repertory and software Radar 10. The repertorial result was analysed, giving more priority to mental symptoms as well as physical general symptoms for selection. According to repertorization, the most indicated remedy was Arsenic Album.

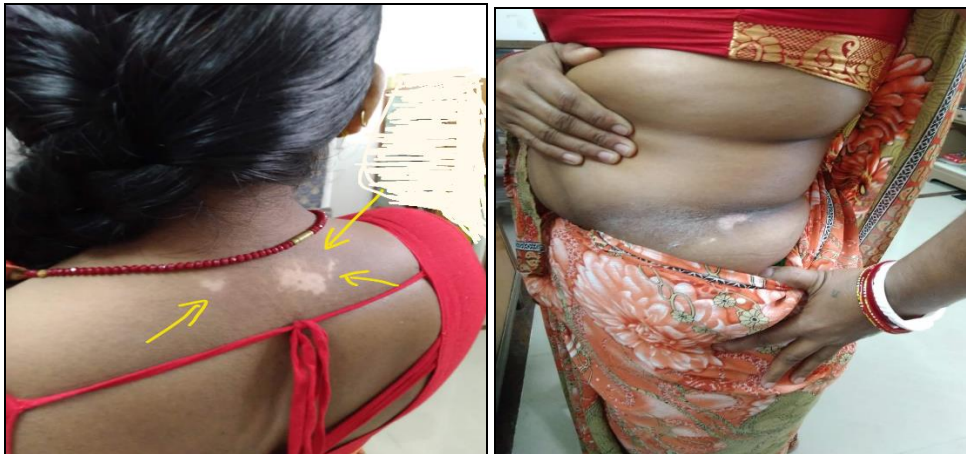Prescription

After considering the totality of symptoms and analysis of repertorial result, Arsenic Album 0/1, 16 doses of each potency was prescribed in 100 ml of aqua dist. orally, on alternate day for 32 days. The potency was gradually increased up to Arsenic Album 0/10 with progressive improvement in hypo-pigmented patches.

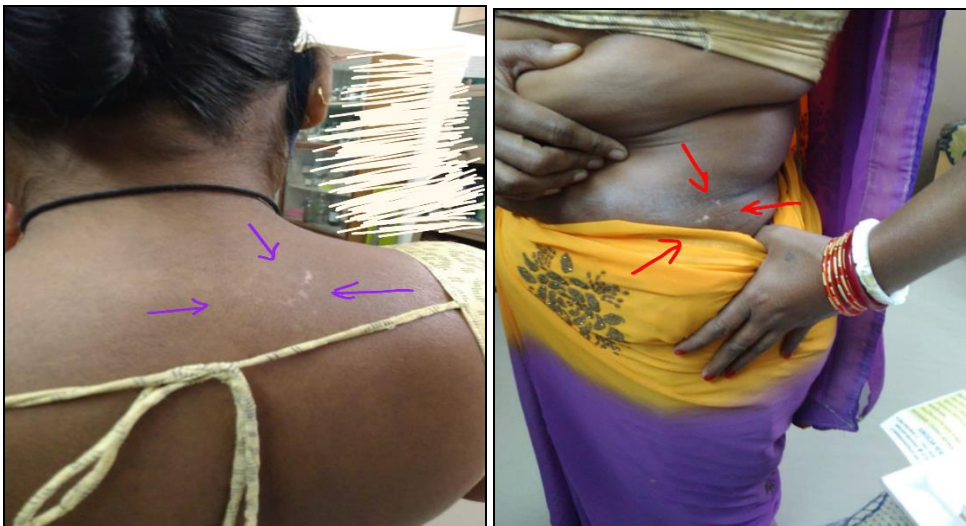Pictures

Before Treatment –

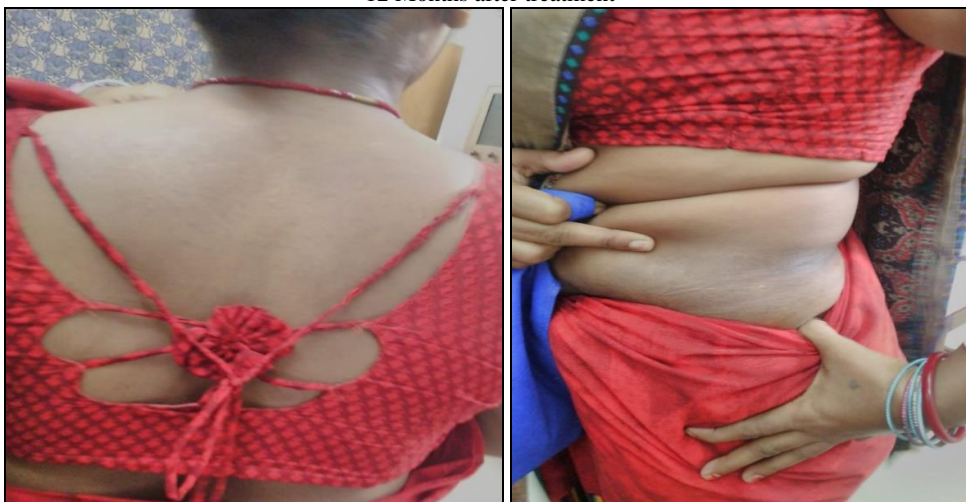Before Treatment



6 Months after treatment



12 Months after treatment



Discussion

A 45 years old lady from Ballygunje, Kolkata, West Bengal, visited the OPD of National Institute of Homoeopathy on 6th AUG. 2021, presented with complaint of hypo-pigmented patches on body for last 6 years. Hypo-pigmented patches were on upper back near nape of neck and left side of lower back without any other complaint such as itching or sensation loss, etc. The size and shape of patches were gradually increasing. After proper case taking and repertorization with the help of Kent's Repertory, Arsenic Album was Selected. Arsenic Album 0/1 to Arsenic album 0/10, 16 doses of each potency on alternate days were administered to the patient on the basis of totality of symptoms. The medicine was given in fifty millesimal potency. Improvement was visible after 4 months of treatment as hypo-pigmented spots started decreasing and colour of affected spots getting same skin tone. Patient was completely cured after 12 months of treatment.

Vitiligo seemed to respond well to individualized homoeopathic medicine after repertorization with Kent's Repertory. In this case report, homoeopathic treatment is recommended as a promising complementary or alternative therapy.

Conclusion

A lady of 45 years old, presented with complaint of hypo-pigmented patches on upper back near nape of neck and left side of lower back without any other complaint, for past 6 years. After proper case taking and repertorization with the help of Kent's Repertory, Arsenic Album was Selected. Arsenic Album 0/1 to Arsenic album 0/10, 16 doses of each potency on alternate days were administered to the patient on the basis of totality of symptoms. Improvement was visible after 4 months of treatment as hypo-pigmented spots started decreasing and colour of affected spots getting same skin tone. Patient was completely cured after 12 months of treatment. This case report also emphasis the significance of repertorization with Kent's Repertory and individualised homoeopathic prescription.

Declaration of patient consent: Nil

Financial support and sponsorship: Nil.

Conflicts of interest: None declared.

References

1. Le Poole IC, Das PK, van den Wijngaard RM, *et al.* Review of the etiopathomechanism of vitiligo: a convergence theory. *Exp Dermatol.* 1993;2(4):145-53.
2. Le Poole C, Boissy RE: Vitiligo. *Semin Cutan Med Surg.* 1997;16(1):3-14.
3. Parsad D, Dogra S, Kanwar AJ. Quality of life in patients with vitiligo. *Health Qual Life Outcomes.* 2003;1:58.
4. Wootton CI, Bell S, Philavanh A, *et al.* Assessing skin disease and associated health-related quality of life in a rural Lao community. *BMC Dermatol;* c2018, 18(11).
5. Ezzedine K, Eleftheriadou V, Whitton M, van Geel N.0 Vitiligo. *Lancet.* 2015;386:74-84.
6. Krüger C, Schallreuter KU. A review of the worldwide prevalence of vitiligo in children/adolescents and adults. *Int. J Dermatol.* 2012;51:1206-1212.
7. Gauthier Y, Cario Andre M, Taïeb A. A critical

appraisal of vitiligo etiologic theories. Is melanocyte loss a melanocytorrhagy? *Pigment Cell Res.* 2003;16:322-332.

8. D'Mello SA, Finlay GJ, Baguley BC, Askarian-Amiri ME. Signaling pathways in melanogenesis. *Int. J Mol. Sci.* 2016;17:1144.
9. Videira IF, Moura DF, Magina S. Mechanisms regulating melanogenesis. *A Bras Dermatol.* 2013;88:76-83.
10. Costin GE, Hearing VJ. Human skin pigmentation: Melanocytes modulate skin color in response to stress. *FASEB J.* 2007;21:976-994.
11. Hara M, Toyoda M, Yaar M, Bhawan J, Avila EM, Penner IR, Gilchrist BA. Innervation of melanocytes in human skin. *J Exp Med.* 1996;184:1385-1395.
12. Ohbayashi N, Fukuda M. Recent advances in understanding the molecular basis of melanogenesis in melanocytes. *F1000Res* 9: F1000 Faculty Rev-608, 2020.
13. Slominski A, Tobin DJ, Shibahara S, Wortsman J. Melanin pigmentation in mammalian skin and its hormonal regulation. *Physiol Rev.* 2004;84:1155-1228.
14. Slominski A, Zmijewski MA, Pawelek J. L-tyrosine and L-dihydroxyphenylalanine as hormone-like regulators of melanocyte functions. *Pigment Cell Melanoma Res.* 2012;25:14-27.
15. Dewan D, Taneja D, Singh U, Mittal R, *et al.* A Homoeopathic research in vitiligo: Current scenario. *Indian J Res Homoeopathy.* 2017;11:226-36.
16. Mahesh S, Mallappa M, Tsintzas D, Vithoulkas G. Homeopathic Treatment of Vitiligo: A Report of Fourteen Cases. *Am J Case Rep.* 2017 Dec 2;18:1276-1283.
17. Kent's Repertory (RADAR opus 3.1.5).

How to Cite This Article

Gautam M, Yadav AK. Individualized homoeopathic treatment of vitiligo: A case report. *International Journal of Homoeopathic Sciences.* 2022;6(4):584-587.

Creative Commons (CC) License

This is an open access journal, and articles are distributed under the terms of the Creative Commons Attribution-NonCommercial-ShareAlike 4.0 International (CC BY-NC-SA 4.0) License, which allows others to remix, tweak, and build upon the work non-commercially, as long as appropriate credit is given and the new creations are licensed under the identical terms.