



International Journal of Homoeopathic Sciences

E-ISSN: 2616-4493
P-ISSN: 2616-4485
IJHS 2019; 3(2): 74-76
Received: 10-02-2019
Accepted: 12-03-2019

Dr. Esha Tyagi
PG. Scholars, Department of
Materia Medica, Bharati
Vidyapeeth (Deemed to be)
University, Homoeopathic
Medical College & Hospital,
Pune, Maharashtra, India

Case report management of ovarian cyst through Homoeopathy: A case report

Dr. Esha Tyagi

Abstract

Ovarian cyst is an endocrine disorder that affects approximately 30% of all women which is commonly found in our day practice. We report a case of 52 years old female suffering from ovarian cyst reported here was treated successfully within 3 months by a single individualised constitutional homoeopathic medicine *Lachesis mutus* 200 with repetition as per required. The improvement is evident from symptomatic relief and ultrasonography (USG) reports. The case was further observed for 2.5 years without recurrence which suggest that permanent cure is possible through constitutional homoeopathic treatment.

Keywords: Metrorrhagia, dysmenorrhoea, ovarian cyst, constitutional homoeopathic treatment

Introduction

Cases of ovarian cysts, both single and multiple, are being increasingly reported in women of reproductive age ^[1]. An ovarian cyst is formed by the collection of fluid surrounded by a very thin wall within an ovary and any such follicle larger than about two centimetres qualifies for being termed as an ovarian cyst ^[2]. Though most of them are small like a pea grain and benign or harmless in nature, some of them alarmingly grow in size and occasionally cause severe pain in the abdomen; patients bearing such large-sized cysts often complain of associated menstrual irregularities with excessive bleeding. In some patients, certain undesirable symptoms like dull aching or sudden sharp stitching pain in lower abdomen, pain during coition or even during bowel movements are also reported. If patients with these symptoms visit an orthodox medical practitioner or a surgeon, they are generally advised for surgical intervention to save the patient from further unwanted sufferings, which may even include a life-threatening condition in stray cases. In general, patients and homeopathic practitioners feel equally unsure if homeopathic remedies can give them relief from their pains and sufferings, and can remove these cysts within a reasonable time span. This is partly because of lack of systemic research and publication of success/failure reports with proper and authentic documentation ^[3]. In this regard here a case of cyst by the administration of a single remedy, *Lachesis mutus* 200, selected on the basis of totality of symptoms.

Ovarian cysts are the most common fetal and infant tumor, with a prevalence exceeding 30%. The incidence of ovarian carcinoma is approximately 15 cases per 100,000 women per year Dec 20, 2018 ^[4]

What is an ovarian cyst?

An ovarian cyst is a sac or pouch filled with fluid or other tissue that forms in or on an ovary. Ovarian cysts are very common. They can occur during the childbearing years or after menopause. Most ovarian cysts are benign (not cancer) and go away on their own without treatment. Rarely, a cyst may be malignant (cancer) ^[5]

Types of ovarian cysts

There are various types of ovarian cysts, such as dermoid cysts and endometrioma cysts. However, functional cysts are the most common type. The two types of functional cysts include follicle and corpus luteum cysts.

Follicle cyst: During a woman's menstrual cycle, an egg grows in a sac called a follicle. This sac is located inside the ovaries. In most cases, this follicle or sac breaks open and releases an egg. But if the follicle doesn't break open, the fluid inside the follicle can form a cyst on the ovary.

Correspondence

Dr. Esha Tyagi
PG. Scholars, Department of
Materia Medica, Bharati
Vidyapeeth (Deemed to be)
University, Homoeopathic
Medical College & Hospital,
Pune, Maharashtra, India

Corpus luteum cysts: Follicle sacs typically dissolve after releasing an egg. But if the sac doesn't dissolve and the opening of the follicle seals, additional fluid can develop inside the sac, and this accumulation of fluid causes a corpus luteum cyst.

- Other types of ovarian cysts include:
- Dermoid cysts: sac-like growths on the ovaries that can contain hair, fat, and other tissue.
- Cystadenomas: non-cancerous growths that can develop on the outer surface of the ovaries.
- Endometriomas: tissues that normally grow inside the uterus can develop outside the uterus and attach to the ovaries, resulting in a cyst.

Some women develop a condition called polycystic ovary syndrome. This condition means the ovaries contain a large number of small cysts. It can cause the ovaries to enlarge. If left untreated, polycystic ovaries can cause infertility [6].

Case Report

A 52 year old female of height 161cm and weight 87 kg with clinical history of irregular menses for 8 months reported to the out patient department of Materia Medica on 2.5.17. Her duration of cycle was 30-45 days with metrorrhagia. She also having complained of constipation for 6 months since irregular menses along with big size clots with dark colour. She also complains of aching pain in lumbar region during menses along with sharp stitching pain in lower abdomen.

The patient was overweight according to her height since 1.5 years. The patient was housewife and menopause bearing women. She took allopathic medicines for 1 month without any improvement in bleeding along with this allopathic doctors advice hysterectomy to which patient was not in favour of.

On examination she was obese, with body mass index of 33.56. She also had nabothian cyst in cervix.

Investigation revealed uterus measures 87.1 x 47.3 x 50.7mm along with left ovarian cyst of 29.1 x 27 mm with nabothian cyst in cervix. TSH levels were normal.

Past History: History of pneumonia in 1973

Family History: Family history revealed diabetes, heart attack and cancer of liver in father and rheumatoid arthritis in mother.

Physical Generals

The patient was average looking in height and was fat. She was vegetarian, thermally she was hot. Her appetite was good. She had thirst for large quantity at a time. Bowel movements were irregular, passes stool every 2 or 3days which was hard in consistency. Further she was stressed out because of her diseased condition as there was sever exhausted and tired also it was found that she easily gets irritate.

Investigations revealed pelvic sonography done on 27.4.17 ovarian cyst [figure 1], last menstrual period 24.3.17 (before that taking allopathic medicine for 1 month to stop the excessive bleeding and then she could not find any relief so she stopped taking those medicines)

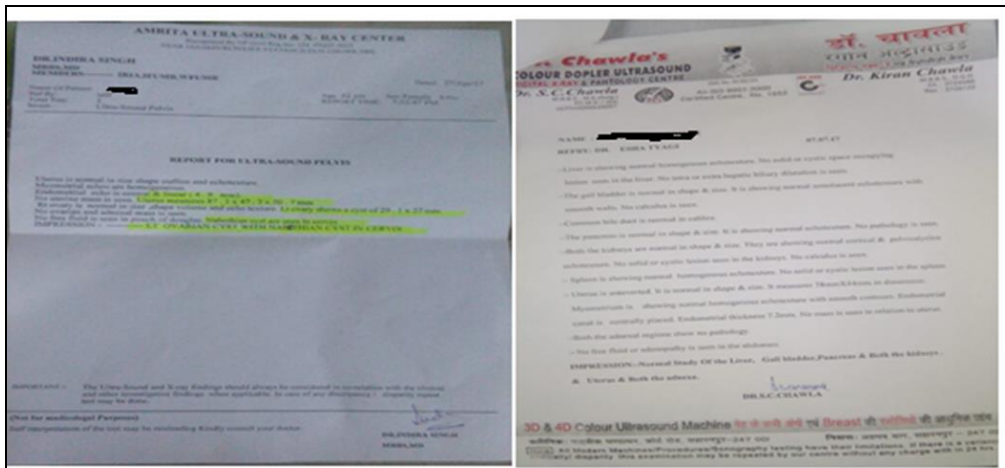
First Prescription

Lachesis mutus 200 single dose followed by sac lac B.D. was given for 1 week. She was advised to take seasonal fruits. This case is followed up to 3 months, as per the follow up table [Table]

Basis of Prescription

Table 1: Follow up chart

Date	Main symptom	Laboratory finding	Medicine Prescribed
2. 5.17	Stitching pain in the left side of iliac region; sever bleeding with dark clots; constipation; backache.	USG: Uterus measure 87.1 x 43.3 x 50.7 mm Left ovarian cyst 29.1 x 27 mm with Nabothian cyst in cervix.	Lachesis mutus 200 x 1 DOSE Sac lac 2pills x BD
8. 5.17	Stitching pain in iliac region still persist; severe bleeding slight better; constipation still persist; backache.	-	Sac lac 2pills x BD
17.5.17	Stitching pain in iliac region still persist; severe bleeding better than before; constipation slight better, backache.	-	Sac lac 2pills x BD
25.5.17	Stitching pain in iliac region slight better; no bleeding; constipation better, backache.	-	Sac lac 2pills x BD
3.6.17	Stitching pain in iliac region better; no bleeding ;no constipation; backache.	-	Sac lac 2pills x BD
12.6.17	Stitching pain in iliac region much better; no bleeding; no constipation; backache.	-	Lachesis mutus 200 x 1 DOSE Sac lac 2pills x BD
21.6.17	No stitching pain in iliac region; no bleeding; no constipation; backache slight better.	-	Sac lac 2pills x BD
30.6.17	No symptoms	-	Sac lac 2pills x BD
7.7.17	No symptoms	USG: Normal scan; no impression of any ovarian cyst ; nabothian cyst ; uterus measures 78mm x 44mm in dimension.	Sac lac 2pills x BD
21.7.17	No symptoms	Normal	Sac lac 2pills x BD



Before Treatment

After Treatment

Fig 1: Reports

Fig 2: Reperforation Chart

Discussion

In present study patient has shown guiding symptom of lachesis mutus was cured by 200 potency, the duration of treatment was of 3 months. From the result and outcome as detailed in (Table) and (Figure1) it could be demonstrated with authenticated evidences that specific homoeopathic remedy, if selected on the basis of totality of symptoms can yield spectacular success in removing ovarian cyst. The USG images of the respective patient have been provided showing the status before the beginning of homeopathic drug administration and also after the treatment was complete (Figure1)

In conclusion, the results of the present study would indicate that proper selection of the homeopathic remedy matching the totality of symptoms can remove cysts from the ovary without any surgical intervention; this can serve as an essential option, in those patients where surgery is undesirable. This can curtail cost of treatment for the economically under-privileged section of the people as well, particularly residing in remote areas where medical amenities and infra-structural facilities for doing surgery are by and large are still unavailable.

Conclusion

From above observation it is concluded that constitutional remedy on the basis of totality of symptoms is effective in

the management of ovarian cyst.

Acknowledgement

Prof. Dr. Arun. B. Jadhav, Principal, Bharati Vidyapeeth (deemed to be) University Homoeopathic Medical College &Hospital, Pune, India.

References

1. Hassan S, Abduljabbar MD, FRCSC Yasir A, Bukhari MB BCH, Estabrq G, Al Hachim MB BCH *et al.* Review of 244 cases of ovarian cysts, Saudi Medical Journal, 2015.
2. By Christian Nordqvist. Everything you need to know about ovarian cysts, medical news today, 2017.
3. Debarshi Das1, Saiful Haque, Asmita Samadder, Saroj Kumar, Anisur Rahman Khuda-Bukhsh. Everything you need to know about ovarian cysts, Journal of Integrative Medicine & Therapy, 2016.
4. Shannon M Grabosch. MD; Chief Editor: Nicole W Karjane, MD (Dec 20, 2018) How common are ovarian cysts in the US? Medscape, 2016.
5. Ovarian Cysts, FAQ075 edn., American College of Obstetricians and Gynecologists. 2017.
6. Alana Biggers. MD, MPH Ovarian Cysts, healthline, 2017.