



International Journal of Homoeopathic Sciences

E-ISSN: 2616-4493

P-ISSN: 2616-4485

www.homoeopathicjournal.com

IJHS 2023; 7(2): 237-242

Received: 09-03-2023

Accepted: 11-04-2023

Dr. Swapan Sarkar

Lecturer, Department of
Homoeopathic Materia Medica,
Bengal Homoeopathic Medical
College and Hospital, West
Bengal, India

Dr. Subhashis Pramanik

Lecturer, Department of Case
taking and Repertory, Bengal
Homoeopathic Medical College
and Hospital, West Bengal,
India

Dr. Ashish Sarkar

Independent Researcher, Mahesh
Bhattacharya Homoeopathic
Medical College and Hospital,
West Bengal, India

Dr. Siddhartha Pal

M.D. (Hom.), J.R.F. (H), Dr.
Anjali Chatterjee Regional
Research Institute, Kolkata,
West Bengal, India

Dr. Rahitosh Ghosh

B.H.M.S, Independent
Researcher

Corresponding Author:

Dr. Swapan Sarkar

Lecturer, Department of
Homoeopathic Materia Medica,
Bengal Homoeopathic Medical
College and Hospital, West
Bengal, India

Role of individualized homoeopathic medicines in the treatment of chronic eczema: A case report

Dr. Swapan Sarkar, Dr. Subhashis Pramanik, Dr. Ashish Sarkar, Dr. Siddhartha Pal and Dr. Rahitosh Ghosh

DOI: <https://doi.org/10.33545/26164485.2023.v7.i2d.835>

Abstract

A male patient aged 53 years, married, lived in Howrah, came to me with Eczema over whole body, specially presented with thickened, hyperpigmented, parchment like plaque with raised skin markings over both hands particularly over back of hands also over the bend of elbows and ulnar surface of forearms with white scaling occasionally after scratching for last 2 years. He was after considering the totality of symptoms and miasmatic background of the case and repertorization with Kent's Repertory with help of Zomeo elite software and final consultation with the material medica Arsenicum album medicine was selected in fifty millesimal potency. The patient was improved well after the treatment. In Homoeopathy we treat the patient as a whole, on the basis of individualization and it is the only basis of treatment to cure a patient in Homoeopathy. This case report showing an efficacy of homoeopathic medicine in a case of eczema.

Keywords: Chronic eczema, Arsenicum album, L.M. Potency, Individualization, Repertory, Homoeopathy

Introduction

Eczema is a relapsing inflammatory skin disease which synonymously used with atopic dermatitis (most common type of dermatitis) and which is characterised by itching, scaling, oozing, vesicle due to impaired barrier function^[1]. Eczema is diagnosed clinically on the basis of the patient's presenting symptoms which are atopic, seborrheic, dyshidrotic, allergic contact, Dermatitis herpetiformis etc.^[2,3]. Social avoidance due to deprived sleep and itching is the most common adverse effect of eczema^[4]. Severity of eczema depend on po-scored index which characterised by erythema, excoriation, oozing, oedema, lichenification^[4,5]. The management of eczema primarily comprises avoiding contact with irritants includes avoid cosmetic, avoid scratching, avoid synthetic cloths, avoid some allergen food substances^[1,6]. In conventional medicine, topical steroids are used, but relapses are very common but in homoeopathy has a positive role in treatment of eczema permanently^[7].

According to homoeopathic principles, suppressed eruptions always lead to deeper diseases; therefore, such eruptions should be treated with homoeopathic individualized medicine. Homoeopathy treats the patient as a whole not the disease. On the basis of totality of symptoms and cardinal principal of homoeopathy, individualised homoeopathic remedy can permanently eradicate the symptoms as whole. There are many medicines in the homoeopathic repertory and material medica for the treatment of eczema such as Arsenicum album, Sulphur, Graphites, Sepia, Tellurium, Mezereum, Rhus Toxicodendron, Dulcamara etc. This case report shows homoeopathic medicine Arsenicum album as effective in eczema.

Case Report

A male patient aged 53 years, married, lived in Howrah, presented with dry eruptions over whole body with itching and burning > by external heat. Eruptions were more on both the hands specially over the bend of elbows and ulnar surface of forearms. The skin was dry, hard, thick, black, smooth, leather like (Parchment like) with white scaling after scratching. He was suffering from 6-7 years and there was a history of suppressed skin eruption previously by the application of Allopathic ointment. But for the last 2 years patient was suffering more with the above complaints. Patient was examined and following characteristics are found.

History of present complaint

In this case, the onset and progress of his complaints were gradual first on the dorsum of both hands then bend of both elbows were affected. Right hand was more affected. No history of exposure to irritant/chemical agents. The patient was previously treated by a skin specialist for this illness. This was diagnosed as a case of chronic eczema. But the modern medicine could not provide him a cure of the condition. After 3 months of treatment by modern medicine under dermatologist patient came to us for homoeopathic treatment.

Past History

1. H/O – Suppressed skin eruption.
2. He was suffered by malaria at childhood.
3. Measles in childhood.

Family History

1. Eczema & gastric ulcer – paternal side.
2. Diabetes – maternal side.

Personal History

History of regular smoking.

Occupation

He working in an iron factory.

Generalities**Physical general**

- Appearance - tall, lean, thin, emaciated & dark complexion. He was very neat & clean.
- Appetite - moderate.
- Thirst - profuse.
- Desires - sweets, egg, fish, warm food.
- Aversion - sour.
- Intolerance - bitter.
- Stool - irregular, occasional loose stool.
- Thermal reaction - chilly patient.
- Sweat - profuse, cold specially on both hands.

Mental General

- Irritable, anxiety, fear about his suffering
- Become restlessness at night on bed, due to more itching,
- Fastidious.

Clinical findings**General Examination**

Built - The patient was tall, thin and dark complexioned.

Pallor - Mild.

Blood Pressure - 110/70 mmHg.

Pulse Rate - 74 beats/min.

Respiratory Rate - 17/min.

Local examination

The skin of the both hands were thickened, hyperpigmented parchment like with raised skin markings with white scaling of scratching mark and no discharges from there.

Diagnosis: It was a case of chronic atopic dermatitis (eczema).

Analysis and evaluation of symptoms**Mental general symptoms**

- The patient was anxious and fear about his sufferings.
- Very much restlessness.
- He was fastidious.

Physical general symptoms

- Desire for sweets, egg, fish, warm foods.
- Aversion to sour.
- Intolerance to egg.
- Stool loose occasionally.
- Patient was thermally chilly.
- Sweats profusely
- Patient had profuse thirst.

Particular symptoms

- Dark, thickened, hyperpigmented parchment like eruptions with raised skin markings over dorsal surface of both hands & bend of both elbows.
- Intense itching with scaling after scratching.

Repertorial totality

The following rubrics were selected for repertorization from “Repertory of the Homeopathic Materia Medica” by Dr. J. T. Kent because the case presented with characteristics mental general as well as physical generals^[8] [Fig-1].

- Mind, fear, sufferings.
- Mind, restlessness, nervousness.
- Mind, fastidious.
- Stomach, desire, sweets.
- Stomach, desire, eggs.
- Stomach, desire, warm food.
- Generalities, food, eggs agg.
- Generalities, cold, in general agg.
- Perspiration, profuse.
- Stomach, thirst, extreme
- Skin, eruptions, eczema
- Skin, dry
- Skin, thick, skin becomes, after scratching
- Skin, hard, parchment, like.

Analysis of the case and selection of medicine with potency

Here, we adopted Dr. Kent’s method as the patient displayed characteristic mental as well as physical general symptoms^[9]. Considering the above symptomatology and miasmatic background of the case, the medicine Arsenicum album in LM potency was selected and it was further consulted with various Homoeopathic Material Medical^[10-12].

| Remedy | Ars | Calc | Ipe | BhusT | Si | Chin | Sulph | Sap | Dulc | Mali-C | Ily | Ferr | Merc | Carbo |
|--|-----|------|-----|-------|----|------|-------|-----|------|--------|-----|------|------|-------|
| Totally | 28 | 23 | 23 | 21 | 20 | 19 | 19 | 18 | 17 | 17 | 16 | 16 | 16 | 15 |
| Symptoms Covered | 11 | 9 | 9 | 9 | 8 | 7 | 7 | 8 | 8 | 8 | 8 | 7 | 7 | 7 |
| Kingdom | ↓ | ↓ | ↓ | ↓ | ↓ | ↓ | ↓ | ↓ | ↓ | ↓ | ↓ | ↓ | ↓ | ↓ |
| [Kent] [Mind]FEAR (SEE ANXIETY):Suffering, of: (7) | | 1 | | | | | | | | | 1 | | | |
| [Kent] [Mind]RESTLESSNESS, NERVOUSNESS: (249) | 3 | 3 | 3 | 3 | 3 | 2 | 3 | 3 | 2 | 2 | 1 | 3 | 3 | 2 |
| [Kent] [Mind]FASTIDIOUS: (2) | 2 | | | | | | | | | | | | | |
| [Kent] [Stomach]DESIRES Sweets: (36) | 1 | 2 | 3 | 2 | | 3 | 3 | 2 | | 2 | 2 | | 1 | 2 |
| [Kent] [Stomach]DESIRES Eggs: (4) | | 2 | | | | | | | | | | | | |
| [Kent] [Stomach]DESIRES Warm Food: (11) | 3 | | 2 | | 1 | | | | | | | 2 | | |
| [Kent] [Generalities]FOOD Eggs Agg: (4) | | | | | | | | | | | | 2 | | |
| [Kent] [Generalities]COLD In general egg: (134) | 3 | 3 | 3 | 3 | 3 | 3 | 2 | 3 | 3 | 3 | 2 | 2 | 2 | 2 |
| [Kent] [Perspiration]PROFUSE: (133) | 3 | 3 | 3 | 2 | 3 | 3 | 2 | 3 | 1 | 3 | 3 | 3 | 3 | 3 |
| [Kent] [Stomach]THIRST Extreme: (187) | 3 | 3 | 2 | 2 | 3 | 3 | 3 | 2 | 2 | 2 | 3 | 2 | 3 | 2 |

Fig 1: Kent because the case presented with characteristics mental general as well as physical generals

Follow up and outcomes

| Date of visit | Follow up | Prescription |
|---------------|---|----------------------------|
| 23/03/21 | Blackening of hands reducing | Ars.alb -0/4, Ars.alb -0/5 |
| 20/04/21 | Skin of back of elbow goes to normal but itching remains. | Ars.alb -0/6; 0/7 |
| 18/05/21 | Going improvement | Ars.alb -0/8; 0/9 |
| 15/06/21 | Patient is better | Ars.alb -0/10; 0/11 |
| 07/12/21 | Eruption on hands starts to become smooth, skin becoming normal in both hands | Ars.alb -0/12; 0/13 |
| 25/01/22 | Going improvement. | Ars.alb -0/14 |
| 15/02/22 | No itching is there and skin going to more normal. | Ars.alb -0/15 |
| 22/02/22 | Improvement | Ars.alb -0/16 |
| 15/03/22 | Improvement | Ars.alb -0/17 |
| 05/04/22 | Improvement | Ars.alb -0/18 |
| 14/02/23 | Cured with normal appearance of the skin. | Ars.alb -0/19 |

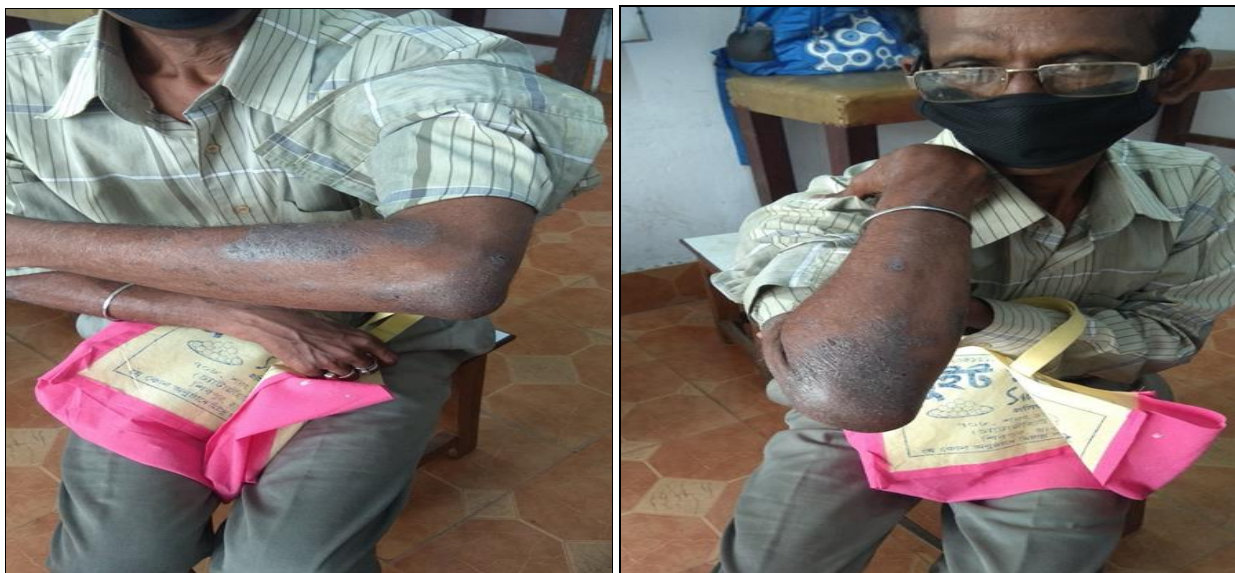

Fig 2A: First visit

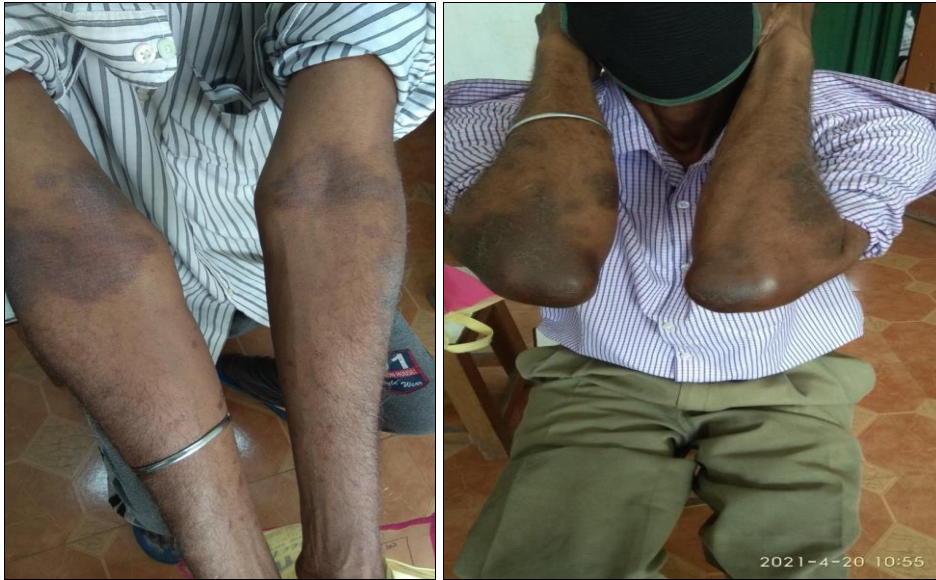

Fig 2B: Second visit

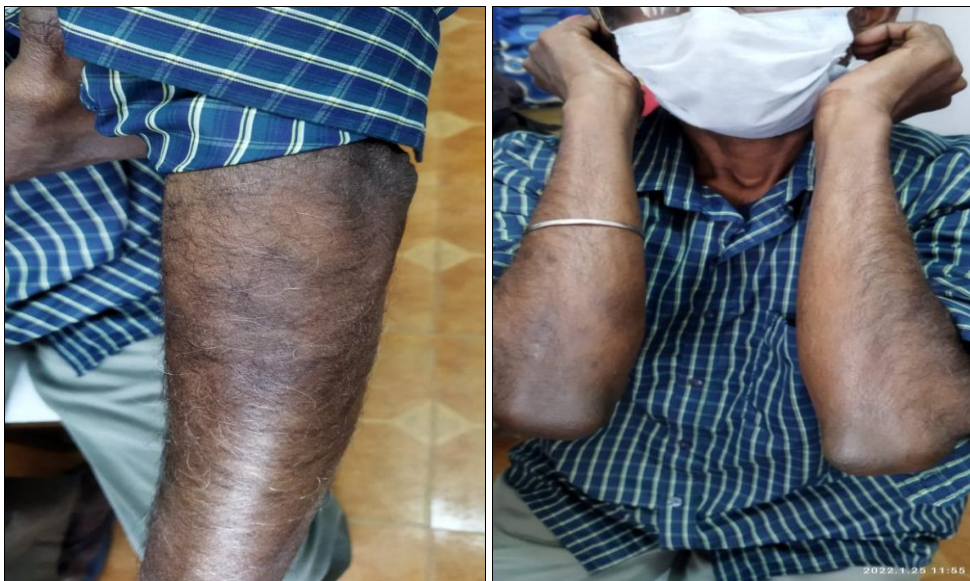

Fig 2C: Before final visit (10th visit)

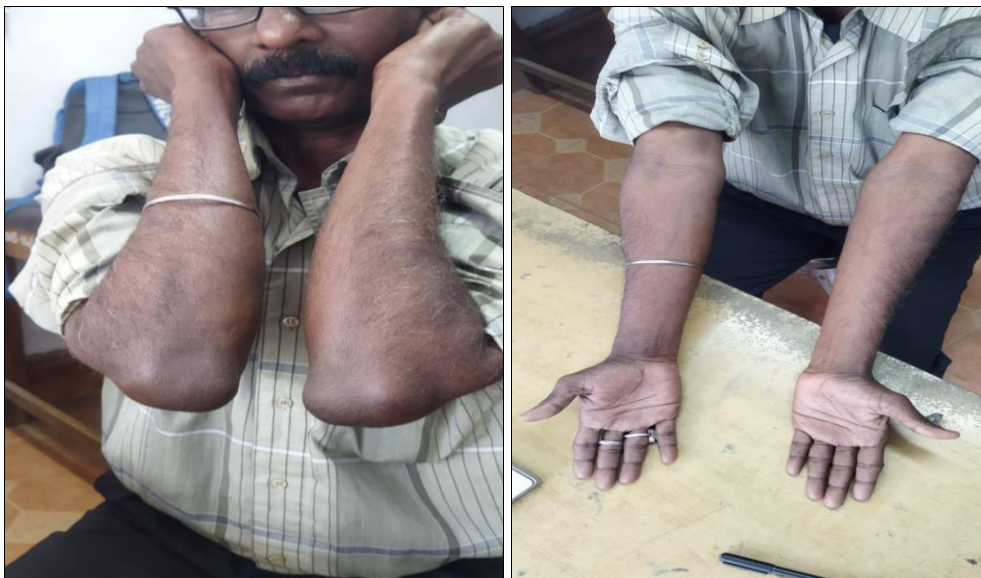

Fig 2D: Final visit

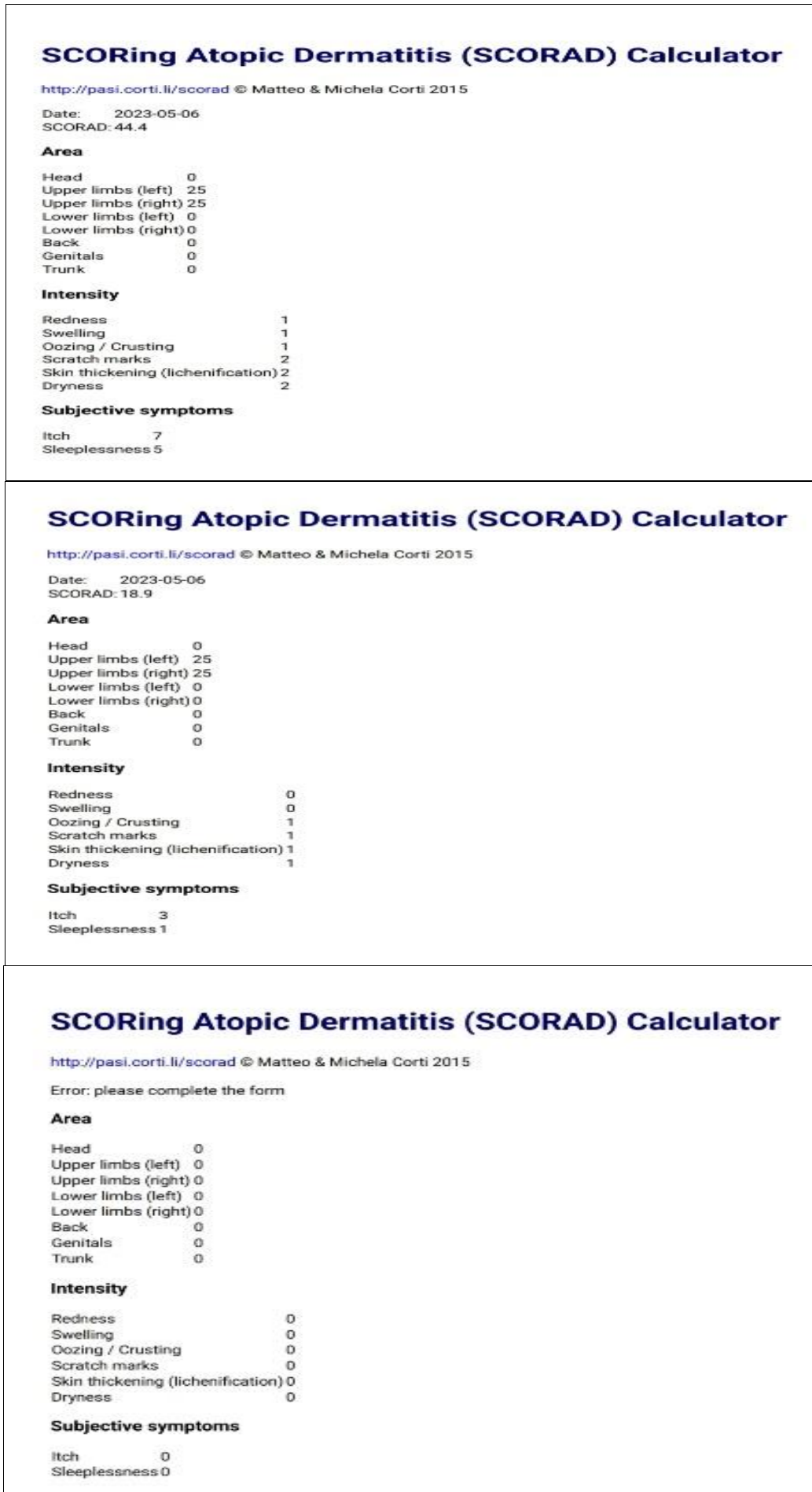


Fig 3: Comparative SCORAD (SCORing Atopic DERmatitis) score at first visit, third visit and final visit by using SCORAD calculator (0.9.0).

Conclusion

This case shows the efficacy of individualized homoeopathic medicines in the case of eczema. No local application was used and patient is well improved only by the internal application of suitable homoeopathic medicine. In homoeopathy, on the basis of the patient's presenting symptoms and on referring to the *Materia Medica*, after systematic repertorisation of the case when a suitable constitutional medicine is given, only then we can see or perceive the beauty of Homoeopathy.

Declaration of patient consent: The authors certify that they have obtained all appropriate patient consent.

Financial support and sponsorship: Nil.

Conflicts of interest: There are no conflicts of interest.

References

1. Khanna Neena, Illustrated synopsis of dermatology and sexually transmitted diseases, 6th edition, New Delhi, Elsevier; c2020.
2. Anthony Fauci S, Dennis Kasper L, Stephen Hauser L, *et al.* Harrison's Principles of Internal Medicine. 20th Edition, The McGraw-Hill Companies, Inc., New York. 2015;2:2692-2698.
3. Marks Ronald, Roxburgh's common skin diseases, International Student's edition, Chennai, Arnold publishers; c2003.
4. Brian S Kim, Atopic dermatitis; c2023 Feb 13. Available from: <https://www.emedicine.medscape.com/article/1049085>.
5. Hall BJ, Hall JC, editors. Sauer's manual of skin diseases. Lippincott Williams & Wilkins; c2010.
6. Khanna Neena, Illustrated synopsis of dermatology and sexually transmitted diseases, 6th edition, New Delhi, Elsevier; c2020.
7. Patil MK. The role of homoeopathy in treating skin disease of the elderly: A case report. *J Intgr Stand Homoeopathy*. 2020;3(4):95-9.
8. Kent JT. Repertory of the Homoeopathic *Materia Medica*, sixth American edition, 8th impression, New Delhi, B. Jain Publishers; c2019.
9. Kent JT. (James Tyler), Lectures on homoeopathic philosophy, B Jain Publishers Pvt. Ltd., New Delhi, reprint edition; c2017.
10. Hahnemann S. *Organon of Medicine*, translated from the 5th edition, with an appendix by R.E. Dudgeon with additions and alterations as per 6th edition translated by William Boericke, and Introduction by James Krauss. New Delhi. B. Jain Publishers; c2013.
11. Kent JT. Lectures on homoeopathic *materia medica*: together with Kent's "New remedies" incorporated and arranged in one alphabetical order. Repr ed. New Delhi: Jain; c1992.
12. Boericke W, *Pocket Manual of Homoeopathic Materia medica with Indian medicine and repertory*. New Delhi. Indian Books and periodicals Publishers; c2011 Jul.

Creative Commons (CC) License

This is an open access journal, and articles are distributed under the terms of the Creative Commons Attribution-Non Commercial-Share Alike 4.0 International (CC BY-NC-SA 4.0) License, which allows others to remix, tweak, and build upon the work non-commercially, as long as appropriate credit is given and the new creations are licensed under the identical terms.

How to Cite This Article

Sarkar S, Pramanik S, Sarkar A, Pal S, Ghosh R. Role of individualized homoeopathic medicines in the treatment of chronic eczema: A case report. *International Journal of Homoeopathic Sciences*. 2023;7(2):237-242.