



International Journal of Homoeopathic Sciences

E-ISSN: 2616-4493
P-ISSN: 2616-4485
www.homoeopathicjournal.com
IJHS 2023; 7(2): 350-352
Received: 11-02-2023
Accepted: 14-03-2023

Dr. Ambala Sriharitha
Associate Professor,
Department of Homoeopathic
Materia Medica, MNR
Homoeopathic Medical
College, Sangareddy,
Telangana, India

Dr. Silvia Sunderraj
Assistant Professor,
Department of Homoeopathic
Materia Medica, MNR
Homoeopathic Medical
College, Sangareddy,
Telangana, India

Corresponding Author:
Dr. Ambala Sriharitha
Associate Professor,
Department of Homoeopathic
Materia Medica, MNR
Homoeopathic Medical
College, Sangareddy,
Telangana, India

Utility of homoeopathic drug phosphorus in management of alopecia areata: An evidence based case report

Dr. Ambala Sriharitha and Dr. Silvia Sunderraj

DOI: <https://doi.org/10.33545/26164485.2023.v7.i2f.851>

Abstract

Alopecia areata, a common cosmetic issue in human beings of this contemporary world. It is a sudden non scarring hair loss. It may progress from patchy loss to complete hair-loss. It is seen in any age, and may have recurrent episodes. It has life time risk of nearly 2% worldwide. Often Alopecia areata co-occurs with psychiatric disorders and other autoimmune diseases, can have serious impacts on psychological well-being and quality of life of patients. This article contains Homoeopathic management of a case of Alopecia Areata.

Keywords: Alopecia Areata, constitutional treatment, phosphorus

Introduction

At any given point of time, approximately 0.2% of population has Alopecia Areata, and approximately 1.7% of population experiences an episode of Alopecia Areata during their life time. A variety of environmental factors like infection, drugs, trauma, stress, physical and psychological insults triggers Alopecia Areata.

Alopecia Areata typically presents with a patch of hair loss, may be single or multiple, or may coalesce. There may be nail changes in Alopecia Areata, they may show fine fitting, mottled Lunula, Trachyonychia, or Onychomadesis.

Differential Diagnosis include-

Tenia Capitis - Obvious inflammation (e.g. scaling, pustules) in association with patchy hair loss.

Trichotillomania- Hair loss is not complete, broken hairs are usually firmly anchored in the scalp.

Triangular Alopecia: It is congenital, may be present from childhood as a focal patch of hair-loss or just behind fronto-temporal hairline. This type of alopecia occurs within families as para-dominant trait.

Thyroid abnormalities, autoimmune diseases, Syphilis (Alopecia Areolaris) and early scarring Alopecia are some Differential Diagnosis, biopsy may be needed for evaluation.

Case report

On 10th July 2022, a 22-year-old female came with complaints of hair loss in single spot on scalp since 1 month.

History of presenting complaints: Patient presented with hair loss in single spot-on scalp since 1 month which was gradually increasing. Moderate Dandruff is seen. No itching of scalp.

Past History: Nothing specific

Family History: Father- K/C/O DM and HTN since 7 years. Brother- also has c/o hair fall.

OBG History: Monthly regular menstrual cycle.

Mental generals: Friendly nature, mingles easily with everybody.

Physical generals: Diet-Non veg. Appetite-Normal. Thirst-Increased. Desire-Chocolates. Bowels-once per day, satisfactory. Micturition- Normal. Thermals- Chilly patient

General survey: Patient was well oriented, alert and co-operative. Clinically no anaemia, cyanosis, oedema, jaundice or clubbing.

Provisional Diagnosis: Alopecia areata, with dandruff.

Analysis and evaluation of the case: After analysis of symptoms of the case, the physical generals, mental generals and the particular symptoms are taken for the formation of totality.

1. Increased thirst
2. Desire for chocolates
3. Friendly nature
4. Hair loss in spots

5. Dandruff

Repertorial analysis

Synthesis repertory was used for the repertorisation. In reportorial result, the following remedies came up, Phosphorus, Ars Alb, Calc Carb, Kali Sulph, Lycopodium etc. Maximum symptoms were covered by phosphorus. It was again cross verified with Materia Medica.

Table 1: Symptoms and Rubric

Symptoms	Rubrics
Increased thirst	Stomach-thirst
Desire for chocolates	Generals-Food and drinks-Chocolate-Desire
Friendly nature	Mind-Affectionate
Hair loss in spots	Head-Hair-baldness-patches
Dandruff	Head-Dandruff

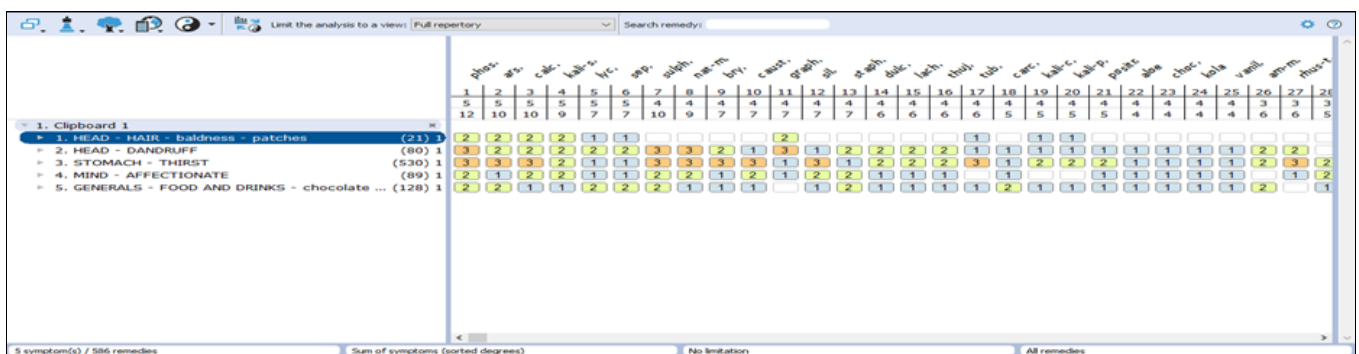


Fig 1: Repertorisation chart

Remedy with potency selection and administration

Phosphorus 200 3 doses was prescribed on 11th July 2022. Patient was instructed to take one dose each day for 3 days, early morning empty stomach.

Follow up

Table 2: Follow up

Date	Observation	Remedy
25-07-22	Dandruff reduced Hairfall persisted	Phosphorus 200 1 dose
25-08-2022	Hair started growing in the bald patch	Pl for 1 month
25-09-22	Bald patch completely gone	No further treatment

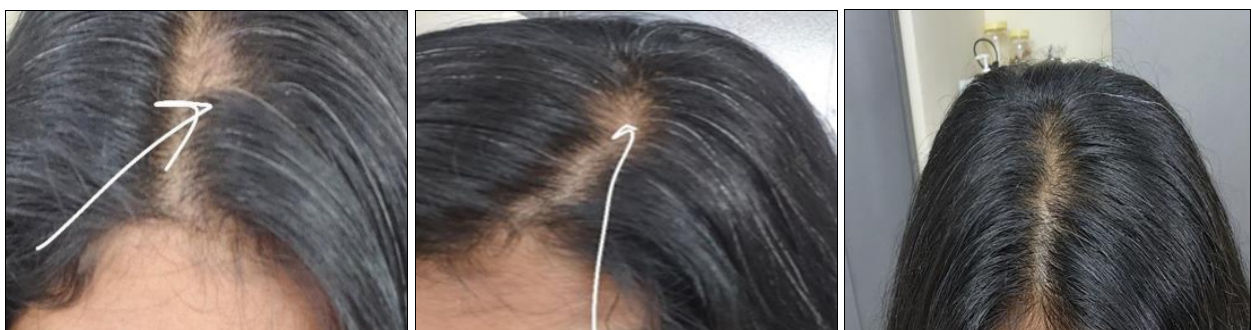


Fig 2: Before and after treatment

Discussion

The case have limited symptomatology, yet deep acting constitutional remedy phosphorus was selected, based on available data. Phosphorus is a prominent remedy in alopecia. According to Boericke's Materia Medica, Phosphorus has symptom- dandruff, falling out of hair in bunches. In Murphy's Materia Medica, Phosphorus has dandruff, falling of hair in bunches, in spots. Lilienthel S. in his text book of Homoeopathic Therapeutics gives in phosphorus the symptoms; Round patches on scalp

completely deprived of hair; falling off of the hair in large bundles on the forehead and on the sides above the ears; the roots of the hair seem to be dry; the denuded scalp looks clear, white and smooth; dandruff copious, falls out in clouds. As the Phosphorus having affinity to alopecia, and covering constitutional symptoms like being affectionate, thirsty, desire for chocolates, it was prescribed for the patient and she showed improvement in 3 months. Case was followed till date with no recurrence of symptoms.

Conclusion

Homoeopathy offers quick and safer treatment for Alopecia areata. It prevent recurrence if treated constitutionally.

Conflict of Interest

Not available

Financial Support

Not available

References:

1. Dr. Boericke W. New manual of Homoeopathic Materia Medica, 3rd revised and augmented edition, B.Jain publishers, Pvt. Ltd, New Delhi.
2. Dr. Frederik Schroyens. Synthesis, Reperotrium Homoeopathicum Syntheticum, Edition 9.1, B. Jain publishers (P) LTD. New Delhi.
3. Dr. Lilienthal SMD. Homoeopathic Therapeutics, the classical therapeutic hints, 1st Edition, B. Jain publishers (P) LTD. New Delhi.
4. Dr. Robin Murphy. Lotus Materia Medica, 3rd revised edition, B. Jain publishers (p) LTD. New Delhi.
5. Wolff K, Goldsmith L. Fitzpatrick's Dermatology, 7th Edition, 2 Volumes set, published by Mc. Graw-Hill Education, Newyork; c2008.
6. Senna M, Ko J, Tosti A, Edson-Heredia E, Fenske DC, Ellinwood AK, *et al.* Alopecia Areata treatment patterns, healthcare resource utilization, and comorbidities in the us population using insurance Claims. *Adv Ther.* 2021 Sep;38(9):4646-4658. DOI: 10.1007/s12325-021-01845-0. EPUB 2021 Jul 22. PMID: 34292518; PMCID: PMC8408067.
7. Pratt CH, King LE Jr, Messenger AG, Christiano AM, Sundberg JP. Alopecia areata. *Nat Rev Dis Primers.* 2017 Mar 16;3:17011. DOI: 10.1038/nrdp.2017.11. PMID: 28300084; PMCID: PMC5573125.
8. Villasante Fricke AC, Miteva M. Epidemiology and burden of alopecia areata: a systematic review. *Clin Cosmet Investig Dermatol.* 2015 Jul 24;8:397-403. DOI: 10.2147/CCID.S53985. PMID: 26244028; PMCID: PMC4521674.

How to Cite This Article

Sriharitha A, Sunderraj S. Utility of homoeopathic drug phosphorus in management of alopecia areata: An evidence based case report. *International Journal of Homoeopathic Sciences.* 2023;7(2):350-352.

Creative Commons (CC) License

This is an open access journal, and articles are distributed under the terms of the Creative Commons Attribution-Non Commercial-Share Alike 4.0 International (CC BY-NC-SA 4.0) License, which allows others to remix, tweak, and build upon the work non-commercially, as long as appropriate credit is given and the new creations are licensed under the identical terms.