



International Journal of Homoeopathic Sciences

E-ISSN: 2616-4493

P-ISSN: 2616-4485

www.homoeopathicjournal.com

IJHS 2023; 7(2): 515-518

Received: 13-03-2023

Accepted: 22-04-2023

Dr. Neha Mahawer

Assistant Professor,

Department of Homoeopathic
Materia Medica, Nootan
Homoeopathic Medical College
and Hospital, Constituted of
Sankalchand Patel University
in Visnagar, Mehsana,
Gujarat, India

Dr. Anjana Kumari

Assistant Professor,

Department of Organon of
Medicine, Nootan
Homoeopathic Medical College
and Hospital Constituted of
Sankalchand Patel University
in Visnagar, Mehsana, and
Gujarat, India

Manish Singh

Assistant Professor,

Department of Anatomy,
Nootan Homoeopathic Medical
College and Hospital
Constituted of Sankalchand
Patel University in Visnagar,
Mehsana, Gujarat, India

Dr. Bhupendra Arya

Assistant Professor,

Department of Homoeopathic
Pharmacy, Nootan
Homoeopathic Medical College
and Hospital Constituted of
Sankalchand Patel University
in Visnagar, Mehsana, and
Gujarat, India

Corresponding Author:

Dr. Neha Mahawer

Assistant Professor,

Department of Homoeopathic
Materia Medica, Nootan
Homoeopathic Medical College
and Hospital, Constituted of
Sankalchand Patel University
in Visnagar, Mehsana,
Gujarat, India

Clinical verification of individualized homoeopathic medicine *mercurius solubilis* in tinea corporis: A case study

Dr. Neha Mahawer, Dr. Anjana Kumari, Manish Singh and Dr. Bhupendra Arya

DOI: <https://doi.org/10.33545/26164485.2023.v7.i2h.877>

Abstract

Tinea corporis is a fungal infection of the body caused by Dermatophytes. Tinea corporis characterised by circinate eruptions, itching, burning, soreness and secondary infections. This case represents a case of Tinea Corporis treated with homoeopathic remedy *Mercurius Solubilis*. A 47 year old male came in our OPD on 14/11/2023 with the complaints of papulovesicular ring shaped eruption on thigh which spread all over body mostly on trunk. Intense itching and burning after scratching itching aggravates by scratching. This patient improved with *Mercurius solubilis* 30, single dose.

Keywords: Tinea corporis, homoeopathy, *Mercurius solubilis*

Introduction

Tinea is also known as 'ringworm' is a superficial mycotic infection. Tinea corporis is a fungal infection of the body caused by Dermatophytes^{1, 2}. Superficial mycotic infections are common throughout the world with prevalence of 20- 25%. The dermatophytes causing tinea corporis belong to genera Trichophyton, Epidermophyton, and Microsporum. *T. rubrum* is most common cause of dermatophytosis and is the most common cause of tinea corporis. There is no sex predominance. Humans may become infected through close contact with an infected individual, an infected animal (domestic dog or cat), contaminated fomites, or contaminated soil^{3, 4}. Tinea corporis characterised by circinate eruptions, itching, burning, soreness and secondary infections². It can occur in either sex or in any age and is bound to have effect on quality of life of patients².

Case profile

47 year old male came in our OPD of Nootan Homeopathic Medical College and Hospital 14/11/2023 with the complaints of papulovesicular ring shaped eruption on thigh which spread all over body mostly on trunk. Intense itching and burning after scratching itching aggravates by scratching.

History of present complaints & treatment history

Patient was apparently well before 5-6 years back, but he gradually started to develop red Coloured maculopapular eruption on thigh which spread on back and chest. Eruptions are itchy which worse in during perspiration. Scratching cause burning and watery fluid discharge and started to spread. Patient took allopathic ointments for few days but got no relief.

Past history

Haemorrhoids at the age of 40 years for this he took allopathic treatment-cured.

Family history: All members healthy with no significant medical history.

Physical generals: The patient has normal appetite. Take meals twice a daily. Intense thirst drinks 5-7 litres of water per day. There was marked desire for sweets. Profuse sweat all over body with yellow staining. Thermal reaction was towards hot.

Mental generals: The Patient was violent anger, using bad language for his colleagues. Fear of darkness. Desires for company. He always wanted someone near him.

5'6", Weight- 72kgs. Other general and systematic examination findings were normal.

Provisional Diagnosis: Tinea Corporis

Clinical findings: Appearance was ectomorphic, Height-

Analysis & Evaluation of Symptoms

Table 1: Analysis & Evaluation of Symptoms

Mental general	Physical general	Particular
Anger, Violent, abusive	Thirsty	Yellow Coating of tongue
Fear of dark	Sweet Desire	Popular vesicular ring shaped eruption on trunk.
Company desire	Profuse Perspiration with yellow stain	Itching <sweating
	Hot Patient	Burning <scratching

Miasmatic analysis of symptoms

Table 2: Miasmatic analysis of symptoms [5, 6, 7, 8, 9]

Symptoms	Psora	Sycosis	Syphilis
Anger violent, abusive	✓		
Fear of dark	✓		
Yellow Coating of tongue	✓		
Desire for sweets	✓		
Popular, ring shape eruption on trunk	✓		
Perspiration profuse with yellow staining	✓		
Itching <sweating	✓	✓	
Thirsty	✓		

Dominant miasm: PSORA

Fundamental miasm: PSORA

Repertorial totality

The following rubrics were selected from RADAR 10.0: [10]

- Mind-Anger-abused; after being
- Mind-fear-dark; of

- Mouth-discoloration-tongue-Yellow
- Generals-food & drink-sweets-Desire
- SKIN-ERUPTIONS-herpetic-circinate
- Perspiration-staining in linen-Yellow
- Skin-itching-perspiration-after
- Stomach-thirst

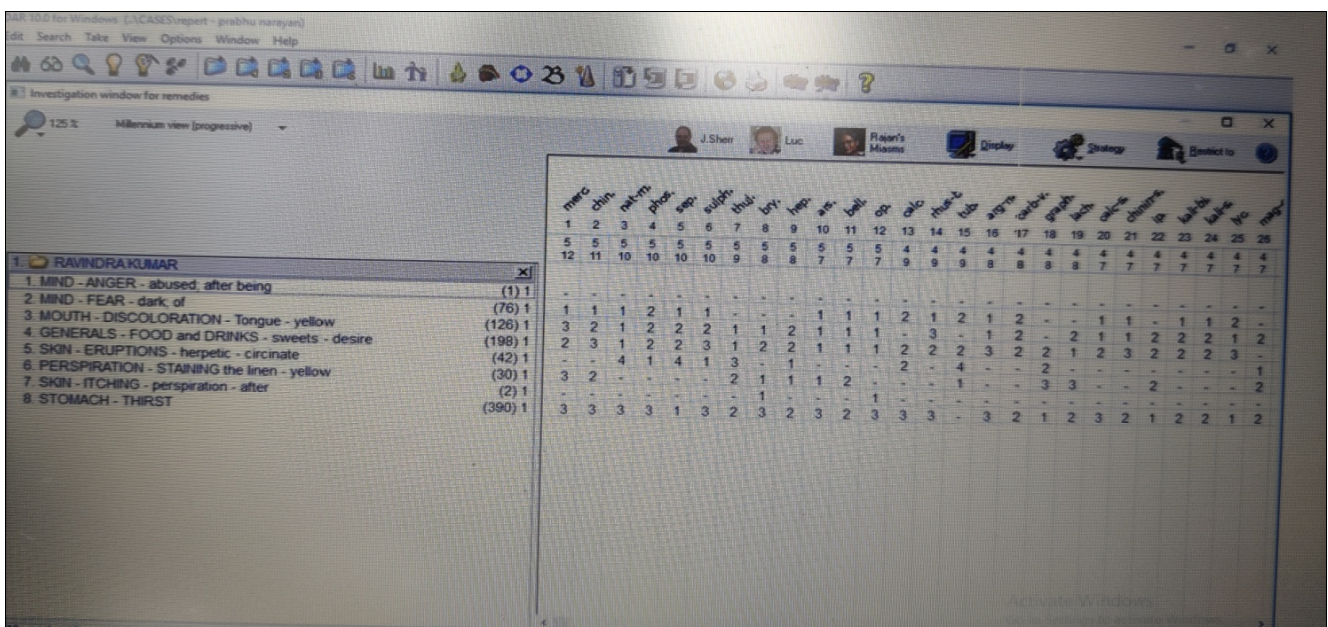


Fig 1: Reperforation of case from Murphy’s Repertory using RADAR software

Prescription

R_x *Mercurius solubilis* 30/1dose, Rubrum30/TDS for 7 days.

Justification of selection of remedy

Mercurius solubilis is selected on the basis of

reperforation and after consulting to Materia medica.

Justification of selection of potency & repetition: 30 potency is selected as per the Susceptibility of patient and intensity of symptoms and single dose was given to avoid unwanted aggravation [11].

Table 1: Follow up

Date	Changes in symptoms	Prescription
21/11/2022	Itching – SQ, eruption slightly reduced, redness slow improved, coating of tongue reduced	Merc sol 30/1 dose Rubrum30/TDS for 10 days.
1/12/2022	Eruptions better, itching and redness slight relieved	Rubrum30/TDS for 14 days
15/12/2022	Eruptions better, itching, redness –SQ No staining in perspiration	Merc sol 30/1 dose Rubrum30/TDS for 10 days
26/12/2022	Itching and eruption better, redness reduced	Phytum1m/1dose Rubrum30/TDS for 14 days
9/1/2023	Eruptions and itching further relieved	Phytum1m/1dose Rubrum30/TDS for 10 days
19/1/2023	Marked improvement in itching and eruption, no redness, tongue clear and moist.	Rubrum30/TDS for 14 days

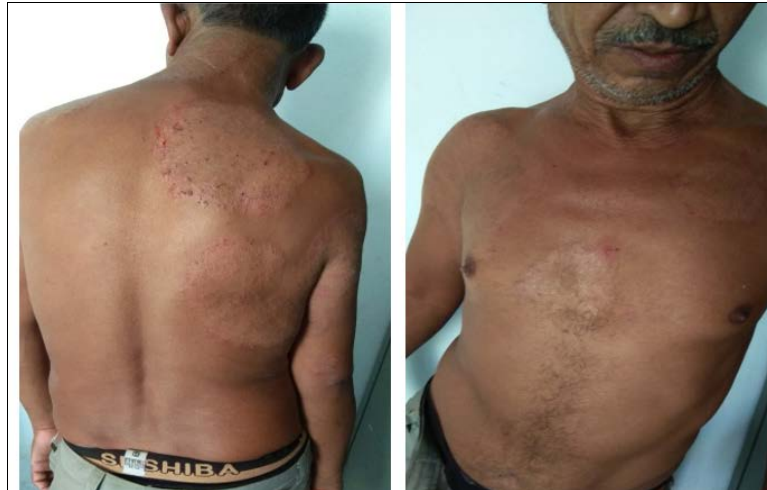

Fig 2: Pre-treatment

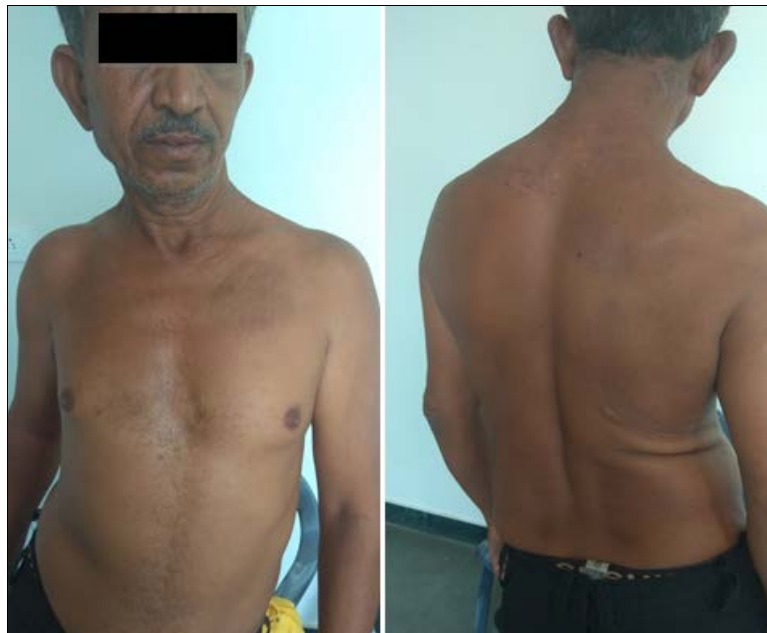

Fig 3: Post-treatment

Conflict of Interest

Not available

Financial Support

Not available

Reference

1. Khanna N. Illustrated synopsis of dermatology and sexually transmitted diseases. 4th ed. New Delhi: Elsevier; c2011.
2. Leshner J. Tinea Corporis: Practice Essentials,

- Background, Pathophysiology [Internet]. Emedicine.medscape.com. 2018 [cited 10 December 2018]. Available from: <https://emedicine.medscape.com/article/1091473-overview#a5>
3. Yee G, Al About AM. Tinea Corporis. [Updated 2022 Apr 30]. In: StatPearls [Internet]. Treasure Island (FL): StatPearls Publishing; 2022 Jan-. Available from: <https://www.ncbi.nlm.nih.gov/books/NBK544360/>
4. Leung AK, Lam JM, Leong KF, Hon KL. Tinea corporis: an updated review. Drugs Context. 2020 Jul

- 20;9:2020-5-6. Doi: 10.7573/dic.2020-5-6. PMID: 32742295; PMCID: PMC7375854.
5. Patel RP. Chronic miasms in homoeopathy and their cure with classification of their rubrics/symptoms in Dr.Kent's repertory (repertory of miasms- psora, sycosis, syphilis. Kerala: Hahnemann Homoeopathic Pharmacy; 1996.
 6. Allen JH. The Chronic Miasms, Psora, Pseudo Psora and Sycosis. New Delhi: B. Jain Publishers Pvt. Ltd.; 2014.
 7. Benerjee SK. Miasmatic prescribing, its philosophy, diagnostic classifications, clinical tips, Miasmatic repertory, Miasmatic weightage of medicines and case illustrations. 2nd extended ed. New Delhi: B Jain Publishers Pvt. Ltd; c2011.
 8. Robert HA. The principles and art of cure by Homoeopathy. 3rd reprint ed. New: B Jain Publishers Pvt. Ltd; c2007.
 9. Hahnemann S. The chronic diseases their peculiar nature and their homoeopathic cure. Low Price Edition. New Delhi: B. Jain Publishers Pvt. Ltd.; c2002
 10. RADAR [computer program]. Version 10.0. London: Archibel Homeopathic software.
 11. Mandal PP, Mandal BA. Textbook of Homoeopathic Pharmacy. 2nd ed. Kolkata: New Central Book Agency(P)Ltd; c2009.

How to Cite This Article

M Neha, K Anjana, S Manish, A Bhupendra. Clinical verification of individualized homoeopathic medicine *mercurius solubilis* in tinea corporis: A case study. International Journal of Homoeopathic Sciences. 2023;7(2):515-518.

Creative Commons (CC) License

This is an open access journal, and articles are distributed under the terms of the Creative Commons Attribution-NonCommercial-ShareAlike 4.0 International (CC BY-NC-SA 4.0) License, which allows others to remix, tweak, and build upon the work non-commercially, as long as appropriate credit is given and the new creations are licensed under the identical terms.