



International Journal of Homoeopathic Sciences

E-ISSN: 2616-4493

P-ISSN: 2616-4485

www.homoeopathicjournal.com

IJHS 2023; 7(4): 187-191

Received: 19-08-2023

Accepted: 23-09-2023

Dr. Kankana Kalra

CHC Cum Mentor, Gurgaon
MG Road Clinic, Dr. Batra's
Positive Health Clinic Pvt.
Ltd., Haryana, India

A case study of homoeopathic treatment for bullous pemphigoid

Dr. Kankana Kalra

DOI: <https://doi.org/10.33545/26164485.2023.v7.i4c.975>

Abstract

Bullous pemphigoid (BP) is a widely increasing autoimmune blistering ailment sometimes accompanied by pruritic urticarial plaques. The prevalence of BP increases as the age of the person increases and it is rarely found in people younger than 50 years of age. The incidence of BP every year is approximately 2.4 and 21.7 new cases per million in the population throughout the world. As per the onset, clinical presentation, and factors responsible for triggering disease different variants of BP include classical BP, no bullous BP, exfoliative erythroderma, and infant or childhood BP. Certain triggering diseases and factors in BP include the following psoriasis/phototherapy-induced BP, lichen planus, and drug-induced BP. The treatment for BP includes locally applied corticosteroids depending upon the patient's severity and clinical features, the dosage may range from moderate to high doses. Unlike such conventional medicines, you may not encounter any side effects since the use of homeopathic medicines is very natural and safe. Homeopathy not only treats the symptoms of the patient but also deals with the root cause of the problem so that the patient gets optimal patient satisfaction. Homeopathy is exceedingly useful in diseases related to immune function since it boosts immunity. In this paper, we encounter such a case of immune dysfunction leading to bullous pemphigoid manifestation in a young individual exhibiting a substantial range of signs and symptoms that point towards the best-suited homeopathic remedy after a very thorough case-taking and case evaluation.

Keywords: Bullous pemphigoid, homeopathy, autoimmune, immune dysfunction, corticosteroids

Introduction

Bullous pemphigoid (BP) is an autoimmune bullous disease that is increasing at a fast pace due to drug-induced occurrence, especially in the elderly. Some rare incidences of BP are reported in children and adolescents. An immune dysfunction manifests itself in a tense blister or several over-urticarial affections mainly on the trunk and extremities often accompanied by severe pruritus.

Some triggering factors and diseases for BP include Psoriasis, Lichen planus, drug-induced, and many more. The differential diagnoses include pemphigus foliaceus, pemphigus herpetiformis, linear IgA bullous dermatosis, eczema, urticarial, prurigo, impetigo, etc.

The different clinical types of BP include classical BP where the lesions are marked in axillary folds, lower abdomen, inguinal areas, and inner parts of the thighs. The nonbullous BP can be a prodromic stage before the incidence of the blistering stage of the disease. The widely seen manifestations include pruritus (100%) with erythematous urticarial skin changes (52.3%), excoriations (22.7%), papules, and nodules (20.5%). Also, the Exfoliative erythroderma, infantile, and childhood BP may be seen to some extent.

The conventional treatment for BP is the use of high-potency locally applied steroids or systemic steroids. Severe complications like secondary infections lead to increased hospitalization rates and incidence of sepsis along with adverse effects of medications have often resulted in mortality in the elderly counterparts.¹

Homeopathy helps a lot in immune dysfunction as it enhances immunity. Compared to conventional steroid treatment that may cause a recurrence of skin affection, homeopathic treatment may offer long-term relief from the disease without frequent relapses and therefore improve the health-related quality of life.

Case Profile

An 11-year-old patient came to Dr Batra's positive health clinic with a bullous pemphigoid eruption on the hands. He also had dermatitis on his fingers/toes for 5 years.

Corresponding Author:

Dr. Kankana Kalra

CHC Cum Mentor, Gurgaon
MG Road Clinic, Dr. Batra's
Positive Health Clinic Pvt.
Ltd., Haryana, India

He had been suffering from asthma for 3 years and used asthalin when exacerbations occurred. He had a cough for a day and a fever for 3 days. He also had yellowish expectoration that aggravated in the morning. There was a presence of vomiting on and off often after eating spongy food and if he ate anything heavy. He feels better by vomiting. For 3 years, he experienced breathlessness after running and other forms of exertion. Breathlessness was also precipitated by changes in weather, cold drinks, and even at night, and it was ameliorated after taking asthalin puff and resting. There was a sensation of burning sometimes after passing stools and aggravated by eating spicy food. The nail of the right hand was infected producing pus discharge with bleeding at times but with no itching or pain.

Physical Generals

Diet	Non-veg
Appetite	Normal
Desire	Eggs
Aversion	Green veg, bland food.
Thermal Reaction	Chilly Patient.
Thirst	1.5-2 liters/day.
Stools	Satisfactory; 2 times a day.
Urine	Nothing specific.
Perspiration	Excessive especially on the head and face.
Sleep	Disturbed due to breathlessness.
Dreams	Sometimes remembers dreams.
Food intolerance	He likes milk but is aggravated after drinking it.

Examination

Fluid filled eruptions on palms

Investigation

Erythrocyte sedimentation rate (ESR-Westergren method) - 23 mm/hr; (after treatment reduced to 10 mm/hr).

Mental Generals

The patient's father is a manager and his mother is a housewife and he has an elder brother. He is more attached to his mother as his father is away most of the time. He studies in 6th standard and likes to study mainly prefers science. His school life is going well. He was excessively

reserved earlier now he has started being interactive. He is now the class representative and shows distinct leadership qualities. In school, he participates in various outdoor activities like Khokho, cricket, dancing, etc., and also likes playing computer games.

He is not very daring as a person and is always conscious about things. He thinks excessively before doing anything and is often indecisive. He is incredibly stubborn. He has a fear of darkness. He has a quiet and mild personality. He is unable to express his emotions easily. He is an introvert, and often takes time to interact with other people. He does not share anything readily. He is often scared and prefers to play alone. But he does not have stage fright. He is sensitive, gets sad prefers to be alone in his room when his mother gets angry and scolds him. Sometimes he gets angry if someone says anything bad. If anyone hits him or scolds him then he cries a lot. He even cries while watching emotional scenes. He was very concerned and conscious about the skin problems in his hands which were visible every day. He felt helpless and hopeless as the disease kept on aggravating every 15 days and was troublesome for him. His friends also made fun of him. It was a difficult time for him at school and during playtime spent with friends.

Past History

Viral fevers off and on, Typhoid in 2020

Family History

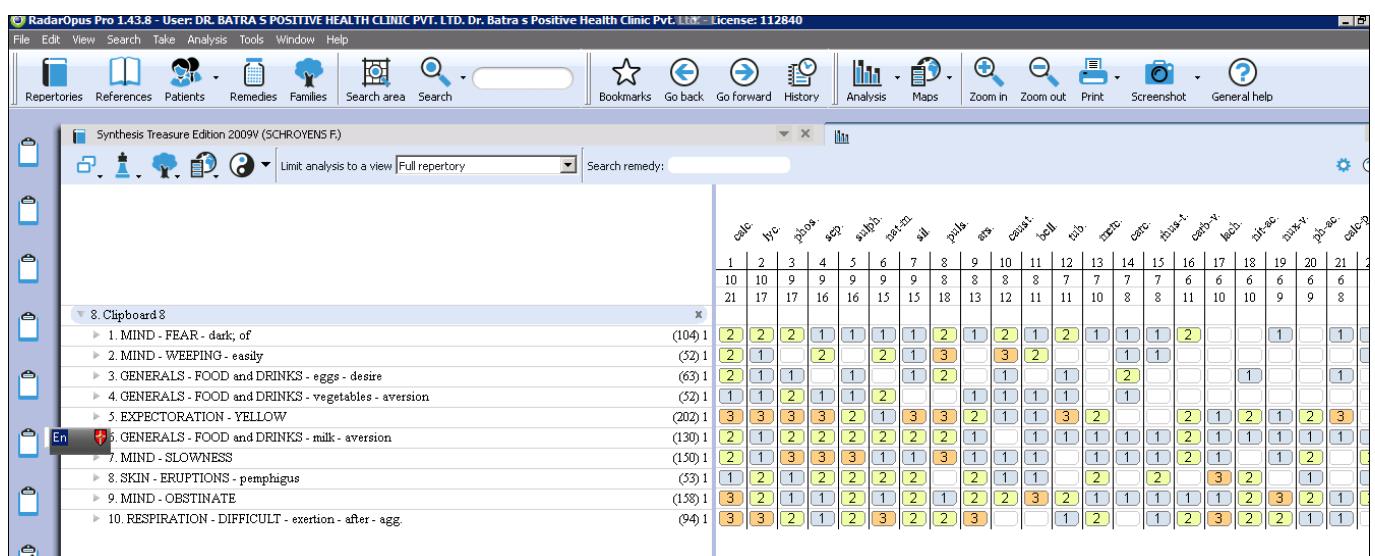
Mother-Bronchial asthma

Case analysis

Repertorial totality

Repertory used	Rubrics selected
Synthesis	[Mind] Fear, dark, of
	[Mind] Weeping, easily
	[Mind] Slowness
	[Mind] Obstinate
	[Generals] Food and Drinks, eggs, desire
	[Generals] Food and Drink, vegetables, aversion
	[Generals] Food and Drink, milk, aversion
	[Expectoration] Yellow
	[Skin] Eruption, pemphigoid
	[Respiration] Difficult, exertion, after, agg

Repertory screenshot



Selection of Remedy

Remedy	Reasons
Constitutional Calcarea carbonica 200 1dose/week	Calcarea carbonica is given based on the totality of the symptoms that cover the characteristics symptoms of his personality, and mind.
Acute Petroleum 30 1/ week	The specific medicine was given based on the acute symptoms similarity that he presented when he first visited the clinic.

Miasmatic approach

Symptoms	Psora	Sycosis	Syphilis	Tubercular
Indecisive	+			
Fear Dark	+			
Reserved	+			
Dullness, slowness	+			
Chilly, cold, sensitive	+			
Obstinate	+			
Miasmatic predominance	PSORA			

Materials and Methods: Synthesis repertory used**Results**

Months	Skin	Respiratory System	Prescription
1 st month	Bullous pemphigoid eruption-itching++ on hands. Dermatitis on fingers & toes-redness+	Breathlessness++ on exertion Cough with fever Yellowish expectoration+++	Petroleum 30, 1 dose/week Calcarea phosphorica 6x, 1 pill daily & Sac lac 30, twice a day.
2 nd month	Bullous pemphigoid eruption-itching reduced on hands. Dermatitis on fingers & toes-redness reduced	Breathlessness++ on exertion Cough reduced. Yellowish expectoration++	Calcarea carbonica 200, 1 dose/week Calcereaphosphorica 6x, 1 pill daily & Sac lac 30, twice a day
3 rd month	Bullous pemphigoid eruption-itching <night on bedtime, Right-side eruptions on hands started healing Dermatitis on fingers & toes- redness reduced	Breathlessness ++ on exertion took inhaler 2/wk Cough reduced.	Sulphur 6c, 2 dose/1 day (morning) Arsenic album 30, 2 dose/week & Sac lac 30, twice a day
4 th month	Bullous pemphigoid eruption-eruptions on hands get clear, Dermatitis on fingers & toes- itching absent	Breathlessnessabsent(no need to take the inhaler). Cough also reduced. Expectoration absent.	Arsenic album 30, once a day. Sac Lac 30, once a day.
5 th month	Bullous pemphigoid eruption- boils appear between small toe after wearing shoe, & small boil eruption on left thumb	Breathlessness also increased the need to take the inhaler	Arnica 30, twice a day for 1 week, Arsenic album 30, 2 doses per week, & Natrum Sulphurica 6x, twice a day
6 th month	Bullous pemphigoid eruption- boils on the inside of small toe reduced; Left thumb eruption also reduced Dermatitis- Itching also reduced, redness reduced	Breathlessness reduced; Cough reduced. Expectoration absent.	Arnica 30, 2 doses per week Arsenic album 30, 2 doses per week & Sac Lac 30, twice a day.
7 th month	Bullous Pemphigoid eruption- eruption on fingers & toes got resolved Dermatitis- itching & redness also got recovered.	Breathlessness- absent Cough- resolved Expectoration- absent	Arsenic album 30, once a day & Sac Lac 30, once a day
8 th month	Bullous pemphigoid- Eruptions on hands not visible Dermatitis- itching & redness of the skin absent	Breathlessness- recovered; Chest clear on examination; Expectoration absent;	Arsenic album 30, 2 doses per week & Calcarea sulphurica 6x, twice a day
9 th month	Bullous pemphigoid, and dermatitis-eruptions & itching in hand and toes reduced, not visible	Breathlessness- no need to take inhaler; no difficulty in respiration on exertion Expectoration absent; Chest clear on examination	Calcarea sulphurica 6x, twice a day & Sac Lac 30, twice a day
10 th month	Bullous pemphigoid- no new eruptions, no discharges, no bleeding Dermatitis- absent	No difficulty in breathing while exertion, No cough, No expectoration	Calcarea sulphurica 6x, twice a day & Sac Lac 30, twice a day
11 th month	No eruptions no itching, no discharges in the skin	No breathing difficulty; On examination chest is clear No expectoration	Calcarea sulphurica 6x, SOS, twice a day & Sac lac 30, twice a day

12 th month	Bullous pemphigoid- no new eruption Skin of hands & feet have become smooth Dermatitis- no itching & redness of the skin	Breathing difficulty absent Chest clear on auscultation	Calcarea sulphurica 6x, SOS, twice a day & Sac lac 30, twice a day
			SOS if required

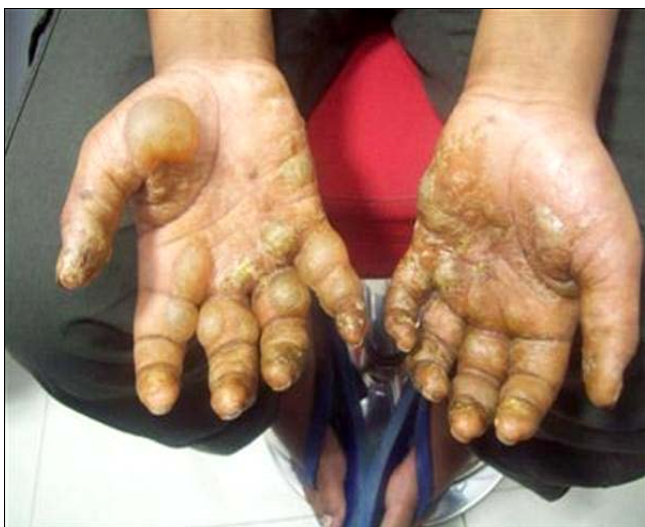Discussion and Conclusion

An 11-year-old male patient had come with his parents to Dr Batra's positive health clinic with a complaint of skin and respiratory manifestations but on careful and in-depth case-taking, it was noted that the disease though physical had a strong negative impact on the mind. The patient was very distressed due to the skin affections especially seen easily on his hands. He was helpless and troubled throughout the time he had exacerbations of the disease making him more and more conscious with every passing day and reducing his quality of life. After effective case-taking, a proper homeopathic repertorization was done to find appropriate medicines from a set of remedies like Calcarea carbonica, Silicea, Sulphur, Calcereasulphurica, etc. An Acute remedy petroleum, was also given for the skin manifestations showing marked symptom similarity for a brief time. It was then followed up by a constitutional medicine like Calcarea carbonica that acted very well to halt the progression of the disease.

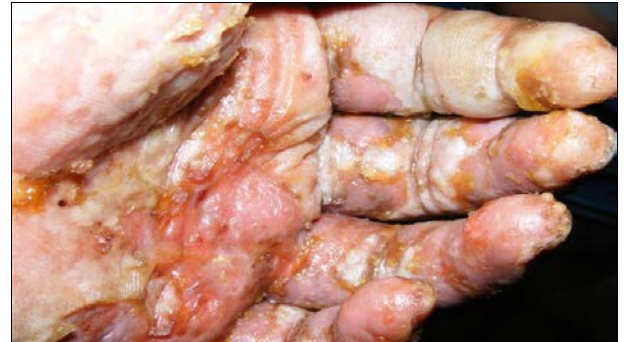The common misconception that homeopathy shows delayed effects does not hold ground as this case is an excellent representation of the same. When the remedy is carefully selected based on symptom similarity that is best suited to the patient then the expectations of a long-standing cure are possible. The use of biochemic system was also employed with marked health benefits received through various remedies like Calcereaphosphorica 6x, Calcereasulphurica 6x, Natrum Sulphurica 6x, etc. The patient received a successful treatment for a total period of 36 months with consistent follow-ups. There was measurable improvement as seen in follow-up descriptions as well as the transformation images. In the concluding follow-ups, the patient repeatedly expressed his gratitude stating that he had forgotten that he ever had such a troublesome disease and now he enjoys a fulfilling life with his friends and family.

The transformation

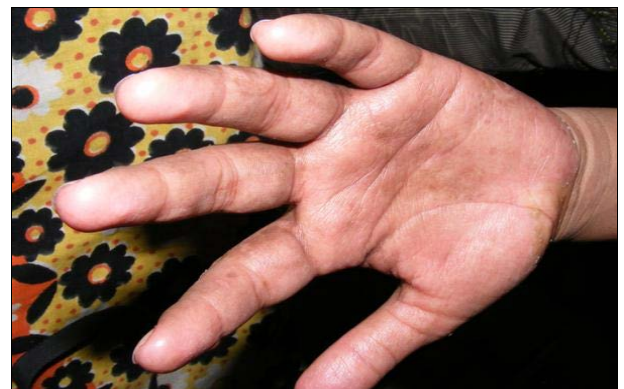1st day



2nd day



7th day



Acknowledgments

Opportunity to thank those who have helped and supported me personally and professionally during this process.

1. Dr. Bindu Sharma, Medical Director, Dr. Batra's positive health clinic.
2. Dr. Tanvi Lokhande, AM- Cured case management, Dr. Batras' Positive health clinic.
3. Dr. Deepanshi Tyagi, Homeopathic consultant (BHMS), Dr. Batras positive health clinic, Gurgaon clinic.
4. Dr. Neha Verma, Homeopathic consultant (BHMS), Dr. Batras, positive health clinic, Dwarka, Delhi.

Conflict of Interest

Not available

Financial Support

Not available

References

1. Aston R, Leppard B. Differential diagnosis in dermatology. 3rd ed. United Kingdom: Radcliffe publishing; c2005. p. 224.
2. Ralston SA, Penman ID, Starchan MWJ, *et al.* (editors). Davidson's principles & practice of medicine. 23rd ed. United Kingdom: Elsevier Health Sciences; c2018. p. 1255-1256.
3. Kridin K, Ludwig RJ. The growing incidence of bullous

- pemphigoid: overview and potential explanations. *Front Med (Lausanne)* [Internet]. 2018 [cited 2020 Aug 11];5:220. Published 2018 Aug 20. Available from: URL DOI:10.3389/fmed.2018.00220
4. Khanna N, Singh S. Bhutani's color atlas of dermatology. 6th ed. New Delhi: Jaypee Brothers Medical Publishers; c2015. p. 169.
 5. Kuzmina I. Case of Homeopathic treatment of bullous pemphigoid in an old man. *Allgemeine Homöopathische Zeitung* [Internet]. 2017 Mar [Cited 2020 Aug 12];262(02):2-76. Available from URL DOI:10.1055/s-0037-1601145
 6. Thakur. Bullous pemphigoid treated with homoeopathy: A case report. *World Journal of Pharmaceutical Research* [Internet]. 2017 May [cited 2020 Aug 12];1119-1126. Available from: URL DOI:10.20959/wjpr20175-8407 *International Journal of Ayush*. 2020;9(3):35-50.
 7. Van Haselen RA. Homeopathic clinical case reports: development of a supplement (HOMCASE) to the CARE clinical case reporting guideline. *Complement Ther Med* [Internet]. 2016 [Cited 2020 Aug 11];25:78-85. Available from: URL DOI:10.1016/j.ctim.2015.12.019
 8. Lamba CD, Gupta VK, Van Haselen R, *et al.* Evaluation of the modified naranjo criteria for assessing causal attribution of clinical outcome to homeopathic intervention as presented in case reports. *Homeopathy* [Internet]. 2020 Mar [Cited 2020 Aug 11];10.1055/s-0040-1701251. Available from: URL DOI:10.1055/s-0040-1701251
 9. Murrell DF, Daniel BS, Joly P, *et al.* Definitions and outcome measures for bullous pemphigoid: Recommendations by an international panel of experts. *J Am Acad Dermatol.* [Internet]. 2012 Mar [Cited 2020 Aug 11];66(3):479-485. Available from: URL DOI:10.1016/j.jaad.2011.06.03
 10. Kent JT. Lectures on homoeopathic philosophy. Student ed. New Delhi: B. Jain Publishers; c2002. p. 196-98, 203-8.
 11. Banerjee SK. Miasmatic prescribing its philosophy, diagnostic classification, clinical tips, miasmatic repertory, miasmatic weightage of medicines and case illustrations. 2nd ed. India: B.Jain Publishers (P) LTD; c2006. p. 51, 96-101, 122-128, 137, 141.
 12. Boericke W. Pocket manual of homoeopathic materia medica and repertory. Reprint ed. New Delhi: Indian Books & Periodicals Publishers; c2007. p. 459-62.
 13. Kent JT. Lectures on homoeopathic Materia Medica together with Kent's new remedies incorporated and arranged in one alphabetical order. Second Rearranged ed. New Delhi: B Jain Publishers (P) Ltd.; c2009. p. 767-68.
 14. World Health Organisation. The ICD-10 classification of clinical descriptions and diagnostic guidelines [Internet]. Geneva: World Health Organisation; c1992 [cited 2020 Aug 12]. Available from: <https://www.icd10data.com/ICD10CM/Codes/L00-L99/L10-L14/L12-/L12.0>
 15. Rath A. Prevalence and incidence of rare diseases: bibliographic data prevalence, incidence or number of published cases listed by diseases (in alphabetical order). Orphanet Report Series, Rare Diseases collection [Internet]. 2020 Jan [cited 2020 Aug 12];1:1-78. Available from: *International Journal of AYUSH*. 2020;9(3):35-50.
 16. Han A. A practical approach to treating autoimmune bullous disorders with systemic medications. *J Clin Aesthet Dermatol*. 2009 May;2(5):19-28.
 17. Pareek P. Homoeopathy in autoimmune disorders. *Allgemeine Homöopathische Zeitung* [Internet]. 2017 Mar [Cited 2020 Aug 11];262: 2-76. Available from URL DOI: 10.1055/s-0037-1601173
 18. Varma PN, Vaid I. Encyclopedia of homoeopathic pharmacopoeia & drug index. New Delhi: B. Jain Publishers; c2007. p. 669.
 19. Wang Y, Mao X, Wang Y, Zeng Y, Liu Y, Jin H, *et al.* Relapse of bullous pemphigoid: An update on this stubborn clinical problem. *Ann Med* [Internet]. 2018 May [cited 2020 Aug 12];50(3):234-239. Available from: URL DOI:10.1080/07853890.2018.1443346
 20. Hahnemann S. Organon of medicine. 5th ed. New Delhi: Indian Books & Periodicals Publishers; c2007. p. 103-4.
 21. Mandal PP, Mandal B. A textbook of homoeopathic pharmacy. Reprinted ed. Kolkatta: Miyamoto D., Santi C. G., Aoki V., *et al.* Bullous pemphigoid. *Am Bras Dermatol*. 2019;94:133-146. <https://www.ncbi.nlm.nih.gov/pmc/articles/PMC6486083/>.

How to Cite This Article

Kalra K. A case study of homoeopathic treatment for bullous pemphigoid. *International Journal of Homoeopathic Sciences*. 2023;7(4):187-191.

Creative Commons (CC) License

This is an open access journal, and articles are distributed under the terms of the Creative Commons Attribution-Non Commercial-Share Alike 4.0 International (CC BY-NC-SA 4.0) License, which allows others to remix, tweak, and build upon the work non-commercially, as long as appropriate credit is given and the new creations are licensed under the identical terms.